



Hypopharyngo Oesophago Gastric Lipoma and Pseudoachalasia

John KC Chan¹, Mamun Rashid^{1*}, Sri Kadiramanathan² and Albert Pace-Balzan³

¹Department of Otolaryngology, Bedford Hospital, UK

²Department of General Surgery, Broomfield Hospital, UK

³Department of Otolaryngology, Broomfield Hospital, UK

Abstract

Introduction: We report the first case of pseudoachalasia caused by a hypopharyngeal-oesophageal-gastric lipoma and its treatment.

Case Report: A 71 year old woman presented with symptoms of Pseudoachalasia including dysphagia, loss of weight, appetite and recent hematemesis. Computed Tomography (CT) and Oesophagogastroduodenoscopy (OGD) revealed a hypopharyngeal-oesophageal-gastric lesion. Endoscopic stapling of the lesion's pedicle with delivery of the lesion through a gastrotomy was performed. Histological assessment confirmed the lesion to be a lipoma. The patient made an uneventful recovery with no further recurrence at 6 months following surgery.

Discussion: Pseudoachalasia refers to the development of 'achalasia-like' syndrome secondary to underlying diseases. Here, we report the first case of hypopharyngeal-oesophageal-gastric lipoma which we successfully treated with surgical excision. This report also highlights the importance of differentiating between Pseudoachalasia and idiopathic achalasia as the treatment for these conditions are entirely different.

Keywords: Lipoma; Hypo pharyngeal neoplasms; Oesophageal neoplasm; Oesophageal achalasia; Manometry medical specialty; Head and neck

Introduction

Dysphagia, or difficulty swallowing, often represents a diagnostic challenge because of multiple possible causes (Table 1). A rare cause of dysphagia is Pseudoachalasia. Here, we present the first report of a hypopharyngeal-oesophageal-gastric lipoma causing pseudoachalasia. We also describe an innovative approach of lipoma excision by endoscopic stapling of its pedicle with delivery of the lipoma through a gastrotomy.

Relevant background literature was undertaken *via* Healthcare Databases Advanced Search (HDAS) of The National Institute for Health and Care Excellence (NICE) using the following keywords: Oesophageal lipoma, hypopharyngeal lipoma, pharyngeal lipoma, hypopharyngeal-oesophageal-gastric lipoma, achalasia and pseudoachalasia.

Case Presentation

A 71 year old woman was admitted under the upper gastroenterological team with a long history of progressive dysphagia, loss of appetite, weight loss and recent hematemesis. Past medical history included hypertension, diet-controlled diabetes mellitus and idiopathic achalasia diagnosed 3 months previously for which she had botulinum toxin injection with no relief. Achalasia was initially diagnosed with both Oesophagogastroduodenoscopy (OGD) and oesophageal manometry demonstrating a dilated oesophagus, aperistalsis, impaired oesophageal clearance and spasm at the lower oesophageal level but with poor tone of 8 mmHg (<25).

Hemoglobin level was initially low at 7.1 g/dL (13-17) which returned to normal at 11.8 g/dL after receiving 4 units of whole blood transfusion. Barium Swallow showed no abnormality. However, Computed Tomography (CT) of thorax and abdomen revealed a large fatty lipoma, 22 cm in length, filling and distending the oesophagus (Figure 1). A soft tissue tag was seen linking the lipoma to the anterior wall of hypopharynx (Figure 2). The body of the lipoma extended through the oesophageal hiatus into the stomach to contact the greater curve. Both the lungs and mediastinum

OPEN ACCESS

*Correspondence:

Mamun Rashid, Department of Otolaryngology, Bedford Hospital, UK, E-mail: mamunrashid@doctors.org.uk

Received Date: 10 Apr 2020

Accepted Date: 04 May 2020

Published Date: 06 May 2020

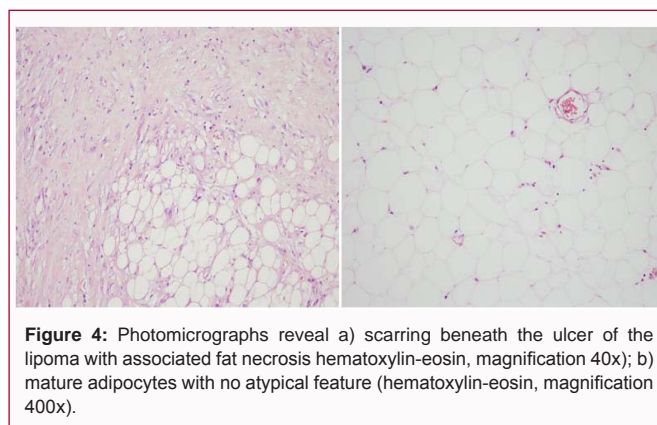
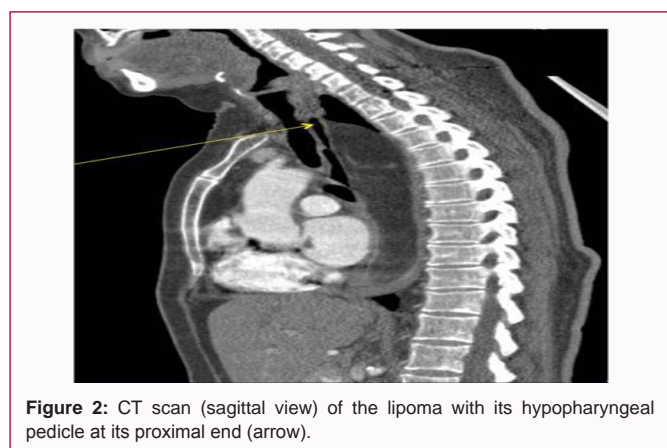
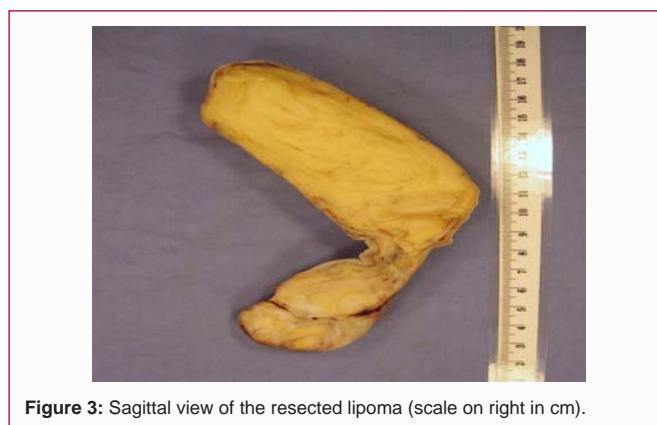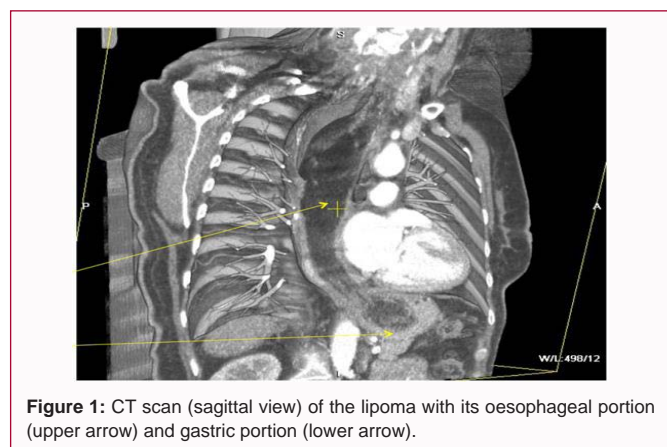
Citation:

Chan JKC, Rashid M, Kadiramanathan S, Pace-Balzan A. Hypopharyngo Oesophago Gastric Lipoma and Pseudoachalasia. *Am J Otolaryngol Head Neck Surg.* 2020; 3(3): 1092.

Copyright © 2020 Mamun Rashid. This is an open access article distributed under the Creative Commons Attribution License, which permits unrestricted use, distribution, and reproduction in any medium, provided the original work is properly cited.

Table 1: Causes of Pseudoachalasia [1,4].

Neoplastic	Malignant - adenocarcinoma of oesophago-gastric junction, squamous cell carcinoma of oesophagus, cardiac metastases of various primary tumors, bronchial carcinoma, lymphoma, hepatocarcinoma, pancreatic tumour, pleural mesothelioma, para-neoplastic. Benign - oesophageal leiomyoma or lipoma
Latrogenic	Post-fundoplication, gastric banding, gastrectomy
Familial	Adrenal insufficiency and Multiple Endocrine Neoplasia type 2B
Degenerative	Chronic idiopathic intestinal pseudo-obstruction
Infectious	Chagas' disease
Others	Pancreatic pseudocyst, mesenchymal tumors of oesophagus, mediastinal fibrosis, amyloidosis, sarcoidosis, and gastro-oesophageal reflux disease



appeared clear. A second OGD confirmed a pedunculated non-ulcerated lesion with polypoid area prolapsing into stomach with minor bleeding. Biopsy of the lesion taken revealed non-dysplastic stratified squamous epithelium.

A consensus for lipoma excision was taken following multidisciplinary discussion. The pedicle of the tumor was divided and stapled endoscopically by a senior otolaryngologist (last author). Access was gained using a Weerda bivalve distending diverticuloscope and the pedicle in post-cricoid area was divided using an Autosuture Multifire Endo-GIA 30 disposable surgical stapler. The tumor was subsequently delivered through a gastrotomy by a senior upper gastroenterological surgeon (second author). The gastrotomy, abdominal fascia and skin were closed with continuous 3-0 Polydioxanone (PDS) suture; loop 0 PDS and staples, respectively.

The macroscopic specimen was a pedunculated intra-oesophageal lipomatous mass measuring 165 mm × 40 mm × 45 mm (Figure 3). Microscopically it was composed of normal oesophageal-type squamous epithelium stretched over an unencapsulated but well-

circumscribed mass of mature adipose tissue. The margins were intact without evidence of dysplasia or malignancy (Figure 4). The patient made an uneventful recovery with no recurrence on follow up OGD at 6 months.

Discussion

Pseudo-achalasia refers to the development of ‘achalasia-like’ syndrome secondary to underlying diseases. Achalasia (“failure to relax”) is a primary motility disorder of the oesophagus marked by absent peristalsis of the oesophagus and inadequate relaxation of the Lower Oesophageal Sphincter (LOS) [1]. The prevalence of primary achalasia is 1:100,000 which is five times as common as the relatively rare condition of Pseudoachalasia [2]. Both conditions can result in symptoms of dysphagia, regurgitation, and chest pain. However, clinical features suggestive of pseudo-achalasia include symptoms of less than one year’s duration, substantial weight loss (>15-20 lbs) and peak incidence in the seventh and eighth decades. Approximately 2% to 4% of patients initially diagnosed with achalasia are later found to have pseudo- achalasia highlighted by our case [3,4]. The diagnosis of achalasia is made by barium swallow or oesophageal manometry.

Characteristic radiographic features on barium swallow include a dilated intrathoracic oesophagus, an air-fluid level and a LOS tapering to a point giving the distal oesophagus a 'beak-like' appearance [5]. Characteristic oesophageal manometric findings include impaired relaxation of the LOS during swallowing, absent peristalsis in the body of the oesophagus, increase in intra-oesophageal pressure relative to intra-gastric pressure and elevated LOS pressure greater than 45 mmHg [1,6]. Similar barium swallow and manometric results can be found in pseudo-achalasia [3,4]. Interestingly in our case, the barium swallow result was normal for which a possible explanation is that the lipoma was long enough to have traversed the oesophagus but stops short of passing into or too mobile to have prolapsed into the stomach at the time of imaging. Furthermore, the sensitivity of the barium examination varies greatly in the literature, from 25% to 87% [1]. Both achalasia and pseudo-achalasia can produce similar values in terms of LOS pressure which according to some studies may also be within normal limits as demonstrated by our case [2]. If initial investigations are equivocal and a clinical suspicion of pseudo-achalasia remains, further evaluation by OGD, CT or Magnetic Resonance Imaging (MRI) is warranted [1].

Gockel et al. [4] reviewed a total of 264 cases of pseudo-achalasia in 122 publications. Most cases were due to malignant disease (53.9% primary and 14.9% secondary malignancy), followed by benign lesions (12.6%) and sequelae of surgical procedures at the distal oesophagus or proximal stomach (11.9%).

Two rare causes of pseudo-achalasia are lipoma of the oesophagus and of the hypopharynx. Only 17 and 52 cases have been reported, respectively [7,8]. Our case is unique - a hypopharyngeal-oesophageal-gastric lipoma with its pedicle originating in the hypopharynx and its body extending through the entire oesophagus into the stomach. In their systematic review, Wang et al. [9] provided estimates of the prevalence of symptoms in oesophageal lipoma: Asymptomatic 85%, dysphagia 52.6%, epigastralgia 5.8% and aspiration with recurrent chest infections 5.3%. However no similar review was done for hypopharyngeal lipoma.

Investigations for lipoma irrespective of its origin in the upper digestive tract include barium swallow, manometry and OGD. As illustrated by our case, a CT or MRI scan can confirm and delineate the lipoma pre-operatively to enable surgical planning [8,10]. Endoscopic ultrasound is also useful to differentiate between submucosal, invasive extramural or diffuse oesophageal tumors [11]. Indeed it was previously instrumental in the differentiation of two cases of lipoma and liposarcoma confirmed by histology where both CT and MRI were homogeneously similar [12].

Histological evaluation with biopsy is not sensitive as submucosal material may not be easily obtained [2,9].

Management options of the lipoma including per-oral, endoscopic or lateral pharyngotomy excision is usually curative [13]. The exact approach is determined by tumor size and origin [9]. In our case, the body of the tumor was too large for endoscopic extraction through a diverticuloscope. It was deemed safest to deliver the lesion *via* a gastrotomy after endoscopic division and stapling of its hypopharyngeal pedicle.

Although lipoma in the pharynx or oesophagus is rare, its treatment is entirely different from that of idiopathic achalasia. Pneumatic dilation is often the initial therapy for idiopathic achalasia but would have been ineffective, potentially dangerous, and delayed

appropriate therapy in our case.

Manson et al. [14] reported 3 recurrences in their review of 24 cases of hypopharyngeal lipoma, one from previous non-radical extirpation and the other two from metachronous lipomas. In one other case, a hypopharyngeal lipoma tumor recurred 15 years after its initial resection [15]. These examples suggest that long-term follow up may be prudent but no consensus has yet been achieved. No case of malignant change has so far been reported [13].

Summary

Hypopharyngeal-oesophageal-gastric lipoma can be responsible for pseudo-achalasia. Importance of differentiating between pseudo-achalasia and idiopathic achalasia is emphasized as the treatment for these conditions are entirely different. Endoscopic stapling of the hypopharyngeal pedicle of the lipoma and its delivery through a gastrotomy by a combined effort of otolaryngologists and upper gastroenterological surgeons is described.

References

- Smith EM, Chaudhuri TK. What are the radiographic appearances of secondary achalasia, and how can it be differentiated from primary achalasia in barium studies? In: Giuli R, Galmiche JP, Jamieson GG, Scarpignato C, editors. The esophagogastric junction. Paris: John Libbey Eurotext; 1998.
- Orlando RC. Pseudo or secondary achalasia: Can manometric findings differentiate between? Are there specific criteria to distinguish achalasia from underlying malignancy? In: Giuli R, Galmiche JP, Jamieson GG, Scarpignato C, Editors. The esophagogastric junction. Paris: John Libbey Eurotext; 1998.
- Oelschlagel BK, Namkung J, Takayama H. Is this achalasia or pseudoachalasia? J Fam Pract. NJ: Quadrant Health Com Inc; 2007. [online].
- Gockel I, Eckardt VF, Schmitt T, Junginger T. Pseudoachalasia: a case series and analysis of the literature. Scand J Gastroenterol. 2005;40(4):378-85.
- Kahrilas PJ. What is pseudoachalasia, what are its causes? In: Giuli R, Galmiche JP, Jamieson GG, Scarpignato C, editors. The esophagogastric junction. Paris: John Libbey Eurotext; 1998.
- Holloway RH. Esophageal manometry. GI Motility. Nature Publishing Group; 2006.
- Mayo CW, Pagtalunan RJG, Brown DJ. Lipoma of the alimentary tract. Surg. 1963;53(5):P598-603.
- Eckel HE, Jungehülsing M. Lipoma of the hypopharynx: Pre-operative diagnosis and transoral resection. J Laryngol Otol. 1994;108(2):174-7.
- Wang CY, Hsu HS, Wu YC, Huang MH, Hsu WH. Intramural lipoma of the esophagus. J Chin Med Assoc. 2005;68(5):240-3.
- El-Monem MH, Gaafar AH, Magdy EA. Lipomas of the head and neck: Presentation variability and diagnostic work-up. J Laryngol Otol. 2006;120(1):47-55.
- Bryant RV, Holloway RH, Nguyen NQ. Education and imaging. Gastrointestinal: Role of endoscopic ultrasound in the evaluation of pseudoachalasia. J Gastroenterol Hepatol. 2012;27(6):1128.
- Muraki T, Akamathu T, Yokosawa S, Misawa N, Itou K, Inoue K, et al. Lipoma and liposarcoma of the hypopharynx of 2 cases report. Gastroenterol Endosc. 2005;47(10):2397-2404.
- Tan KK, Abraham KA, Yeoh KH. Lipoma of hypopharynx. Singapore Med J. 1994;35(2):219-21.

14. Mansson I, Wilske J, Kindblom LG. Lipoma of the hypopharynx. A case report and a review of the literature. *J Laryngol Otol.* 1978;92(11):1037-43.
15. Wenig BM. Lipomas of the larynx and hypopharynx: A review of the literature with the addition of three new cases. *J Laryngol Otol.* 1995;109(4):353-7.