



Hyperhomocysteinemia, *Helicobacter pylori* Infection and Recurrent In-Stent Thrombosis: a Case Report

Ian Shih^{1,3}, Feng-Chi Chang^{2,3} and Li-Chi Hsu^{3,4*}

¹Department of Neurology, Cheng-Ching Hospital Chung-Kang Branch, Taiwan

²Department of Radiology, Veterans General Hospital-Taipei, Taiwan

³Department of Neurology, National Yang-Ming University School of Medicine, Taiwan

⁴Department of Neurology, Neurological Institute, Veterans General Hospital-Taipei, Taiwan

Abstract

Hypercoagulability might be associated with in-stent thrombosis. Here we reported a case of hyperhomocysteinemia with recurrent in-stent thrombosis. A 35-year-old male was admitted to our hospital because of 4 episodes of transient right upper extremity weakness, numbness and dysarthria. Severe arterial stenosis was noted over the M1 segment of the left middle cerebral artery. Intracranial stenting was done immediately. Acute (1 day) and subacute (5 days) in-stent thrombosis was noted after the procedure. Search for hypercoagulable state revealed elevated homocysteine level and incidental *Helicobacter pylori* infection. The patient's condition was stabilized after proper management.

Keywords: Angioplasty and stenting; *Helicobacter pylori*; Hyperhomocysteinemia; Stroke

Introduction

Hyperhomocysteinemia (HHCy) had been emerged as an important risk factor for cardiovascular and cerebrovascular diseases [1]. Previous study also verified that HHCy was an independent risk factor of Middle Cerebral Artery (MCA) stenosis in Chinese people [2]. Besides, HHCy has proved to be an indicator of poor prognosis in patients receiving coronary artery stenting [3]. The advent of intracranial angioplasty and stenting as well as satisfactory outcome makes it a reasonable alternative therapy for people who experienced severe symptomatic intracranial stenosis and dissection [4]. To the best of our knowledge, HHCy has never been reported to be a risk factor of recurrent in-stent thrombosis in intracranial stenting previously.

Case Presentation

A 35-year-old male was admitted to our hospital because of four episodes of transient right upper extremity weakness, numbness, and dysarthria with total recovery within 5 min in one month. He was reportedly in good shape in the past. There was no remarkable past medical history except for a habit of smoking one and a half pack of cigarettes per day for 13 years. The first attack occurred in November 2008. Acute onset of right upper extremity weakness (muscle power from Medical Research Council (MRC) grade 5 to 0 in one minute) and numbness was noted when he was in an internet café playing online game. The condition got totally resolved within 5 min. Initially, he didn't pay much attention to it until the recurrence of similar events for another 3 times in the ensuing one-month. He was brought to our emergency department where carotid duplex examination showed severe stenotic flow over the M1 segment of left MCA. Carotid angiogram revealed 75% stenosis over the M1 segment of left Middle Cerebral Artery (MCA) (Figure 1A) Stenting and angioplasty was done by super selection of left M2 segment with a 0.014 inch extra-support microwire. After pre-dilatation with a 2 mm × 9 mm Maverick balloon (Boston Scientific Co, Natick, MA, USA), a 2.5 mm × 10 mm Tsunami stent (Terumo Co, Tokyo, Japan) was deployed in M1 segment of left MCA (Figure 1B). Good patency was noted in control angiogram after angioplasty and stenting. Eighteen hours after stenting, sudden onset of right extremities weakness (muscle power from MRC grade 5 to 4) and right central facial weakness with dysarthria occurred. Under the impression of acute stroke with proof of follow-up brain Magnetic Resonance Imaging (MRI) showing acute in-stent thrombosis with total occlusion over the M1 segment of left MCA (Figure 1C). Immediate Intra-Arterial (IA) thrombolysis was done with 240000U of urokinase and 15 ml tirofiban with complete resolution of the thrombus and revascularization of the left MCA

OPEN ACCESS

*Correspondence:

Li-Chi Hsu, Department of Neurology,
Neurological Institute, Section of
Cerebrovascular Diseases, Veterans
General Hospital-Taipei, Taipei 112,
Taiwan, Tel: +886-2-28757578; Fax:
886-2-28732131;

E-mail: lchsu@vghtpe.gov.tw

Received Date: 29 May 2019

Accepted Date: 03 Jul 2019

Published Date: 08 Jul 2019

Citation:

Shih I, Chang F-C, Hsu L-C.
Hyperhomocysteinemia, *Helicobacter
pylori* Infection and Recurrent In-Stent
Thrombosis: a Case Report. *Neurol
Case Rep.* 2019; 2(2): 1011.

Copyright © 2019 Li-Chi Hsu. This is
an open access article distributed under
the Creative Commons Attribution
License, which permits unrestricted
use, distribution, and reproduction in
any medium, provided the original work
is properly cited.

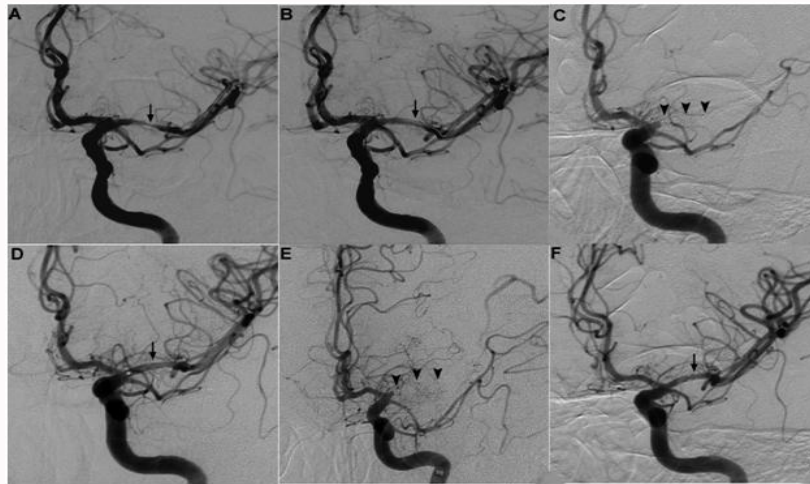


Figure 1: left carotid angiogram, **A:** Severe stenosis over M1 segment of left middle cerebral artery (arrow); **B:** Control angiogram after stent placement showed good patency (arrow); **C:** Acute in-stent thrombosis with total occlusion of left middle cerebral artery after 1 day (arrowheads); **D:** IA thrombolysis restored the patency of left MCA (arrow); **E:** 2nd in-stent thrombosis with total occlusion of left MCA on 6th post-procedural day (arrowheads); **F:** The thrombosed stent of left MCA was recanalized by IA thrombolysis but had residual in-stent thrombus and irregular lumen (arrow).

(Figure 1D). The symptoms and signs improved immediately after the IA thrombolysis. Unfortunately, acute onset of right extremities weakness occurred again 5 days after the previous IA thrombolysis (muscle power from MRC grade 4 to 1). Repeated brain MRI showed total in-stent occlusion again at M1 portion of left MCA with larger area of acute infarction. The carotid angiogram showed the thrombosed M1 segment of left MCA (Figure 1E). Emergent IA thrombolysis was done again with 360000 units of urokinase and angioplasty with 2.5 mm × 9 mm Maverick balloon. The thrombosed M1 segment of left MCA was recanalized. After completion of IA thrombolysis, we waited for another 40 min and found that the stent was thrombosed again. Hence, we gave IA thrombolytic agent again with 30 ml of tirofiban. The thrombosed segment of left MCA was totally restored to good patency again. Muscle power returned to the baseline level. We started to give intravenous heparin combined with oral anticoagulant (warfarin) after the procedure (Figure 1F). No recurrent symptoms and signs were noted afterwards. The survey of hypercoagulability state including tests for protein C, protein S, lupus anticoagulant, antithrombin, prothrombin/activated partial thromboplastin time, amphetamine and cocaine screen, cardiolipin IgG, anti-phospholipid antibody IgG, anti-beta2-glycoprotein IgG, Anti-Neutrophilic Cytoplasmic Antibodies (ANCA), Antinuclear Antibody (ANA), IgG, IgA, IgM, double-strand DNA, Extractable Nuclear Antigens (ENA) test, cryoglobulin, Venereal Disease Research Laboratory (VDRL) test, Human Immunodeficiency Virus (HIV), and folate level were all within normal range. The Erythrocyte Sediment Rate (ESR) was 55 mm/h (normal range: 10~20 mm/h). The High Sensitivity C-Reactive Protein (HsCRP) was 1.5 mg/dL (normal range 0~0.5 mg/dL). The homocysteine level was 26.82 μmol/L (normal range: 5~13.9 μmol/L). The vitamin B12 level was 139 μg/mL (normal range: 160~970 μg/mL). Upper gastrointestinal endoscopy showed gastric ulcer, duodenal ulcer, and the presence of *Helicobacter pylori* (*H. pylori*) infection. Standard triple therapy was given with amoxicillin 1 g twice daily, clarithromycin 500 mg twice daily, and esomeprazole 40 mg once daily for 10 days. Immediate intramuscular Vitamin B12 injection was given to the patient as well. The patient was discharged in stable condition and remained unremarkable 3 months later.

Discussion

The unusual co-existence of hyper acute, acute and subacute recurrent in-stent thrombosis of the intracranial stent in this patient demonstrated the high tendency of thrombosis in susceptible patients, such as patients with *H. pylori* infection-related vitamin B12 deficiency and secondary HHCy.

Helicobacter pylori infection and atherosclerosis

H. pylori infection has been identified in human atherosclerotic plaques [5]. Case control studies found that the association between *H. pylori* infection and stroke depends on strain of *H. pylori*. *H. pylori* strain with cytotoxin-associated gene-A (Cag-A) seropositivity was strongly associated with ischemic stroke in contrast to general strain of *H. pylori* [6]. Besides, Cag-A positive *H. pylori* have been further shown to be independently associated with carotid plaque irregularities [7]. Though the strain of the *H. pylori* was not available in our patient, the Cag-A was detected in 99% of 101 clinical isolates of *Helicobacter pylori* collected in one study in Taiwan [8]. However, risk of cardio embolic stroke is not increased with *H. pylori* infection [9].

Helicobacter pylori infection, vitamin B12 deficiency and HHCy

H. pylori infection has been considered a correctable cause of HHCy10 and vitamin B12 deficiency solely by eradication of *H. pylori* [11]. In addition, it is well established that HHCy may be secondary to vitamin B12 deficiency. However, no reports have been published to support the concept that eradication therapy alone might lower stroke risk significantly in this subgroup of patient (HHCy and *H. pylori* infection).

HHCy, Inflammation and atherothrombosis

Many mechanisms have been proposed to explain how increased total homocysteine level could contribute to vascular disease [12]. The strongest evidence for this link comes from studies of animal models and indicates that the principal mechanisms involve impaired endothelial function, increased oxidative stress, alterations of lipid metabolism, and induction of thrombosis. In fact, increased coagulability of the blood had been noted to be associated with

raised plasma total homocysteine concentrations [4,13-15]. HHCy also activates platelet aggregation and promote thrombus formation [16]. HHCy alters endothelial cell function by upregulating MCP-1 and IL-8 expression and secretion. By enhancing the responsiveness of monocyte to inflammatory stimuli and promoting leukocyte recruitment in atherosclerotic plaque, HHCy may contribute to atherogenesis [16]. The Cag-A positive *H. pylori* infection and secondary HHCy may contribute to chronic inflammatory status in our patient as manifested by elevated ESR and HsCRP. This chronic inflammation may subsequently lead to atherosclerosis and repeated thrombosis [15,16].

HHCy and stenting

HHCy might explain the high tendency of repeated thrombosis in our patient after intracranial stenting. In fact, acute thrombosis had been reported to be associated with HHCy in patients receiving coronary artery stenting [17]. Though no data support the same risk of acute thrombosis after intracranial angioplasty and stenting in patients with HHCy, we recommend routine screen of homocysteine level before scheduled intracranial stenting based on the finding of our patient.

Future perspective

In management of a young patient with crescendo transient ischemic attacks and intracranial stenosis like our patient, it is a dilemma of decision making between emergent intracranial stenting and screening for risk factors of young stroke. What's the minimal routine risk factor screening necessary before an emergent intracranial stenting and angioplasty? Because these surveys take days or even weeks to get results, it may be too late for decision making of an urgent endovascular therapy. In this subgroup of patients with HHCy secondary to *H. pylori* infection, eradication of *H. pylori* alone might be able to prevent intracranial stenosis and thromboembolic event. Though unrelated to our patient, the eradication of *H. pylori* may be beneficial in some patients with dementia and vitamin B12 deficiency through restoration of vitamin B12 level. Further study was necessary to test the hypothesis. It also needs more evidence to confirm the efficacy of immediate vitamin B12 supplementation in such patients.

Conclusion

In summary, our case was an extraordinary example of how *H. pylori* infection, low vitamin B12 level and high homocysteine concentration might contribute to atherosclerosis manifested with MCA stenosis and recurrent in-stent thrombosis in an otherwise healthy young male.

References

1. Van Guldener C, Stehouwer CD. Homocysteine and large arteries. *Adv Cardiol.* 2007;44:278-301.
2. Huang HW, Guo MH, Lin RJ, Chen YL, Luo Q, Zhang Y, et al. Hyperhomocysteinemia is a risk factor of middle cerebral artery stenosis. *J Neurol.* 2007;254(3):364-7.
3. Lange H, Suryapranata H, De Luca G, Börner C, Dille J, Kallmayer K, et al. Folate therapy and in-stent restenosis after coronary stenting. *N Engl J Med.* 2004;350(26):2673-81.
4. Nishinaga M, Ozawa T, Shimada K. Homocysteine, a thrombogenic agent, suppresses anticoagulant heparan sulfate expression in cultured porcine aortic endothelial cells. *J Clin Invest.* 1993;92(3):1381-6.
5. Ameriso SF, Fridman EA, Leiguarda RC, Sevlever GE. Detection of *Helicobacter pylori* in human carotid atherosclerotic plaques. *Stroke.* 2001;32(2):385-91.
6. Preusch MR, Grau AJ, Bugge F, Lichy C, Bartel J, Black C, et al. Association between cerebral ischemia and cytotoxin-associated gene-A-bearing strains of *Helicobacter pylori*. *Stroke.* 2004;35(8):1800-4.
7. Gabrielli M, Santoliquido A, Cremonini F, Cicconi V, Candelli M, Serricchio M, et al. CagA-positive cytotoxic *H. pylori* strains as a link between plaque instability and atherosclerotic stroke. *Eur Heart J.* 2004;25(1):64-8.
8. Lai CH, Kuo CH, Chen YC, Chao FY, Poon SK, Chang CS, et al. High prevalence of cagA- and babA2-positive *Helicobacter pylori* clinical isolates in Taiwan. *J Clin Microbiol.* 2002;40(10):3860-2.
9. Markus HS, Mendall MA. *Helicobacter pylori* infection: a risk factor for ischaemic cerebrovascular disease and carotid atheroma. *J Neurol Neurosurg Psychiatry.* 1998;64(1):104-7.
10. Marino MC, de Oliveira CA, Rocha AM, Rocha GA, Clementino NC, Antunes LF, et al. Long-term effect of *Helicobacter pylori* eradication on plasma homocysteine in elderly patients with cobalamin deficiency. *Gut.* 2007;56(4):469-74.
11. Kaptan K, Beyan C, Ural AU, Cetin T, Avcu F, Gülşen M, et al. *Helicobacter pylori* -- is it a novel causative agent in Vitamin B12 deficiency? *Arch Intern Med.* 2000;160(9):1349-53.
12. Spence JD. Homocysteine-lowering therapy: a role in stroke prevention? *Lancet Neurol.* 2007;6(9):830-8.
13. Undas A, Brozek J, Szczeklik A. Homocysteine and thrombosis: from basic science to clinical evidence. *Thromb Haemost.* 2005;94(5):907-15.
14. Lentz SR. Mechanisms of thrombosis in hyperhomocysteinemia. *Curr Opin Hematol.* 1998;5(5):343-9.
15. Ebbesen LS. Hyperhomocysteinemia, thrombosis and vascular biology. *Cell Mol Biol (Noisy-le-grand).* 2004;50(8):917-30.
16. Huang T, Yuan G, Zhang Z, Zou Z, Li D. Cardiovascular pathogenesis in hyperhomocysteinemia. *Asia Pac J Clin Nutr.* 2008;17(1):8-16.
17. D'Amario D, Niccoli G, Porto I, Crea F. Dynamic thrombosis associated with bare-metal stent malapposition in a patient with hyperhomocysteinemia. *J Cardiovasc Med (Hagerstown).* 2008;9(4):427-9.