



# Hydatid Cyst of the Liver Ruptured into the Thorax in a Child

Mohamed Zouari<sup>1,2\*</sup>, Ahmed Khalil Ben Abdallah<sup>1,2</sup>, Imen Abid<sup>1,2</sup>, Mahdi Ben Dhaou<sup>1,2</sup>, Mahdi Ben Dhaou<sup>1,2</sup> and Riadh Mhiri<sup>1,2</sup>

<sup>1</sup>Department of Pediatric Surgery, Hedi-Chaker Hospital, Tunisia

<sup>2</sup>Department of Pediatric Surgery, Sfax Medical School, Tunisia

## Clinical Image

A 6-year-old boy who fell to the ground from a two meters high wall presented to the emergency department for complaints of dyspnea, cough, and abdominal pain of around 10 hours duration. On examination, his temperature was 38.2°C. The respiratory rate was 44 breaths/min and the heart rate 102 beats/ min. Abdominal examination revealed tenderness and ecchymosis on the right abdomen. In the Computed Tomography (CT) evaluation, the liver had multiple low-density lesions in segments V, VI, VII, and VIII (4.5 cm, 4 cm, 3 cm, and 5 cm diameter, respectively). The hydatid cyst of the hepatic dome was complicated by pulmonary cracking with evidence of a fistulous pathway (Figure 1). There was also a right-sided pleural effusion. The patient underwent emergency surgery. A chest tube was inserted in the fifth right inter costal space. The ruptured hepatic cyst was treated by cystectomy, excision of the germinative membrane, and closure of the fistulous tract with non-

## OPEN ACCESS

### \*Correspondence:

Mohamed Zouari, Department of Pediatric Surgery, Hedi-Chaker Hospital, 3029 Sfax, Tunisia, Tel: +21697459586;

E-mail: zouarimohamed.1982@yahoo.fr

Received Date: 13 May 2019

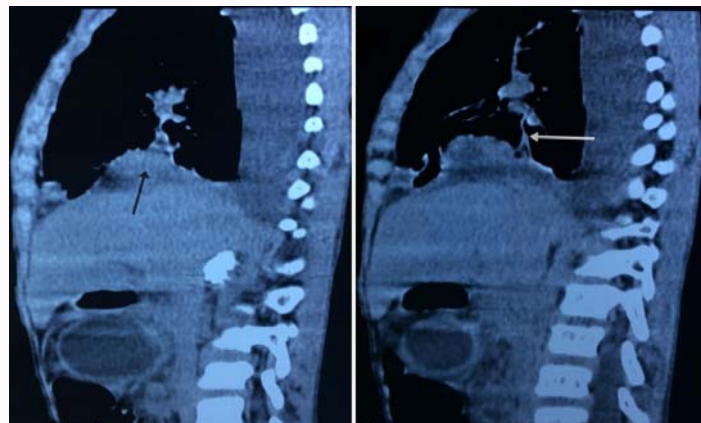
Accepted Date: 12 Jun 2019

Published Date: 14 Jun 2019

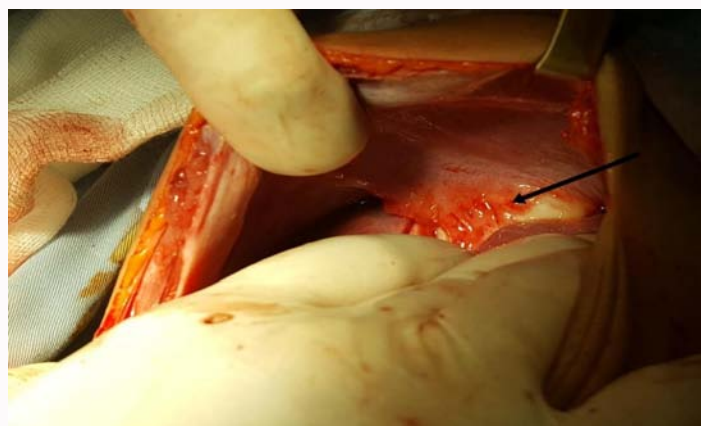
### Citation:

Zouari M, Ben Abdallah AK, Abid I, Ben Dhaou M, Ben Dhaou M, Mhiri R. Hydatid Cyst of the Liver Ruptured into the Thorax in a Child. Ann Pediatr Res. 2019; 3(2): 1022.

**Copyright** © 2019 Mohamed Zouari. This is an open access article distributed under the Creative Commons Attribution License, which permits unrestricted use, distribution, and reproduction in any medium, provided the original work is properly cited.



**Figure 1:** The hydatid cyst of the hepatic dome was complicated by pulmonary cracking with evidence of a fistulous pathway.



**Figure 2:** The ruptured hepatic cyst.

absorbable suture (Figure 2). Then the excision of the other hydatid cysts was performed. After operation, oral albendazole treatment (10 mg/kg) for 6 months was suggested as medical adjuvant treatment. Histological examination of the specimen revealed scolices, daughter

cysts, and fragments of the lamellar membrane. No bacterial pathogen was cultivated in the cyst fluid. A 3-month follow up visit revealed a healthy and asymptomatic boy.