



Gangrene of Penile Skin - A Rare Entity

Sonal Kumar Jha and Alisha Qamar*

Northern Railway Central Hospital, Delhi, India

Clinical Image

Penile gangrene is seen infrequently but is associated with significant morbidity and mortality.

Gangrene of penis may be dry or infective. It is rare, fulminant but usually a localized disease of penis and scrotum with occasional extension up to abdominal wall.

A 27-year-old gentleman presented with pain, fever and brownish black discoloration of penis since 7 to 8 days; with history of Savalon application over the penile area for hygiene purpose. There was no h/o trauma, infection or diabetes.

General examination: Febrile; no pallor.

Local examination: Brownish black discoloration of penile skin extending up to penoscrotal junction without any clear line of demarcation.

Penile gangrene is rare, but grave sequelae following infection or ischemia. Vascular compromise may be caused by tourniquet syndrome; Priapism; venous thrombosis and anticoagulants and can also be seen in diabetics with end stage renal disease.

USG Doppler can provide information regarding thrombosis or rupture of cavernosal and dorsal penile vessels (Figure 1).

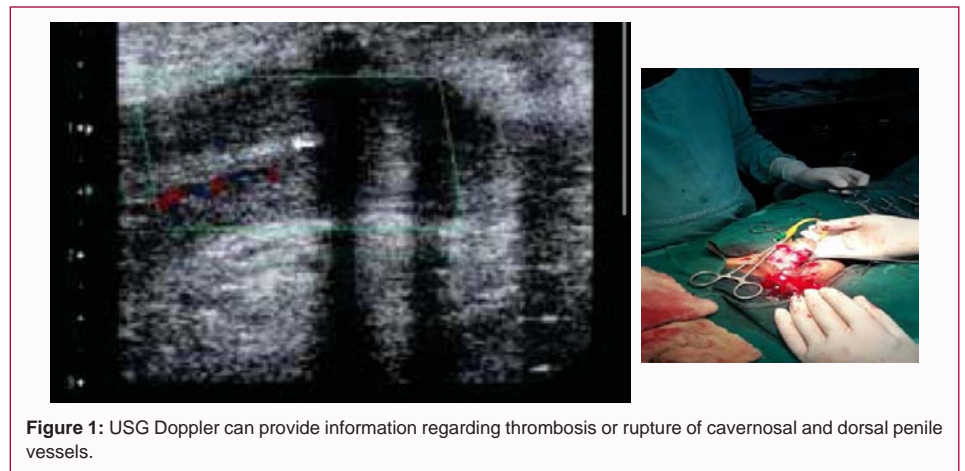


Figure 1: USG Doppler can provide information regarding thrombosis or rupture of cavernosal and dorsal penile vessels.

OPEN ACCESS

***Correspondence:**

Alisha Qamar, Northern Railway Central Hospital, Delhi, India, Tel: 9810446589;

E-mail: sonaljha.jha@gmail.com

Received Date: 05 May 2022

Accepted Date: 30 May 2022

Published Date: 02 Jun 2022

Citation:

Jha SK, Qamar A. Gangrene of Penile Skin - A Rare Entity. *Ann Clin Surg.* 2022; 3(1): 1024.

Copyright © 2022 Alisha Qamar. This is an open access article distributed under the Creative Commons Attribution License, which permits unrestricted use, distribution, and reproduction in any medium, provided the original work is properly cited.