



Focal Dermal Hypoplasia: A Male Case

Kan Wu^{1*}, Bin Hu², Yingxue Huang³, Wei Zhang⁴ and Jianfang Sun⁴

¹Department of Dermatology, General Clinic, China

²Department of Dermatology, Wuhan No.1 Hospital, China

³Department of Dermatology, Xiangya Hospital, China

⁴Department of Pathology, Chinese Academy of Medical Sciences and Peking Union Medical College, China

Abstract

A 17-year-old male presented with multiple linear distributed erythema and papules which first appeared since birth. The erythema was fragile, easily traumatized, and often healed with hypopigmented atrophic scars. The right first and second fingers and nails were hypoplastic. Generalized linear or whorled hyperpigmented patches gradually developed and multiple papillomatous papules emerged during childhood, which were mainly distributed in the perioral region. A skin biopsy found epidermal parakeratosis, diminished dermal thickness, increased vasculatures in dermal papillae, and upward migration of subcutaneous fat layer known as “fat herniation”. A diagnosis of focal dermal hypoplasia was thus established.

Keywords: Focal dermal hypoplasia; Goltz-gorlin syndrome; Blaschko’s line; Linear and whorled nevoid hypermelanosis

Introduction

Focal dermal hypoplasia (FDH; omim 305600) is a rare x-linked dominant ectomesodermal dysplasia syndrome first described by Goltz et al. [1], later summarized and reviewed by Gorlin et al. [2], is now also known as Goltz-Gorlin syndrome. It is a disease with multi-system symptoms and characterized by patchy dermal hypoplasia along the lines of blaschko, the lesional dermis is significantly thinned and replaced by subcutaneous fat tissue, known as “Fat Herniation”. Other abnormalities include papillomas around the mucocutaneous junction, dystrophic nails, sparse brittle hair and various developmental anomalies of bones, teeth, eyes and head. Management is therefore multidisciplinary. However, patients are frequently misdiagnosed for a long period resulting in avoidable life-long defects. 200 to 300 FDH cases have been previously reported in the literatures with no ethnic or racial predilection [3]. But as a X-linked dominant male-lethal disorder, male patients are extremely rare, we hereby report a case of male FDH patient with mild clinical disease but typical pathological findings.

Case Presentation

A 17-year-old chinese male presented with multiple striated erythema and papules which first appeared since birth, he was born full-term after an uneventful pregnancy with a low birth weight of 2.40 kg (normal range defined as 2.50-4.00 kg in mainland china). His mother was a farmer who reported no infection or medications taken during pregnancy and there was no history of previous miscarriages. His parents were non-consanguineous and he is the first and only child in the family.

The erythematous patches were fragile at birth, easily traumatized, then gradually healed with hypopigmented atrophic scars. The right first and second fingers and nails were hypoplastic. The infant was otherwise healthy and intellectual development progressed normally with age. At the age of five, some papules appeared in the perioral region. Repeated laser ablations were performed but the lesions continued to erupt.

On examination, there were linear and whorled hypo/hyperpigmented macules and yellowish/pink plaques which generally followed the blaschko’s line (Figure 1). Multiple papillomas were noted mostly in the perioral region and chin, with the largest one located in the right popliteal fossa (Figure 2). The right index finger was radial deviated with the first and second fingernails appeared to be hypoplastic, there was also yellowish/pink plaque in the right thumb (Figure 3). No obvious enamel defects were noticed. X-ray photography of the limbs did not find osteopathia striata. Biopsy of an atrophic scar like lesion revealed decreased thickness of the dermis and extensive replacement

OPEN ACCESS

*Correspondence:

Kan Wu, Zhuhai Xiguang, Department of Dermatology, General Clinic, 172 Renminxi St, Zhuhai, 519000, China,

Tel: (86) 18666100527;

E-mail: Drhonng@Foxmail.Com

Received Date: 02 Aug 2016

Accepted Date: 01 Sep 2016

Published Date: 22 Sep 2016

Citation:

Wu K, Hu B, Huang Y, Zhang W, Sun J. Focal Dermal Hypoplasia: A Male Case. *J Dermatol Plast Surg*. 2016; 1(1): 1002.

Copyright © 2016 Kan Wu. This is an open access article distributed under the Creative Commons Attribution License, which permits unrestricted use, distribution, and reproduction in any medium, provided the original work is properly cited.

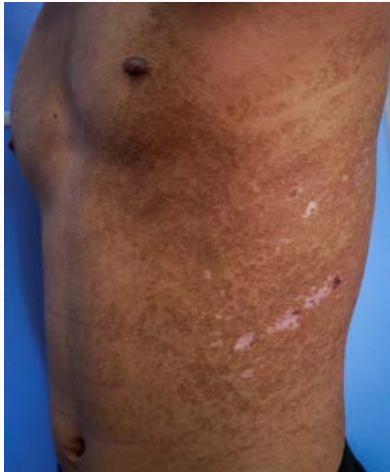

Figure 1:

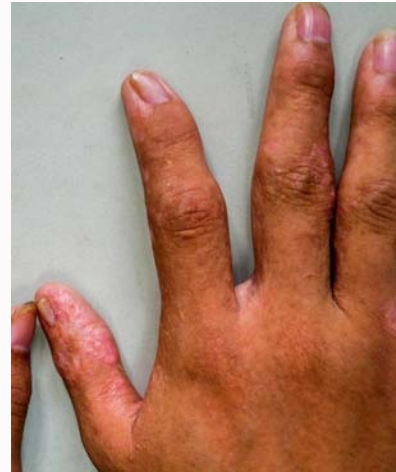

Figure 3:

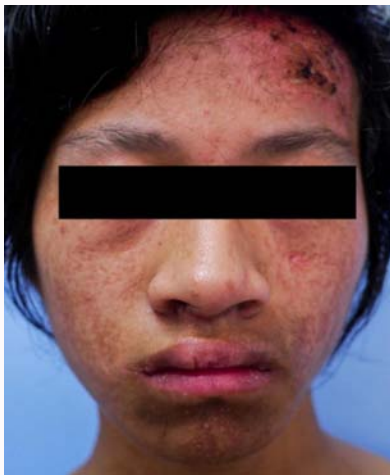

Figure 2:

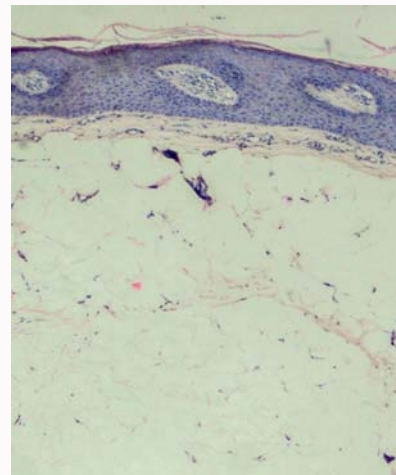


Figure 4:

by fat tissue (Figure 4), which was consistent with FDH.

Discussion

FDH is a rare syndrome with distinct clinical and pathological features. Similar histopathological changes can only be found in naevus lipomatosus cutaneous superficialis. Diagnosis is made by clinicopathological correlation. For mild cases at birth, aplasia cutis congenita should be considered in differential diagnosis because scraping or biopsy may be contraindicated. In contrast to the diversity manifestations of FDH, aplasia cutis congenita is often an isolated finding in which the head region is mostly affected and lesions tend to be monomorphous. The epidermis, dermis, and fat may all be missing; a single absence of the dermis theoretically exists but is different from "Hypoplasia". Linear and whorled nevoid hypermelanosis is another monomorphous disease, although some patients may present with systemic involvement. Denuded hypopigmented lesions, fat herniation and papillomas are absent. In comparison to the evolving lesions of incontinentia pigmenti with stages change, the linear and whorled macules of FDH are relatively static. For severe cases with prominent limb deformity, a series of syndromes should be considered in differential diagnosis. The lobster-claw deformity is seen in several autosomal dominant syndromes, but not a pathognomonic finding of FDH, whereas fat herniation is never

a feature of them [4]. Symmetrical second digital nail hypoplasia is known as iso-kikuchi syndrome [5], our case was unilateral affected with concomitant first fingernail hypoplasia and perinail skin change, which was a sign of FDH skin adnexal involvement.

Wingless/wnt signaling has been implicated in the embryo development of nearly all animal tissues as well as human diseases. Drosophila wingless/wnt secretion and activity require the dedicated function of an endoplasmic reticulum-localized acyltransferase enzyme, porcupine. Porcn is the single mammalian ortholog of porcupine, and inhibiting it by RNAi or small molecule antagonists impairs the processing, secretion, and activity of multiple vertebrate wnts. Mouse models with deleted porcn exhibit a spectrum of limb, skin, and body patterning abnormalities resembling those observed in human patients with FDH, and considerably overlap with defects observed in mouse wnt pathway mutants, suggesting malfunction porcn cause FDH through defective wnt signaling [6,7].

The only gene recognized to cause FDH is porcn, located at Xp 11.23 and the inheritance is thought to be X-linked dominant with early intrauterine mortality in males as supported by reports of affected families, in which there were female-to-female transmission, increased rate of pregnancy wastage and decreased male-to-female ratio [8,9]. However, the fertility of female patients is markedly reduced

[10]. It was estimated that more than 95% of all cases and 100% of all male patients appear de novo as evidenced by the fact that reported male cases have always been the first affected member of their families [9,11]. Rarely, there were three reported father-daughter transmission, in two of them, the fathers exhibited only mild forms of the disease. In these cases, expression of the mutant gene might be minimal, the fathers themselves might have somatic X mosaicism, with only a little proportion of their cells carrying the X gene mutation [10]. The affected females are either heterozygous or have somatic mosaicism for a porcn mutation, whereas all affected males have somatic mosaicism for porcn mutations [9,11]. Our patient is a sporadic and most probably somatic mosaic case who manifests relatively mild mucocutaneous lesions, dystrophic nails, limb malformations. The anomalies were bilateral but more prominent on one side. The histopathological findings were consistent with FDH. We did not perform amplification and sequence analysis of porcn gene from the peripheral white blood cells because when a porcn mutation occurs post-zygotically in early embryos, the cells with mutated porcn allele may not be present in the blood cells in all cases and we believed that taking fresh tissue from the lesional skin for further confirmation was not necessary [12].

There is no cure for FDH but appropriate aesthetics, especially dental treatment, is advocated. Some authors have suggested that children should attend their first dental visit as early as possible to prevent the occurrence of dental caries because enamel hypoplasia may make plaque control difficult and skeletal hand anomalies may limit the dexterity needed to conduct proper oral hygiene. During dental procedures, antibiotic prophylaxis against infectious endocarditis should be implemented depending on the type of cardiac septal or valvular defects presented. Uncontrolled observation found that weekly topical application of fluoride varnish might prevent oral papillomas as well as dental caries [3].

In conclusion, although FDH is not curable, in the severe cases, with early diagnosis, proper treatment and consultation, patients' quality of life may be greatly improved. Our case was a mild case with minimal morbidity, it's important to recognize and differentiate it from other non-hereditary diseases, and more importantly, provide proper genetic counseling to avoid more severely affected female offspring.

References

1. Goltz RW, Peterson WC, Gorlin RJ, Ravits HG. Focal dermal hypoplasia. *Arch Dermatol.* 1962; 86: 708-717.
2. Gorlin RJ, Meskin LH, Peterson WCJ, Goltz RW. Focal dermal hypoplasia syndrome. *Acta Derm Venereol.* 1963; 43: 421-440.
3. Murakami C, de Oliveira Lira Ortega A, Guimarães AS, Gonçalves-Bittar D, Bönecker M, Ciamponi AL. Focal dermal hypoplasia: a case report and literature review. *Oral Surg Oral Med Oral Pathol Oral Radiol Endod.* 2011; 112: 11-18.
4. Duijf PH, van Bokhoven H, Brunner HG. Pathogenesis of split-hand/split-foot malformation. *Hum Mol Genet.* 2003; 12: 51-60.
5. Al Aboud K. Iso-Kikuchi syndrome; an overview. *Our Dermatol Online.* 2012; 3: 145-146.
6. Barrott JJ, Cash GM, Smith AP, Barrow JR, Murtaugh LC. Deletion of mouse Porcn blocks Wnt ligand secretion and reveals an ectodermal etiology of human focal dermal hypoplasia/Goltz syndrome. *Proc Natl Acad Sci U S A.* 2011; 108: 12752-12757.
7. Liu W, Shaver TM, Balasa A, Ljungberg MC, Wang X, Wen S, et al. Deletion of Porcn in mice leads to multiple developmental defects and models human focal dermal hypoplasia (Goltz syndrome). *PLoS One.* 2012; 7: 32331.
8. Wechsler MA, Papa CM, Haberman F, Marion RW. Variable expression in focal dermal hypoplasia. An example of differential X-chromosome inactivation. *Am J Dis Child.* 1988; 142: 297-300.
9. Wang X, Reid Sutton V, Omar Peraza-Llanes J, Yu Z, Rosetta R, Kou YC, et al. Mutations in X-linked PORCN, a putative regulator of Wnt signaling, cause focal dermal hypoplasia. *Nat Genet.* 2007; 39: 836-838.
10. Balmer R, Cameron AC, Adès L, Aldred MJ. Enamel defects and Lyonization in focal dermal hypoplasia. *Oral Surg Oral Med Oral Pathol Oral Radiol Endod.* 2004; 98: 686-691.
11. Goltz RW. Focal dermal hypoplasia syndrome. An update. *Arch Dermatol.* 1992; 128: 1108-1111.
12. Grzeschik KH, Bornholdt D, Oeffner F, König A, del Carmen Boente M, Enders H, et al. Deficiency of PORCN, a regulator of Wnt signaling, is associated with focal dermal hypoplasia. *Nat Genet.* 2007; 39: 833-835.