



First Case of Human Latrodectism in Egypt: Case Report

Mohamed AM Khalaf * and Asmaa S Taghian

Forensic Medicine and Clinical Toxicology Department, Minia University, Egypt

Abstract

The first case of envenoming by *Latrodectus geometricus* in Egypt is described. The accident occurred at the victim's home, in Tookh El-Kheil, Minia governorate. The 29-year-old female victim was bitten on the right forearm. She developed a hyperactive state of the central, autonomic and peripheral nervous systems, respiratory distress, severe abdominal colic with minor local symptoms. Later on, the patient developed paralytic ileus. Unfortunately, due to the lack of the antivenin in Egypt, the patient was treated symptomatically. By the 5th day, she was completely clinically free and discharged the next day.

Keywords: Arachnids; Spiders; *Latrodectus geometricus*; Envenomation; Egypt

Introduction

Latrodectism is a condition that results from envenoming by species belonging to the genus *Latrodectus* (Araneae: Theridiidae) [1]. It is associated with dramatic discharge of neurotransmitter, particularly in the autonomic system [2]. There have been no previous reports of human envenoming by *Latrodectus* species in Egypt. According to the geographic distribution of spider species in Egypt, it is well-known that Minia governorate is devoid of such species as shown by Figure 1 [3]. In this study, we report the first case of latrodectism in this country, which was recorded in the village of Tookh El-Kheil, Minia governorate, Upper Egypt, Egypt. The causal agent identified by a professional taxonomist as *Latrodectus geometricus* (Araneae, Theridiidae) which is, surprisingly, not present in Egypt [3].

Case Presentation

A 29-year-old woman (height: 1.62 m and weight: 67 kg), from Tookh El-Kheil, Minia governorate, Egypt, reported having been bitten by a spider on the right forearm on August 03, 2010, at 4:00 AM. The envenoming took place inside her home while she was preparing the breakfast for her family. The patient immediately developed burning pain at the envenoming site, but she underestimated its importance. Soon, she started to complain of palpitation and severe abdominal pain that forced her to seek medical intervention. On arrival at Minia Poisoning Control Center (PCC), she was agitated with facial pallor. Her blood pressure was 190/110 mmHg; heart rate: 140 beats/min; respiratory rate: 32/min; and oral temperature: 38.7°C. Chest examination revealed normal expansion with marked rhonchi. Sinus tachycardia was shown by electrocardiographic examination. Her pulse was rapid and her venous pulse was normal. Abdominal examination showed tenderness, marked distention and diminished intestinal sounds. Cerebral and cerebellar functions were normal and her cranial nerves were intact. She presented generalized fasciculation in all four limbs and face, hypertonia and hyperreflexia. Random blood glucose level was 240 mg/dl. It was normal by the 2nd day of admission. ECG revealed sinus tachycardia and plain chest x-ray showed bilateral alveolar shadows (Figure 2).

As spider envenomation is not reported in Egypt, the spider antivenin is not available. Symptomatic and supportive treatment was administered consisting of oxygen inhalation, parenteral hydration, non-opiate analgesics, corticosteroids, antibiotics, antispasmodics (containing hyoscine) and benzodiazepines. Also, Antitetanic toxoid was given on arrival.

By the 2nd day of admission, the patient condition started to improve, but the bilateral alveolar shadows persisted and the intestinal sounds decreased. Accordingly, antispasmodic medication was stopped.

By the 3rd day of admission, improvement was marked but the bilateral alveolar shadows persisted and the intestinal sounds were not auscultated. Plain abdominal x-ray showed the presence of paralytic ileus (Figure 3).

OPEN ACCESS

*Correspondence:

Mohamed AM Khalaf, Forensic
Medicine and Clinical Toxicology
Department, Minia University, Egypt,
Tel: 002 01060722209;
E-mail: mohamedabdelaazeem_khalaf@
yahoo.com

Received Date: 11 Aug 2017

Accepted Date: 09 Oct 2017

Published Date: 16 Oct 2017

Citation:

Khalaf MAM, Taghian AS. First Case
of Human Latrodectism in Egypt: Case
Report. *Glob J Emerg Med.* 2017; 1(1):
1003.

Copyright © 2017 Mohamed AM
Khalaf. This is an open access
article distributed under the Creative
Commons Attribution License, which
permits unrestricted use, distribution,
and reproduction in any medium,
provided the original work is properly
cited.

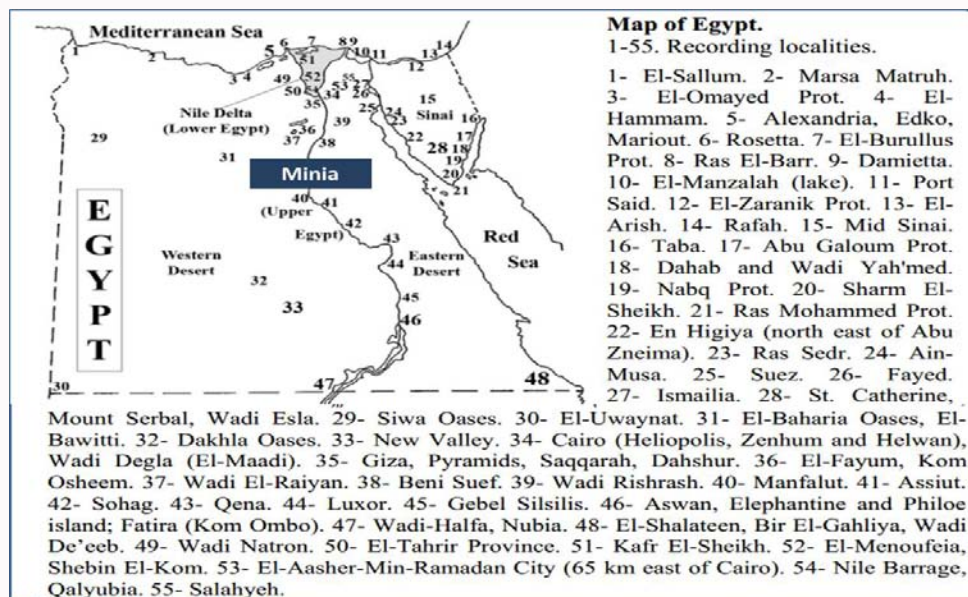


Figure 1: Map of Egypt showing the geographic distribution of spider species. The map also shows that Minia governorate is devoid of all species of venomous spiders [3].

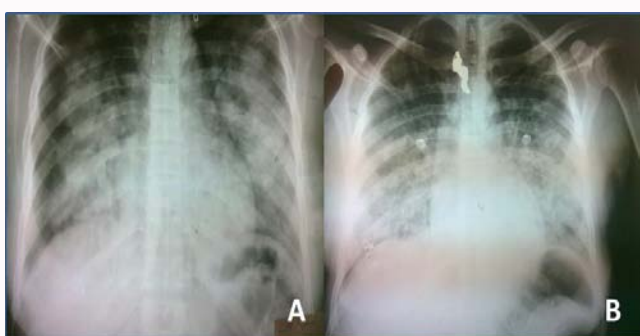


Figure 2: Two plain chest X-ray showing bilateral alveolar shadows on admission (A) and on discharge (B). It revealed the reported bilateral alveolar shadows persisted till the date of discharge.

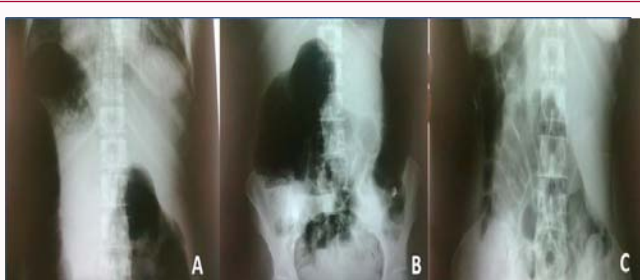

Figure 3: Multiple plain abdomen X-ray showing (A): marked abdominal distension (Day 2); (B): massive abdominal distension and multiple fluid levels (paralytic ileus) (Day 3) and (C): normal plain abdomen X-ray (Day 5).

By the 4th day of admission, the patient condition improved, but the bilateral alveolar shadows persisted. After conservative treatment, the patient passed feces and the intestinal sounds returned but still diminished.

By the 5th day of admission, the patient was clinically free with normal intestinal sounds, but the bilateral alveolar shadows persisted.

By the 6th day of admission, the patient was discharged and

referred to the Department of Chest Diseases to deal with the persistent bilateral alveolar shadows. Later on, it was diagnosed as Miliary Tuberculosis (TB).

Clinical data of the patient throughout the period of hospital stay were plotted in Table 1. Honestly, as we know that our area is devoid of spider, we didn't take the history of being spider envenomation as a true one and we provided this opinion to the father. He left the hospital with marked anger. Two hours later, we were shocked when the patient's father came back with 3 live spiders in 3 glass jars. He told us that he returned to his village and captured them to make us believe him. He added that this spider is present in his village abundantly and he used to see it since he was a child!

The live spiders were sent to the Department of Zoology, Faculty of Science, Minia University for taxonomic study. The taxonomic diagnosis enabled classification of the arachnid agents as *Latrodectus geometricus* (Araneae, Theridiidae).

Discussion

In Egypt, spider envenomation has not been reported before and according to our knowledge, this is the 1st reported case of human latrodectism in Egypt. Latrodectism is a condition that is characterized by an autonomic storm due to the dramatic discharge and enhancement of the neurotransmitters. Thus, as reported in the case of the study, the systemic manifestations were much more marked than the local ones [4].

The prominent reported systemic manifestations were in the form of agitation, fasciculation, tachycardia, hypertension, tachypnea, dyspnea, hyperglycemia and fever. These findings are in agreement with many worldwide previous studies [5-7]. The reported severe abdominal colic that forced the patient to seek medical intervention is in accordance with Kiriakos et al. [8], who reported similar finding. The unexpected finding was the diminished peristaltic sounds that progressed by the 3rd day to paralytic ileus. We have not found any previous studies that reported similar condition. It seems to be a drug-induced condition caused by the excessive use of hyoscine-

Table 1: Clinical data of the patient throughout the period of hospital stay.

Manifestations	Day 1	Day 2	Day 3	Day 4	Day 5
Neurologic:					
Consciousness	Agitated	Agitated	Normal	Normal	Normal
Reflexes	Exaggerated	Exaggerated	Normal	Normal	
Muscle Tone	Increased	Increased	Normal	Normal	
Fasciculation	++++	++	--	--	
Cr. Nerves	Intact	Intact	Normal	Normal	
CVS:					
HR	140/min.	110/min.	92/min.	76/min.	Normal
Bl. P.	190/110	140/90	120/80	110/75	
Dysrhythmias	Sinus tachy.	Sinus tachy.	Normal	Normal	
Respiratory:					
RR	32/min.	21/min.	18/min.	16/min.	bilat. alveolar shadows
Dyspnea	++++	+++	++	+	
Rhonchi	+++	++	+	-	
X-Ray	bilat. alveolar shadows	bilat. alveolar shadows	bilat. alveolar shadows	bilat. alveolar shadows	
Renal:	Oliguria	Normal	Normal	Normal	Normal
Hepatic:	Normal	Normal	Normal	Normal	Normal
Others:					
Temperature	38.7°C	37.8°C	37.4°C	37.2°C	Normal
RBS	240 mg/dl	135 mg/dl	123 mg/dl	127 mg/dl	
GIT	Severe colic	↓ peristalsis	Ileus	↓ peristalsis	

CVS: Cardiovascular System; GIT: Gastrointestinal Tract; Cr. Nerves: Cranial Nerves; HR: Heart Rate; BP: Blood Pressure; RBS: Random Blood Sugar; bilat.: Bilateral.

containing antispasmodics.

The moderately severe case of latrodectism described here is on the contrary to the study conducted by Souza et al. [9] that commented that *Latrodectus geometricus* produces venom that is weakly toxic to humans. In addition, in a series of 45 cases that involved 15 ones of *Latrodectus geometricus* bites, the symptoms and signs were mild and tended to be restricted to the bite site and surrounding tissues [10]. The surprising finding that venomous spider presents in Minia governorate and is well known to the natives, despite the reports that this governorate is free of such arachnids [3], suggests that this arachnid is epidemiologically important, at least in Egypt. The clinical relevance of envenoming of Egyptians by *Latrodectus geometricus* should be further studied, especially taking into consideration that its presence is well known among the rural people but not to the scientific community.

Acknowledgements

We would like to convey our thanks to Professor Mohamed H Ibrahim, Department of Zoology, Faculty of Science, Minia University for performing the taxonomic part of the current study.

References

- Rahmani F, Banan Khojasteh SM, Ebrahimi Bakhtavar H, Rahmani F, Shahsavari Nia K, Faridaalae G. Poisonous spiders: bites, symptoms, and treatment; an educational review. *Emerg (Tehran)*. 2014; 2(2):54-8.
- Ryan NM, Buckley NA, Graudins A. Treatments for Latrodectism—A systematic review on their clinical effectiveness. *Toxins (Basel)*. 2017;9(4):148.
- El-Hennawy HK. A list of Egyptian spiders (revised in 2006). *Serket*. 2006;10(2):65-76.
- Offerman SR, Daubert GP, Clark RF. The treatment of black widow spider envenomation with antivenin *Latrodectus mactans*. A case series. *Perm J*. 2011;15(3):76-81.
- Rohou A, Nield J, Ushkaryov YA. Insecticidal toxins from black widow spider venom. *Toxicon*. 2007;49(4-5):531-49.
- Ali Bshabshe A, Musa A, Ahmed FA. Black widow spider bites experience from tertiary care center in Saudi Arabia. *Avicenna J Med*. 2017;7(2):51-3.
- Garyfallia NA, Dimitrios I, Rania K, Sofia I, Giorgos R, Agoritsa B. *Latrodectus* envenomation in greece. *Perm J*. 2014;18(4):e155-8.
- Kiriakos D, Núñez P, Parababire Y, García M, Medina J, Sousa LD. First case of human latrodectism in Venezuela. *Rev Soc Bras Med Trop*. 2008;41(2):202-4.
- Souza ARB, Bührnheim PF, Lima CSC. Report of a case of latrodectismo occurred in Manaus, Amazonas, Brazil. *J Brazil Soc Trop Med*. 1998;31(1):95-8.
- Müller GJ. Black and brown widow spider bites in South Africa. A series of 45 cases. *S Afr Med J*. 1993;83(6):399-405.