



# Fetus in Fetu: Sequel to a Quadruplet Pregnancy

Hemonta KD<sup>1\*</sup>, Arpita G<sup>2</sup>, Abhinav P<sup>3</sup> and Ashok A<sup>4</sup>

<sup>1</sup>Department of Pediatric Surgery, Assam Medical College, India

<sup>2</sup>Department of Pediatrics, Assam Medical College, India

<sup>3</sup>Department of Anesthesiology, Apeksha Hospital, India

<sup>4</sup>Department of Gynecology, Apeksha Hospital, India

## Abstract

Fetus in Fetu (FIF) is a rare entity, in which a malformed fetus is found inside the body of its twin. FIF is a diamniotic, monochorionic, monozygotic twin that becomes incorporated into the body of the host, mostly within the abdominal cavity. Although more than 200 cases of FIF have been reported in the literature, reports of multiple fetuses within the host are rare. We present a 9-month-old baby boy who presented with a lump in the abdomen. An ultrasound revealed an encapsulated mass with solid and cystic component. An HRCT scan showed structures resembling body parts with incomplete spine and other bones. A laparotomy was performed and a large retroperitoneal cystic mass with three solid masses inside resembling body parts with attached vessels were found. The abdomen was closed and the child made uneventful recovery.

**Keywords:** Fetus in fetu; Teratoma; Twinning

## Introduction

Fetus in Fetu (FIF) is a rare congenital anomaly with an incidence of one per 500,000 births [1]. It is formed as a consequence of an unequal division of the totipotent inner cell mass of a developing blastocyst, which results in an inclusion of a small cell mass within a maturing sister embryo. Thus, a vestigial remnant representing the co-twin in a diamniotic monochorionic pregnancy gets incorporated within the normal co-twin's body [2]. The common sites of occurrence are abdominal cavity (retroperitoneum), posterior mediastinum, sacrococcygeal region and neck [3]. It is commonly seen during early childhood with a male to female ratio of 2:1 [4]. There are reports of single and multiple fetuses within the body of the host; however, a host carrying multiple fetuses within it is extremely rare. In the present case, the host is a nine-month-old male child, part of a quadruplet who carried three incompletely developed fetuses within its abdomen.

## OPEN ACCESS

### \*Correspondence:

Hemonta Kr Dutta, Department of Pediatric Surgery, Assam Medical College, Dibrugarh, Assam, India,

Received Date: 20 Jun 2024

Accepted Date: 03 Jul 2024

Published Date: 09 Jul 2024

### Citation:

Hemonta KD, Arpita G, Abhinav P, Ashok A. Fetus in Fetu: Sequel to a Quadruplet Pregnancy. *Ann Clin Surg.* 2024; 5(1): 1030.

Copyright © 2024 Hemonta KD. This is an open access article distributed under the Creative Commons Attribution License, which permits unrestricted use, distribution, and reproduction in any medium, provided the original work is properly cited.

## Case Presentation

A 9-month-old male child hailed from Arunachal Pradesh, a tribal state in the northeastern part of India presented with a lump in the abdomen. The child was first in birth order, born of normal vaginal delivery at a local hospital. The mother had no significant problem during the antenatal period. On presentation, the child was otherwise asymptomatic and playful. There was no bowel or urinary symptoms. The parents had noticed the lump and brought him to the hospital (Figure 1). An ultrasonography revealed an encapsulated mass with fluid (size- 10 cm × 8 cm × 8 cm) around it in the right side of the abdomen. An HRCT scan showed a complex mass with bony structures resembling incomplete spine and other bones (Figure 2). A laparotomy was performed and a large retroperitoneal cystic mass with three solid masses inside resembling body parts with attached vascular pedicles were found (weight-800 gm). Two of the fetuses had vestigial limbs and the third had fleshy mass with a pedicle (Figure 2). The abdomen was closed and the child made uneventful recovery (Figures 3A, 3B).

## Discussion

Since the first report of fetus in fetu by Meckel in the late 18<sup>th</sup> century there have been more than 200 case reports, although many of them did not have the characteristic features of an FIF [1]. Two hypothesis has been suggested to explain the embryo-pathogenesis of FIF: The "Parasitic twin theory" suggests a normal fetus becomes enveloped inside the twin partner and becomes dependent on its blood supply [5]. According to "Teratoma theory," it is a highly differentiated form of mature teratoma [6]. It is important to distinguish FIF from teratomas since the latter condition has a distinct

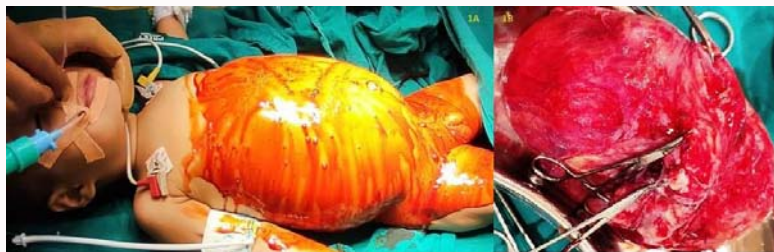

Figure 1: A) The child with the lump. B) The encapsulated mass.

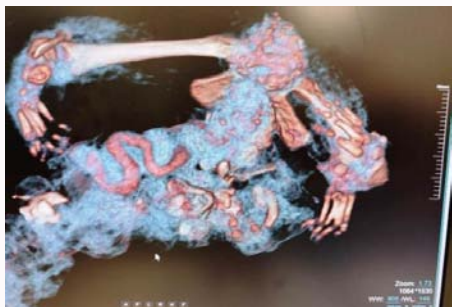


Figure 2: HRCT shows limb bones, pelvic girdle, etc.

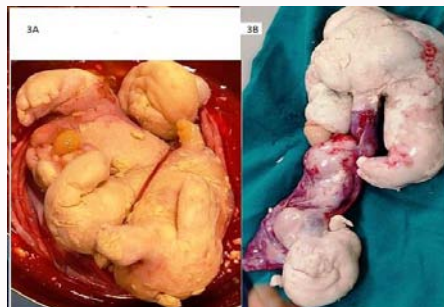


Figure 3A, 3B: Three fetuses with vestigial limbs & vascular pedicles.

malignant potential in contrast to FIF, which is benign in origin [7]. Willis described the following characteristics for FIF: (a) a separate vertebral column, which demonstrates that the fetus has passed through a primary stage after gastrulation, involving formation of the neural tube, metamerization, and symmetrical development around its axis and (b) the organs should have developed in an organized manner with some degree of maturation [8]. As many reported cases did not have a spinal column, Gonzalez-Crussi proposed another definition of FIF as, “any structure in which the fetal form is in a very high development of organogenesis” and linked it to the presence of a vertebral axis [9]. Spencer in 2001 further modified the criteria of FIF as follows: (a) be enclosed within a distinct sac, (b) be partially or completely covered by normal skin, (c) have grossly recognizable anatomic parts, (d) be attached to the host by only a few relatively large blood vessels, and (e) either be located immediately adjacent to one of the sites of attachment of conjoint twins or be associated with the neural tube or the gastrointestinal system [10]. Our case fulfils these criteria of Spencer (Figure 1A, 1B).

Most of the reported cases of FIF were noted before 18 months of age [11] and the commonest location of FIF being retroperitoneum, as noted in the present case [12]. FIF with multiple fetuses have been reported. Hasan & Ebrahim reported a case of FIF as part of triplet pregnancy, in which one of the viable twins had FIF in his abdomen [13]. The symptoms of FIF are primarily due to its mass effect such as abdominal distension, feeding difficulty, constipation, urinary or respiratory symptoms. Initial diagnosis is usually made with an ultrasonography and a CT or MRI scan confirms the diagnosis. FIF have been diagnosed on antenatal ultrasonography and fetal MRI [14]. In the present case, the child was asymptomatic except the presence of an abdominal lump noted by parents. An MRI scan showed three distinct masses with long bones, limbs and part of pelvic bones with independent vascular pedicles.

Without the characteristic features of FIF as described by Spencer or Willis, the condition is often confused with teratoma. Prescher LM states that FIF and teratoma have same pathology but are detected

at different stage of maturation [15]. There are reports of FIF transforming into teratoma with malignant components [7].

## Conclusion

FIF is a rare anomaly that should be considered in any child presenting with complex abdominal mass. Presence of axial and long bones within the mass in CT or MRI scan confirms the diagnosis of FIF. Surgical excision is the treatment of choice to alleviate symptoms and to prevent future transformation into teratoma with its associated complications.

## References

1. Abdur-Rahman LO, Abdul-Kadir AY, Rahman AG. Fetus-in-fetu in a 6-month-old. *Afr J Paediatr Surg*. 2008;5(2):96-8.
2. Sitharama SA, Jindal B, Vuriti MK, Naredi BK, Krishnamurthy S, Subramania DB. Fetus in Fetu: Case report and brief review of literature on embryologic origin, clinical presentation, imaging and differential diagnosis. *Pol J Radiol*. 2017;82:46-9.
3. Arlikar JD, Mane SB, Dhende NP, Sanghvi Y, Valand AG, Butale PR. Fetus in fetu: 2 case reports and review of literature. *Pediatr Surg Int*. 2009;25(3):289-92.
4. Yaacob R, Mokhtar AZ, Abang Jamari DZ, Jaafar N. The entrapped twin: A case of fetus-in-fetu. *BMJ Case Rep*. 2017;2017:bcr2017220801.
5. Chua JHY, Chui CH, Sai Prasad TR, Jacobsen AS, Meenakshi A, Hwang WS. Fetus-in-fetu in the pelvis. *Ann Acad Med Singap*. 2005;34(10):646-9.
6. Basu A, Jagdish S, Iyenger KR, Basu D. Fetus in fetu or differentiated teratomas? *Indian J Pathol Microbiol*. 2006;49(4):563-5.
7. Hopkins KL, Dickson PK, Ball TI, Ricketts RR, O'Shea PA, Abramowsky CR. Fetus-in-fetu with malignant recurrence. *J Pediatr Surg*. 1997;32(10):1476-9.
8. Willis RA. The structure of teratomata. *J Path Bacteriol*. 1935;40(1):1-36.
9. Gonzalez-Crussi F. Atlas of tumor pathology. In: Extragonadal teratomas. 2<sup>nd</sup> Ser, fasc 18. Washington DC: Armed Forces Institute of Pathology; 1982.

10. Spencer R. Parasitic conjoined twins: External, internal (fetus in fetu and teratomas) and detached (acardiac). *Clin Anat.* 2001;14(6):428-44.
11. Hoeffel CC, Nguyen KQ, Phan HT, Truong NH, Nguyen TS, Tran TT, et al. Fetus in fetu: A case report and literature review. *Pediatrics.* 2000;105(6):1335-44.
12. Dutta HK, Thomas JK, Sahewala NK, Patgiri DK. Fetus in fetu in a neonate: Report of a case. *Surg Today.* 2013;43(5):547-9.
13. Hasan B, Ebrahim M. Fetus in fetu: A case of vanishing triplet phenomena. *Cureus.* 2022;14(10):e30342.
14. Puranik RU, Joshi P, Jahanvi V, Handu AT, Puli KR. Antenatally detected fetus in fetu case report. *BJR Case Rep.* 2023;9(3):20230001.
15. Prescher LM, William Butler J, Taylor Vachon A, Marion CH, Thomas L, Romeo Jr CI. Fetus in fetu: Review of the literature over the past 15 years. *J Ped Surg Case Rep.* 2015;3:554e562.