Annals of Thoracic Oncology Research

Case Report
Published: 12 Jan, 2018

False-Positive Finding on Positron Emission Tomography after Lung Cancer Surgery: Back to Operative Report

Tugba Cosgun[1], Erkan Kaba[1], Kemal Ayalp[2] and Alper Toker[2]*

[1]Department of Thoracic Surgery, Istanbul Bilim University Medical Faculty, Turkey

[2]Department of Thoracic Surgery, Group Florence Nightingale Hospitals, Turkey

Abstract

^{18}F-Fluorodeoxyglucose-Positron Emission Tomography/Computed Tomography (FDG-PET/CT) is an imaging method for staging/restaging of various malignancies. False positivity, which is a major handicap of FDG-PET/CT, can be seen particularly in active inflammation or infectious areas. We report two cases of false-positive FDG-uptake during postoperative follow-up due to pledgeted sutures for the treatment of chylothorax.

Keywords: Fluorodeoxyglucose-positron emission tomography; Chylothorax; False-positive

Introduction

^{18}F-Fluorodeoxyglucose-Positron Emission Tomography/Computed Tomography (FDG-PET/CT) has an effective role in diagnosis and postoperative management of almost all malignancies [1]. PET/CT is not specific for malignancy only, and false positivity has been reported to occur with granulomas, which could have developed in response to suture materials [1]. We described two cases where postoperative FDG-PET/CT demonstrated a local recurrence, which was later shown to be false-positive due to pledgeted sutures placed for treatment of chylothorax during surgery.

Case Presentation

Case 1: A 60-year-old man was referred with two lesions in the right upper lobe detected during follow-up. Standard Uptake Values (SUVmax) of the lesions were 3 to 5.

Robot-assisted right upper lobectomy and systematic mediastinal lymph node dissection were performed. Both tumours were adenocarcinomas, and the largest diameters were 1.5 cm to 1 cm, respectively. Chylous drainage started on postoperative day 1. Firstly oral intake was stopped and total parenteral nutrition was initiated. High amount of chylous drainage (>800 mL despite cessation of oral nutrition) continued for three days. Reoperation was performed on day 4. Areas with lymphatic drainage were closed with pledgeted sutures, and the ductus thoracicus was ligated to reassure cessation of leakage. He was discharged five days after reoperation. He underwent adjuvant chemotherapy after surgical recovery.

A new nodule was detected in the left upper lobe 18 months postoperatively. SUVmax of the new left upper lobe lesion was 3.5. A high FDG-uptake was reported on the right mediastinal side (Figure 1). These locations, identified from the operative reports, were where pledgeted sutures were placed to stop chylous drainage. No progression was observed in this area on CT and FDG-PET/CT during follow-up intervals of three and nine months.

Case 2: A 40-year-old man presented with pain in left shoulder. Examinations revealed a Pancoast tumour that invaded the first three ribs and mediastinum. Tumour was confirmed as adenocarcinoma. The tumour regressed and surgery was planned after neoadjuvant therapy. The first five ribs were resected and disarticulated from the vertebrae posteriorly via a Paulson incision. After the subclavian vein was divided, lobectomy was performed. Because of the radical mediastinal dissection, Polytetrafluoroethylene (PTFE) pledgeted sutures (with 4-0 polypropylene) were placed on the mediastinal side to avoid possible chylothorax. A low fat diet was provided for three days postoperatively. He was discharged from hospital on postoperative day 6. He underwent consolidation chemotherapy.

A control FDG-PET/CT three months postoperatively revealed an area with SUVmax 5.23. After operative reports and early postoperative chest CT were revised, this area was confirmed to

OPEN ACCESS

***Correspondence:**
Tugba Cosgun. Department of Thoracic Surgery, Istanbul Bilim University Istanbul, Turkey,
E-mail: tugba_cosgun@hotmail.com

Received Date: *20 Dec 2017*
Accepted Date: *05 Jan 2018*
Published Date: *12 Jan 2018*

Citation:
Cosgun T, Kaba E, Ayalp K, Toker A. False-Positive Finding on Positron Emission Tomography after Lung Cancer Surgery: Back to Operative Report. Ann Thorac Oncol Res. 2018; 1(2): 1007.

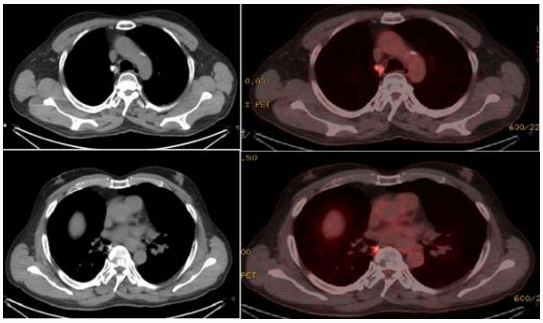

Figure 1: High FDG-uptake on the right mediastinal side where pledgeted sutures were placed to stop chylous drainage.

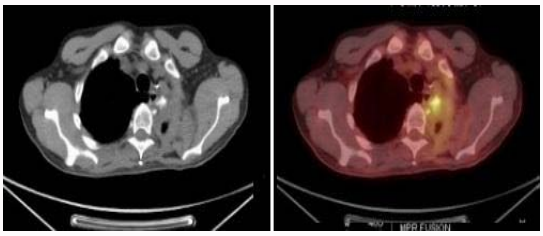

Figure 2: High FDG-uptake on the left side where pledgeted sutures were placed.

be where pledgeted sutures were placed during surgery (Figure 2). Images remained stable at follow-up six and 12 months later.

Discussion

Chylothorax emerges when lymphatic fluid (chyle) accumulates in the pleural cavity due to leakage from lymphatic vessels [2]. Treatment of chylothorax includes conservative approaches, surgery, chemotherapy and even radiotherapy [2]. Cerfolio et al. [3] specified that if chylothorax occurs after surgery, reoperation should not be delayed.

After locating the leakage, ligation is performed a few centimetres below. Many centres prefer to use pledgeted 4-0 monofilament nonabsorbable sutures for ligation [3]. We regularly use pledgeted sutures on suspicious areas of leakage during surgery if we foresee that the patient is at risk for postoperative chylothorax.

FDG-PET/CT imaging is a procedure that has become standard in the diagnosis of cancers, restaging and monitoring of therapeutic efficacy. Tissues can demonstrate false high FDG-uptake due to acute or chronic inflammations, abscesses, inflammatory lymphadenopathies, and following radiotherapy [1].

We use pledgeted 4-0 Prolene sutures to close the possible area of chylous leakage. Prolene suture rarely causes granulomas, but pledgeted PTFE sutures may cause granulomas more often. Reports have demonstrated clinical situations with Teflon (which is the best known brand name of PTFE-based formulas) injection into paralysed vocal cords due to recurrent laryngeal nerve paralysis, causing increased FDG-uptake in PET/CT. Teflon already was found to cause granulomatous reactions with higher FDG-uptake. We also demonstrated that pledgeted sutures can raise granulomatous areas with higher FDG-uptake. Ozguven et al. [4] reported that hypermetabolism in the vocal cord was similar one week and three months after Teflon injection.

Treatment strategy is complicated in cases high FDG-uptake at postoperative period. Surgical exploration can be considered due to possible recurrence of malignancy. However, awareness of previous surgery and prior treatment details may prevent interpretation errors and potentially prevent overestimation of the disease during unnecessary surgery. In conclusion, referring to operative notes and details of pledgeted suture localisation may be an important factor during follow-up. More conservative management strategies can be followed, particularly for postoperative borderline SUV values on PET-CT close to surgical sites. We advise close follow-up in such cases. In our cases, the areas with FDG-uptake were stable during follow-up.

Acknowledgement

We would like to thank to Dr. Canan Akman and Emel Ceylan Gunay for the assessment of CT and PET-CT of patients.

References

1. Lim JW, TangCL, Keng GH. False-positive F-18 fluorodeoxyglucose combined PET/CT scans from suture granuloma and chronic inflammation: report of two cases and review of literature. Ann Acad Med Singapore. 2005;34(7):457-60.
2. Schild HH, Strassburg CP, Welz A, Kalff J. Treatment options in patients with chylothorax. Dtsch Arztebl Int. 2013;110(48):819-26.
3. Cerfolio R. Ligation of the Thoracic Duct for Chylothorax. CTSNet. 2009.
4. OzguvenS, DedeF, ErdilTY, Turoglu HT. Marked uptake of fluorodeoxyglucose in a vocal cord after medialization: Acute and subacute positron emission tomography/computed tomography findings. Indian J Nucl Med. 2014;29(4):289-90.