



## Excessive Dynamic Airway Collapse as Unusual Presentation of Obstructive Sleep Apnoea Syndrome: Case Report

Jiang Sheng-hua<sup>1\*</sup>, Wang Ji-wang<sup>2</sup>, Shan Feng-lian<sup>1</sup> and Jiang Lu-ning<sup>1</sup>

<sup>1</sup>Department of Respiratory Medicine, Affiliated Hospital of Jining Medical University, China

<sup>2</sup>Department of Respiratory Medicine, Jiangsu Province Hospital, China

### Abstract

Excessive dynamic airway collapse (EDAC) is one of uncommonly chronic respiratory conditions. Here we reported a 43-year-old lady who was suffering bronchial asthma and snoring. We shared our experience in diagnosis, treatment her uncommon disease. And the relative literatures were reviewed.

**Keywords:** Obstructive sleep apnoea syndrome; Excessive dynamic airway collapse management

### Introduction

Excessive dynamic airway collapse (HDAC) or tracheobronchomalacia (TBM) refers to patients who were presented with features of losing structural integrity of the airway walls. EDAC usually defined as excessive bulging of the posterior membrane into the airway lumen during expiration without cartilage collapse [1]. Typical phenomenons known as chronic cough, recurrent pulmonary infections and dyspnea on exertion. It is usually difficult to differentiate EDAC from other conditions that cause those symptoms. Here, we present an unusual case of a patient with EDAC, who interfered with abnormal respiration during the night causing sleep apnoea.

### Case Report

A 43-year- lady was referred to Affiliated Hospital of Jining Medical University at June 30, 2016, worsening of her chronic airway disease in the last 5 days. She was diagnosed as asthma for eight years, complained of coughing and shortness of breath after exposure to rapid changes in the temperature or irritant gas. But she didn't regularly receive medical treatment to control asthma. Her husband described the patient also suffering from chronic snoring and breathing cessation about 5 years. She was non smoker with no history of other chronic diseases.

Physical examination: Pharynx wasn't congestive and tonsils were not enlarged. Respiratory movement was bilaterally symmetric with the frequency of 19/min. Breathing sounds were clear all over the lung fields. No moist rales or rhonchis was heard. Pulmonary function testing (PFT) revealed no marked airflow limitation, the FEV1, FEV1/FVC ratio were normal. The bronchial provocation test showed positive with inhalation of methacholine. Impression diagnose: asthma, obstructive sleep apnoea syndrome (OSAS)?.

Using nebulization of budesonide combining terbutaline q8h for treatment of asthma, but she was worse at night and in the supine position. Polysomnography demonstrated moderate respiratory distress, snoring with an apnea hypopnea index (AHI) of 22.8/h (mostly obstructive events), the lowest SaO<sub>2</sub> was 79%, the longest apnea time was 75s, which met the diagnostic standard of moderate OSAS.

The patients were classified as normal weight (BMI: 19.4). Her diagnosis of OSAS is worthy to be discussed further. In addition to PFT and polysomnography, CT scan of the chest and three-dimensional reconstruction of trachea were recommended to identify possible obstruction by tracheal stenosis. Reports as follows: There were no abnormal in the tracheal and main bronchus with inspiratory. No pharyngolaryngeal neoplasms were not found at the same time. (Figure 1 and 2) on the basis of CT findings. Our team proposed bronchoscopy to gather dynamic information about his disease process. On bronchoscopy, this patient's central airway disorder was diagnosed. Including: the posterior membrane bulges in and excessively narrows the airway lumen by more than

### OPEN ACCESS

#### \*Correspondence:

Jiang Lu-ning, Department of Respiratory Medicine, Affiliated Hospital of Jining Medical University, Shandong, 272019, China,

E-mail: fyhy3069@163.com

Received Date: 30 Aug 2016

Accepted Date: 20 Sep 2016

Published Date: 27 Sep 2016

#### Citation:

Sheng-hua J, Ji-wang W, Feng-lian S, Lu-ning J. Excessive Dynamic Airway Collapse as Unusual Presentation of Obstructive Sleep Apnoea Syndrome: Case Report. *J Respir Med Lung Dis.* 2016; 1(1): 1001.

Copyright © 2016 Sheng-hua J. This is an open access article distributed under the Creative Commons Attribution License, which permits unrestricted use, distribution, and reproduction in any medium, provided the original work is properly cited.

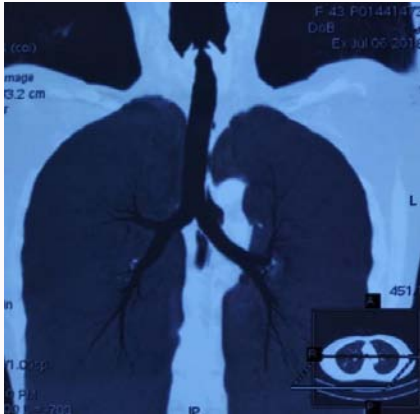

Figure 1: CT.

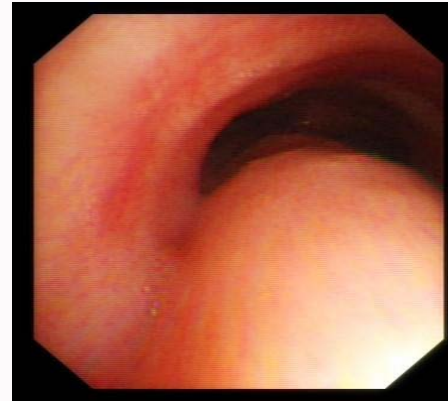


Figure 3: Bronchoscopic.

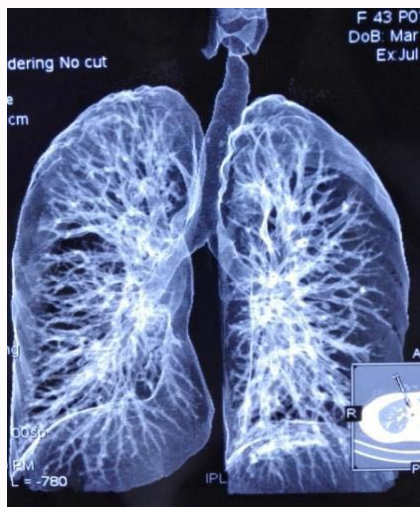

Figure 2: CT.

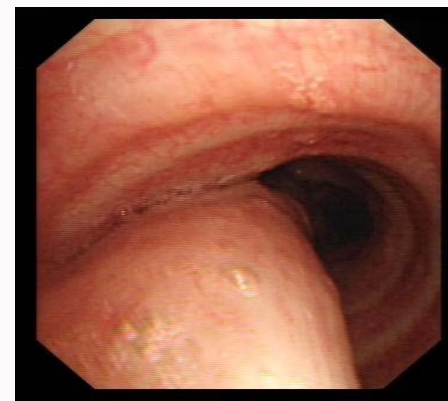


Figure 4: Bronchoscopic.

50% during tidal expiration, the collapse of the posterior membrane closes the airway completely, consistent with EDAC (Figure 3 and 4).

**Discussion**

EDAC is a rare disease with weakness of the trachea, involving posterior membrane invagination into the airway lumen, this posterior portion of the airway membrane is either unable to maintain normal tone or is simply redundant. Bronchoscopy is acknowledged to be the gold-standard diagnostic measure for EDAC. The standard is collapse of the airways with forced expiratory maneuvers is 50% or more [1,2].

Dyspnea, recurrent pneumonia, and inability to raise secretions are nonspecific but common findings in patients with EDAC, and may mimic many diseases [3]. Asthma severity in these difficult-to-treat patients is often further worsened by the coexistence of one or more co-morbidities, previous studies reported EDAC prevalence to be 31% in patients with asthma [4]. The most common secondary causes in adults include airway inflammation and mechanical manipulation. In our patient, the diagnosis of EDAC was clear. And it's secondary to asthma. Which causing decreased elastic recoil and increased peripheral airway resistance. The uniqueness of this case is related to snoring and sleep apnoea symptoms. On examination, her somato type were not inconsistent with typical OSAS. Upper airway abnormalities associated with OSAS also were not found, such as nasal

congestion, rhinitis, chronic sinusitis, and nasopharyngeal anatomic abnormalities. But evidence revealed moderate OSAS. Bronchoscopy was indicated in this patient to diagnose and determine the severity of EDAC which couldn't showed by the regular CT scan. Based on treatment of bronchodilators, auto-CPAP 12 cm H<sub>2</sub>O was prescribed at night for the management of EDAC. In summary, to our knowledge, there are no cases of obstructive sleep apnoea syndrome due to EDAC [5]. EDAC is usually incidentally detected in patients with underlying lung disease. With the increasing popularity of flexible bronchoscopy, it is being well recognized as the gold standard diagnostic criterion. For those patients, the recognition of both sets of morbidities is important to guide practical treatment decisions.

**References**

1. Choo EM, Seaman JC, Musani AI. Tracheomalacia/Tracheobronchomalacia and hyperdynamic airway collapse. *Immunol Allergy Clin North Am.* 2013; 33: 23-34.
2. Murgu S, Colt H. Tracheobronchomalacia and excessive dynamic airway collapse. *Clin Chest Med.* 2013; 34: 527-555.
3. Bozoghlanian V, Williams SJ, Ismail H, Gutta R. Dynamic airway collapse: a frequently misdiagnosed asthma mimicker. *Ann Allergy Asthma Immunol.* 2016; 116: 87-88.
4. Dal Negro RW, Tognella S, Guerriero M, Micheletto C. Prevalence of tracheobronchomalacia and excessive dynamic airway collapse in bronchial asthma of different severity. *Multidiscip Respir Med.* 2013; 8: 32.
5. Muzumdar H, Nandalike K, Bent J, Arens R. Obstructive sleep apnea due to extrathoracic tracheomalacia. *J Clin Sleep Med.* 2013; 9: 163-164.