



Does B-Tricalcium Phosphate Work as a Bone Regenerative Material?

Maged Iskaros*, Joel Silver, Jeffery S Blye and Maria P Rodriguez Cardenas

Department of Cariology and Comprehensive Care, New York University College of Dentistry, USA

Abstract

Improved surgical site preparation and implant integration is demonstrated when beta tricalcium phosphate is inserted into extraction sites prior to implant placement. Mandibular first and second molars were extracted and immediate placement of this calcium salt resulted in improved vertical and horizontal bone deposition. These clinical cases correlate with other available evidence of accelerated healing, and dense bone deposition around extraction sites prior to implant placement.

Introduction

Teeth need the support of alveolar bone to function properly in the oral cavity. When teeth are extracted the surgical procedure leads to typical bone deficiency of the ridge width and height of the alveolar crest producing problems in placement of screw titanium implants. The resorption process starts immediately after the extraction. It is believed that there is an average of 40% to 60% decrease in horizontal and vertical dimensions of the alveolar ridge in the extracted tooth location during the first two years. Many different bone substitutions are used to restore the alveolar bone such as autografts, allografts, xenografts, synthetic biomaterials and osteoactive agents. Ridge preservation using guided bone regeneration technique has been proven to improve ridge height and width dimensions compared to tooth extraction only. The use of beta tricalcium phosphate also known as TCP shows great osteoconductive potential because of its macro porosity which leads to good bone growth. It bonds directly to bone which improves healing the site of the extracted tooth. TCP is one of the main combustion products of bone ash and it is also contained in mineral rocks called whitockite.

OPEN ACCESS

*Correspondence:

Maged Iskaros, Department of
Cariology and Comprehensive Care,
New York University College of
Dentistry, USA,

E-mail: iskarosrus@aol.com

Received Date: 08 Sep 2017

Accepted Date: 15 Oct 2017

Published Date: 22 Oct 2017

Citation:

Iskaros M, Silver J, Blye JS, Cardenas
MPR. Does B-Tricalcium Phosphate
Work as a Bone Regenerative
Material?. *J Dent Oral Biol*. 2017;
2(18): 1106.

ISSN: 2475-5680

Copyright © 2017 Maged Iskaros. This
is an open access article distributed
under the Creative Commons Attribution
License, which permits unrestricted
use, distribution, and reproduction in
any medium, provided the original work
is properly cited.

There are three recognized polymorphs of tricalcium phosphate:

- Bi hexdral beta
- Monoclinic alpha
- Hexagonal alpha/beta

There are chemical biological differences between beta and alpha forms of TCP. The alpha forms more soluble and biodegradable than the beta form.

There are many uses of TCP in various products:

- It is used in powdered spices as an anti-caking agent
- In baking soda
- In fertilizers
- Additive to cheese products
- In antacids
- Porcelain and dental powders
- Repairing bony defects when grafting is not feasible

As a bone grafting agent, it could be used alone or in combination with other biodegradable agents, such as resorbable poly glycolic acid. There have been numerous articles written evaluating the effect of a multi porous beta tricalcium phosphate on bone density around dental implants inserted into fresh extraction sites. The results of the studies showed significant increases in bone density measurements of the sites in which TCP were introduce to. On the basis of the many

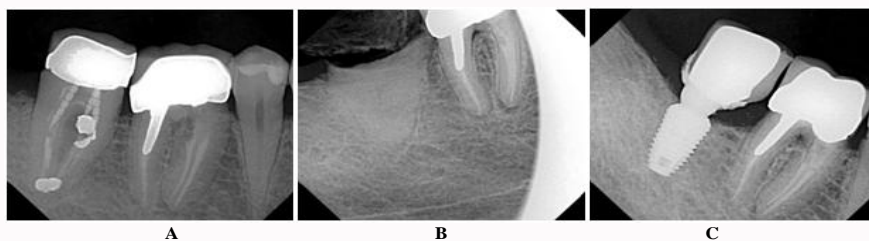


Figure 1: 59-year-old male with uneventful medical history. A) Tooth #31 to be extracted. B) After removal, TCP placed into extraction socket; no suture was placed. C) Implant completely restored with PFM after flapless implant placement.

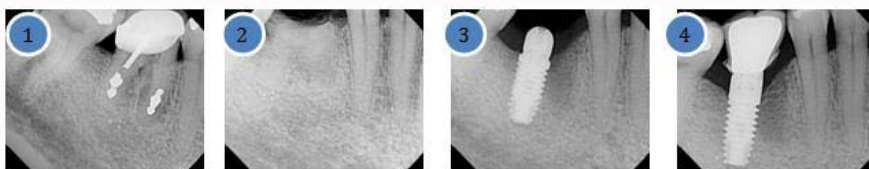

Figure 2: 53-year-old male with uneventful medical history. 1) Tooth #30 to be extracted. 2) Immediate socket graft after extraction with TCP. 3) Healing abutment placed after flapless implant placement with infiltration only. 4) Final crown on fully integrated implant.

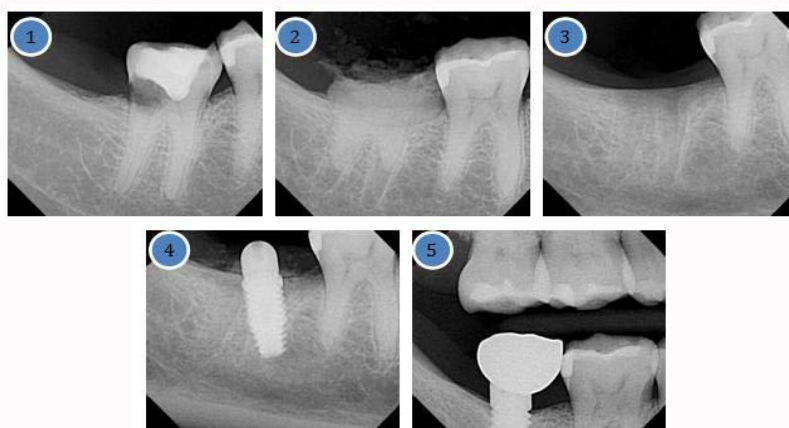


Figure 3: 28-year-old female with uneventful medical history. 1) Tooth #31 to be extracted. 2) Immediate socket graft. 3) 3 months after extraction, watch bone level and density of bone. 4) Flapless implant placement with healing abutment with infiltration. 5) Complete crown restoration on fully osseointegrated implant.

studies presented it seems that the pure phase multiphasic beta TCP may enhance bone density around gaps in immediate placed dental implants. Because of these positive results the question is how is the use of TCP in immediate placement in tooth extraction sites increase bone density and bone height of these sites. Therefore, in our case study we are using beta tricalcium phosphate to evaluate the alveolar ridge preservation achieved following tooth extraction in the mandibular arch of the jaw involving the extractions of firsts and second molars.

Materials and Methods

The materials used in these clinical cases are: beta tricalcium used alone without any synthetic and biodegradable. Additive local anesthesia lidocaine 2% 1:100,000 with epinephrine. No sutures were placed, and no flap surgery was used in the incorporation of the materials to the involved surface sites. No bone matrix materials were used, neither natural nor synthetic matrix materials. Four patients had an age range of 28-70 years. Three of them are male and one is female. These patients were in good health and presented with no underlying prior medical significant history or complications related to prior and post dental treatment. None were smokers, and none were taking

any medications. No history of diabetes, hypertension, or bleeding disorders existed in any of these patients. None had a history of use of heparin, biologics, chemotherapy, pregnancy. Bisphosphonate use was negative. Each patient presented with 4 wall bone defects, and beta tricalcium phosphate was placed in the extraction sites, with no flap, and no sutures. Informed consent was obtained prior to surgery. These patients were followed up after one week, three months and six months at which point final restorative procedures were completed. Cement retained crowns were placed. Literature exists evaluating the effect of depositions of beta tricalcium phosphate and increased bone density around dental implants inserted into fresh extraction sites. This material can be used alone or in combination with biodegradable, resorbable polymers to promote healing. This paper will discuss and correlate the results obtained in our clinical cases. Does this material play a role in increasing the bone density? Does this leads to improved surgical site preparation and better implant integration and success? Grafting materials can promote osteogenesis, osseous conduction and osseous induction without additive chemicals beta tricalcium phosphate serves as an osseous conductive material. It provides a matrix, as its porosity allows increased blood flow, and cellular migration for enhanced healing. One study where Collagen β -TCP-

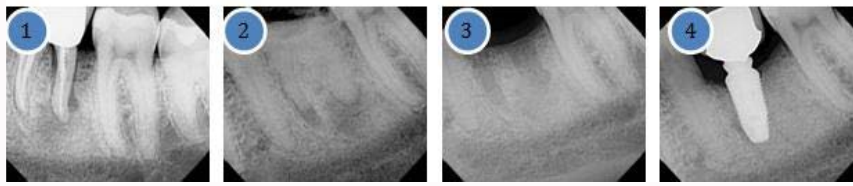


Figure 4: 30-year-old male with uneventful medical history. 1) Tooth #19 to be extracted. 2) Immediate socket graft after extraction. 3) 3 months after socket graft. 4) Final crown on fully integrated implant.

Cl g and beta tricalcium phosphate were placed in human extraction sites, it appears to show improved bone and socket morphology, which showed improved dental implant placement success after a 9 month healing period.

Some studies have formulated protocols for bone augmentation with immediate placement of implants after extraction. This offers the benefit of an improved survival rate, and minimization of infection. Deposition of B-TCP helps achieve soft tissue healing and decreases the risk of infection. Studies have not evaluated and documented the long-term outcome of using B-TCP as an adjunctive grafting material simultaneously with implant placement into extraction sites.

Our objectives are to:

- Preserve the most possible alveolar bone during extraction (free natural bone full of osteoblasts) which it is called atraumatic extraction.
- Interruptions and slowing down of normal physiologic healing process following bone surgery.
- Utilize the beta tricalcium phosphate as a bone substitute material. It is natural, biodegradable, harmless, and relatively inexpensive. It interacts actively with the blood clot after a fresh bony socket exposure, and starts the osteoconductive stimulation immediately from this material (TCP).
- The socket is filled with TCP after the tooth extraction, and it is over filled. It is noteworthy to mention that this material acts as a membrane as well as an osteoconductive grafting material by forming a scaffold with the blood clot. Initiates the osteoblastic activity immediately. No suture is used to close the socket.

By following the above method, we are keeping the width of the alveolar process bucco-lingually intact. This is tension free soft tissue kept flapless technique takes advantage of the natural healing processes in addition to limiting bone resorption classically seen with suturing. All patients were seen for routine post-op evaluation within 2 weeks, and no adverse reactions were observed/reported for any case. The material was found to be promoting and accelerating the healing process. In addition to the previously mentioned beneficial applications, TCP was found to act as an artificial hemostatic plug. After a healing period of 3-4 months, a flapless entry into the socket and a complete osteotomy procedure is performed keeping the bucco-lingual soft and hard tissue intact. In the majority of the cases, a healing abutment is placed instead of a covering screw, again to avoid secondary stage surgery (uncovering procedure) and no sutures are utilized (any time there is an opening of a flap that exposes bone, resorption will occur). All patients aged 28-59 years, both male and female present with uneventful medical conditions. The authors are presenting 4 cases in the first and second mandibular molar region. The surgical procedure and protocol was the same as above. Pre-surgical medication was 2 capsules of Amoxicillin 500 mg and 2 tablets

of Ibuprofen 600 mg, one hour before the procedure, and to continue for 5 days after the surgery (Figure 1). No inferior dental block was given only infiltration using 2% lidocaine, buccal and lingual injection only. The rationale behind this is to maintain sensation during the procedure, preventing approaching or accidental dropping into the mandibular canal (Figure 2). There is no innervation in the bone so there is no need to block the posterior mandibular region. All patients tolerated the procedure with no swelling, no bleeding, and very little discomfort with most patients returning back to work right after the procedure. During drilling the alveolar bone, it was noticed that there was an actual mix of hard substance, mix of bone and TCP (Figure 3). The same bone type we usually experience in the lower mandibular region, type D2 (bone density quality found in the anterior mandible and posterior mandible). The entire implant body was submerged until the last thread, then the healing abutment was placed, no suture since there is no flap (Figure 4). After 3 months, the healing abutment is removed and replaced with a regular abutment (prepared inside mouth followed by fabrication of a provisional acrylic crown). In many cases it will be appropriate to take the final impression for the final crown when the gingival condition permits.

Discussion and Conclusions

Using tricalcium phosphate 5 also known as TCP can minimize complications and failure of dental implants. Using TCP as a bone grafting material and a bone substance immediately after tooth extraction was found to be very beneficial to keep the bone height and width, and to slow down the shrinkage associated with healing. It is suggested that it promotes healing, stops bleeding, and is osteoconductive for alveolar bone. In this case report, the cases presented used the beta form of tricalcium phosphate as an adjunct, placed immediately post surgically in extraction sites. The extractions were minimally traumatic, and no flap was exposed and no sutures were placed. We presented four cases where these sites were treatment planned for implant placement. We showed bony defects after the extraction of mandibular first and second molars were repaired. Dental implant placement success is an important mission for dental practice. As practitioners we seek consistent successful outcomes. By applying the appropriate biological principles of how the human body reacts after bone trauma (tooth extraction), using TCP mixed with a fresh blood clot in a healthy environment, will initiate and lead to fibroblastic and osteoblastic activity resulting in new bone formation [1-3]. TCP is integrated into healthy bone. Subsequently that will be very helpful and highly desirable when the time comes for implant placement. This is a more predictable way to achieve enough bone suitable for implant placement without an unpredictable tissue graft that may not work. Implant use has become one of the preferred modes of restorative choice to replace missing teeth. Instead of utilizing fixed bridgework to replace a single tooth most dentists and patients opt for a single implant and crown. Adjacent teeth are not prepared, and future implant success seems to be more predictable.

Criteria to measure success include -the absence of implant mobility, the absence of pain at rest and during function, no bleeding, and no inflammation of the soft tissue. Bone defects arising after the implant is placed would indicate infection and failure. In one animal study monkeys were sacrificed and the implant socket site specimens were analyzed histologically and with histomorphometry. It was concluded "the poly caprolactone-tricalcium phosphate scaffold showed better maintenance of the alveolar contour as compared to autogenous particulate bone at 6 months" [4]. Utilizing TCP as an osseous conductive grafting material after tooth extraction shows promising results due to the ability of this material to promote a good healing environment [1-3,5]. In the twenty years it has been used by the author it has not shown foreign body reactions and appears to be extremely safe.

References

1. Damron TA. Use of 3D beta-tricalcium phosphate (Vitoss) scaffolds in repairing bone defects. *Nanomedicine (Lond)*. 2007;2(6):763-75.
2. Brkovic BM, Prasad HS, Rohrer MD, Konandreas G, Agrogiannis G, Antunovic D, et al. Beta-tricalcium phosphate/type I collagen cones with or without a barrier membrane in human extraction socket healing: clinical, histologic, histomorphometric, and immunohistochemical evaluation. *Clin Oral Investig*. 2012;16(2):581-90.
3. Nyan M, Miyahara T, Noritake K, Hao J, Rodriguez R, Kasugai S. Feasibility of alpha tricalcium phosphate for vertical bone augmentation. *J Investig Clin Dent*. 2014;5(2):109-16.
4. Goh BT, Chanchareonsook N, Tideman H, Teoh SH, Chow JK, Jansen JA. The use of a polycaprolactone-tricalcium phosphate scaffold for bone regeneration of tooth socket facial wall defects and simultaneous immediate dental implant placement in *Macaca fascicularis*. *J Biomed Mater Res A*. 2014;102(5):1379-88.
5. Fairbairn P, Leventis M. Protocol for bone augmentation with simultaneous early implant placement: A retrospective multicenter clinical study. *Int J Dent*. 2015;2015:589135.