



## Dentigerous Cyst Associated with an Ectopically Unerupted Maxillary Third Molar below Infraorbital Region. A Rare Case Report

Priya Gupta\*, Devika Singh, Navin Mishra, A.K Sharma and Sanjay Kumar

Department of Dentistry, IGIMS, India

### Abstract

A Dentigerous cyst or follicular cyst is a form of odontogenic cyst occurring frequently during the development processes of the teeth. It is associated with pressure exerted by the crown of an unerupted (or partially erupted) tooth on the fluid within the follicular space. Typically, dentigerous cysts are painless and discovered during routine radiographic examination. However, they may be large enough resulting in a palpable mass. As they expand, can displace adjacent teeth resulting in gross swelling of the involved region. They almost exclusively occur in permanent dentition. The cyst is lined by stratified squamous non-keratinizing epithelium. About 70% of dentigerous cysts occur in the mandible and 30% in the maxilla. Dentigerous cysts associated with ectopic teeth within the maxillary sinus are very rare. We report radiologic and pathologic features in a rare case of infected dentigerous cyst of maxillary sinus arising from an ectopic third molar in a 20-year-old female patient.

**Keywords:** Dentigerous cyst; ectopic Third molar; Infraorbital margin; Maxillary sinus; Maxilla

### Introduction

Dentigerous cyst is a form of odontogenic cyst. It commonly develops due to accumulation of fluid within the follicular space of an unerupted tooth after its crown has fully formed [1]. It is the second most common odontogenic cyst, next to radicular cyst. The teeth commonly involved are third molars, canines, and second premolars [1,2]. Usually it is symptomless unless it becomes secondarily infected, resulting in a painful swelling. A late non-eruption of tooth could largely indicate the possibility of this cyst. As it grows in size due to increased hydrostatic pressure in the cystic lumen it causes expansion of the concerned region of the jaws resulting in facial asymmetry. As with other cysts, when a Dentigerous cyst expands it can cause pressure induced root resorption of the adjacent teeth [2]. Radiographically, the Dentigerous cysts typically show a unilocular radiolucency with a well-defined sclerotic border associated with the crown of an unerupted tooth, but an infected cyst lacks well defined corticated borders [3]. Dentigerous cysts associated with ectopic teeth within the maxillary sinus are very rare. Hence the present case report highlights the importance of detecting the Dentigerous cyst in otherwise healthy patient with an unerupted third molar.

### Case Presentation

A 20-year-old female patient reported to the department of Dentistry, IGIMS, Patna, with a history of progressive swelling on the right side of the face with discharge of pus from the third molar region her past medical and dental history was unremarkable. There was no history of trauma, pain, paresthesia or lymphadenopathy. There was slight obvious facial asymmetry caused by the swelling over the right maxillary region. The mass was firm and non-tender on palpation and non adherent to the overlying skin. Intra-oral examination showed expansion of the right buccal cortex thus obliterating the buccal vestibule along with absence of the upper right third molar. Provisional diagnosis of impacted maxillary third molar was made. Patient was advised for an x ray orthopantomogram and was put on antibiotics and analgesics and recalled after 5 days. On follow-up x-ray reveals impacted maxillary third molar at infraorbital margin (Figure 1). But extent of lesion was indiscernible; hence CBCT (Figure 2A-C) was advised. Its finding revealed the teeth was seen impacted completely within the maxillary antrum and present inferior to roof of antral wall.

### OPEN ACCESS

#### \*Correspondence:

Priya Gupta, Department of Dentistry,  
IGIMS, India,  
E-mail: Drpriyagupta27@gmail.com

**Received Date:** 20 Dec 2017

**Accepted Date:** 14 Jan 2018

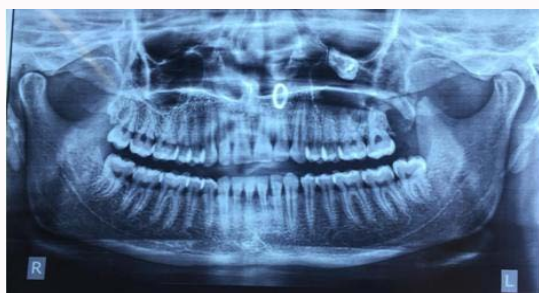**Published Date:** 18 Jan 2018

#### Citation:

Gupta P, Singh D, Mishra N, Sharma  
AK, Kumar S. Dentigerous Cyst  
Associated with an Ectopically  
Unerupted Maxillary Third Molar below  
Infraorbital Region. A Rare Case  
Report. *J Dent Oral Biol.* 2018; 3(2):  
1124.

**ISSN: 2475-5680**

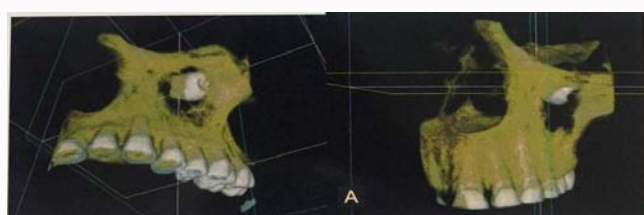
**Copyright** © 2018 Priya Gupta. This is an open access article distributed under the Creative Commons Attribution License, which permits unrestricted use, distribution, and reproduction in any medium, provided the original work is properly cited.



**Figure 1:** OPG revealed unerupted third molar in the right maxillary sinus below the Infra orbital region with cloudy appearance of right maxillary sinus.



**Figure 2A:** The apical end of root of unerupted tooth seems to be impinging on wall of left nasal bone and medial border of left maxillary sinus.



**Figure 2B:** The crown of teeth is positioned slightly distobuccally.

### Radiological feature

A panoramic radiograph showed a well-defined unilocular radiolucency involving the right maxillary sinus along with the impacted third molar on infraorbital margin.

### Pathologic features

Aspiration of the lesion through sinus tract yielded frank pus, which was foul-smelling.

### Histopathological examination

Histopathological examination revealed non-keratinized stratified squamous epithelium confirming the clinical diagnosis of dentigerous cyst. Postoperative panoramic radiograph after 6-months showed a normal maxillary sinus. The patient was followed-up for a year and showed no abnormalities general anesthesia using the Caldwell-Luc approach.

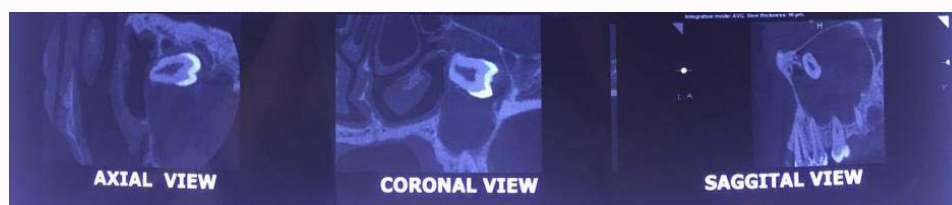
### Diagnosis and treatment plan

Based on the clinical and radiological findings, a diagnosis of

infected dentigerous cyst of maxillary sinus arising from an ectopic third molar was made. The cystic lesion was enucleated under general anesthesia and patient recovery was uneventful.

### Discussion

Ectopic teeth are those located in the jaw bones or regions other than the alveolar arch. Ectopic eruption of maxillary third molar tooth is very rare. However, there have been a few reports of tooth erupting in the nose, mandibular condyle, coronoid process, and maxillary sinus, which is also the largest of the paranasal sinuses [4]. Wisdom teeth are often impacted or in an ectopic position. One rather unusual location is the maxillary sinus. Dentigerous cyst associated with an ectopically unerupted maxillary third molar in Infraorbital region is rare. Usually these teeth are associated with dentigerous cysts, which can occupy the maxillary sinus partially or totally and can be the cause of various symptoms. Usually these teeth are detected during routine radiographic examination or the patient could have a history of typical, sinus-related symptoms [4,5]. Dentigerous cyst is the most common of all follicular cysts, more common in males, occurring in the second or third decade of life. About 70% of Dentigerous cysts occur in the mandible and 30% in the maxilla [5,6]. Teeth most commonly associated with Dentigerous cyst are mandibular third molars, maxillary canines, mandibular premolars, and, very rarely, maxillary third molars. There are three variants of Dentigerous cyst: (a) Central: Crown is enveloped by the follicle symmetrically, (b) Lateral: Dilatation of follicle on one aspect of the crown, and (c) Circumferential: The follicle expands in a manner which envelopes the entire tooth. If infected, the treatment of choice is complete enucleation of the lesion intraoral with removal of the associated tooth. It is also important to completely remove all diseased antral tissues and thoroughly assess all resected soft tissue histologically with proper follow-up for a period of 1 year [6] when the cyst is smaller in size, it is difficult to differentiate a Dentigerous cyst from a large but normal dental follicle. A working definition is that a dentigerous cyst exists when the distance between the crown and dental follicle is greater than 2.5-3.0 mm. The differential diagnosis of a dentigerous cyst includes unicystic ameloblastoma, Adenomatoid Odontogenic Tumor (AOT), early stages of Gorlin Cyst/Calcifying Epithelial Odontogenic Tumor (CEOT), ameloblastic fibroma, ameloblastic fibro-odontoma, and odontogenic keratocyst. Unicystic ameloblastoma occurs in people under the age of 30 years, is seen equally in both genders, and has a tendency to occur in the posterior mandible associated with the crown of an unerupted third molar [7]. AOT is common in the 2<sup>nd</sup> decade, affects females twice as often as males, and has a tendency to occur in the anterior maxilla and, in about 74% of cases, is associated with the crown of an unerupted canine and supernumerary teeth. However, AOT of the maxillary antrum is extremely rare. Gorlin cyst is commonly found in the incisor and canine area in about 65% of cases. Approximately one-third of cases are associated with an unerupted tooth, most often a canine. CEOT is an uncommon lesion, which is most often encountered between



**Figure 2C:** Axial coronal and saggital view showing impacted maxillary third molar at infraorbital margin.

3<sup>rd</sup> and 5<sup>th</sup> decades, occurs equally in both genders, and has a tendency to occur in posterior mandible associated with an impacted third molar. Ameloblastic fibroma is an uncommon tumor, occurs in the first 2 decades, more common in males, commonly found in posterior mandible, and is associated with an unerupted tooth in about 75% of cases. Ameloblastic fibro-odontoma often occurs in the maxilla and is associated with an impacted tooth. However, the ameloblastic fibro-odontoma is rarely found within the maxillary sinus and usually occurs in young adults under the age of 20 years. Odontogenic keratocyst may be found in patients in any age group, is commonly found in posterior body and ascending ramus of the mandible, and in 25-40% of cases, an unerupted tooth is involved [7]. Histologically, dentigerous cysts are lined by a layer of non-keratinized stratified squamous epithelium, with a surrounding wall of thin connective tissue containing odontogenic epithelial rests. Cases of ameloblastoma or epidermoid carcinomas developing from the lining epithelium of a dentigerous cyst are adequately documented as potential long-term complications, whereas mucoepidermoid carcinomas are less well-documented [8]. The standard treatment for a dentigerous cyst of maxilla is enucleation and extraction of the associated tooth via a Caldwell-Luc procedure under local or general anesthesia. In large cysts, an initial marsupialization to diminish the size of the osseous defect, followed by enucleation and tooth extraction, has been followed. The major disadvantage of marsupialization is recurrence or persistence of the lesion along with the residual cystic lining. Endoscopic approach for management of dentigerous cyst of maxilla is also described in the literature. This method is associated with lesser operative as well as postoperative morbidity [9]. Dentigerous cyst of maxilla may cause pathological jaw fracture if large enough, may transform into ameloblastoma, and has the potential of developing into squamous cell carcinoma and mucoepidermoid carcinoma if there is chronic infection. It has a recurrence rate of about 12-14% [8].

## Conclusion

Early diagnosis and treatment of odontogenic cyst lesions is very important to prevent morbidity. Imaging studies including CT scans aid in diagnosis of dentigerous cysts and associated tooth

abnormalities. Knowledge of histopathologic features helps confirm the diagnosis. Management of Dentigerous cyst arising from ectopic third molar in the maxillary sinus is usually enucleation. If left untreated, it has a tendency to transform into a tumor. Caldwell-Luc procedure along with enucleation and primary closure was followed in this case as the ectopic tooth was the cause of recurrent sinusitis and purulent rhinorrhea in spite of administering antibiotics repeatedly.

## References

1. Szerlip L. Displaced third molar with dentigerous cyst--an unusual case. *J Oral Surg.* 1978;36(7):551-2.
2. Elango S, Palaniappan SP. Ectopic tooth in the roof of the maxillary sinus. *Ear Nose Throat J.* 1991;70(6):365-6.
3. Goh YH. Ectopic eruption of maxillary molar tooth-an unusual cause of recurrent sinusitis. *Singapore Med J.* 2001;42(2):80-1.
4. Amin ZA, Amran M, Khairudin. Removal of extensive maxillary dentigerous cyst via a Caldwell-Luc procedure. *Arch Orolfac Sci.* 2008;3(2):48-51.
5. Srinivasa Prasad T, Sujatha G, Niazi TM, Rajesh P. Dentigerous cyst associated with an ectopic third molar in the maxillary sinus: A rare entity. *Indian J Dent Res.* 2007;18(3):141-3.
6. Wang Chih-Jen, Huang Po-Hsien, Wang Yin-Lai, Shyng Yih-Chung, Kao Wen-Bin. Dentigerous cyst over maxillary sinus: A case report and literature review. *Taiwan J Maxillofac Surg.* 2009;20:116-24.
7. Mahesh KR, Umashankar DN, Nandakumar H, Radhika BM, Sudhaka R. Inflammatory variant of dentigerous cyst in maxillary sinus--A case report. *Int J Oral Maxillofac Pathol.* 2010;1:17-9.
8. Mohan S, Kankariya H, Harjani B, Sharma H. Ectopic third molar in the maxillary sinus. *Natl J Maxillofac Surg.* 2011;2(2):222-4.
9. Yasuoka T, Yonemoto K, Kato Y, Tatematsu N. Squamous cell carcinoma arising in a dentigerous cyst. *J Oral Maxillofac Surg.* 2000;58(8):900-5.