



Dental Stem Cell Banking, The Future is Here: A Case Report

Abhishek Singh Nayyar^{1*}, Hetal Turakhia² and Shravan Chawla³

¹Department of Oral Medicine and Radiology, Saraswati Dhanwantari Dental College and Hospital and Post-Graduate Research Institute, India

²Department of Prosthodontics and Crown and Bridge, Saraswati-Dhanwantri Dental College and Hospital and Post-Graduate Research Institute, India

³Department of Oral Medicine, Beyond Smiles Dental Care Pvt Ltd, India

Abstract

The world over the entire educated population is well aware of the various possibilities of stem cell science and research, an endless possibility to repair and regenerate tissues in our body. Stem cell therapy has a promising future for tissue regenerative medicine. However, because stem cell technology is still in its infancy, interdisciplinary cooperation is needed to achieve successful clinical applications. Dental stem cells have drawn attention in recent years because of their accessibility, plasticity, and high proliferative ability. Several types of dental stem cells have been identified, including dental pulp stem cells from adult human dental pulp, stem cells from human primary exfoliated deciduous teeth, periodontal ligament stem cells, and dental follicle stem cells from human third molars. The concept of Dental Stem Cell Banking is gaining popularity in view of its affordability, ease of extractions, awareness amongst the patients and parents in case of child patients to safeguard their children health and the emphasis in modern medical research towards therapies from regenerative tissues.

Keywords: Stem cell science and research; Dental stem cell banking

Introduction

The world over the entire educated population is well aware of the various possibilities of stem cell science and research, an endless possibility to repair and regenerate tissues in our body. Stem cells are specialized cells that have the remarkable potential to develop into many different cell types in the body during early life and growth. In addition, in many tissues, they serve as a sort of internal repair system dividing essentially without limit to replenish other cells as long as the person is still alive [1]. It is for this very reason that the West has put its full weight behind stem cell research with government funded research projects and legally approving new treatment avenues. Fortunately, we are not too far behind. We got an opportunity to do a case in association with STEMAD, an International Dental Stem Cell Banking Company, which is based in India, using the autologous stem cell therapy wherein a patient is treated using his own stem cells. These autologous cells are multipotent stem cells, so they can create varied tissues unlike umbilical cord stem cells which are used to treat only blood cell-related disorders. The focus, today, is on your way to banking yours and your child's dental stem cell harvest for the future.

Case selection

An appropriate case selection is the main key for high success rate for stem cell harvests. STEMAD, an International Dental Stem Cell Banking Company, in association with Beyond Smiles Dental Care Pvt. Ltd., Mumbai, Maharashtra, India, are amongst the pioneers in advocating planned extractions for the purpose of Dental Stem Cell Banking. However, this procedure requires a thorough understanding of the case selection, planned atraumatic extractions, thorough asepsis and biological material's packaging protocols to achieve an optimal stem cell harvest success rate. Children between the age group of 6 years to 10 years are usually considered ideal candidates for such procedures. In adults, third molars can be considered for the harvest of stem cells. The tooth being considered for extraction must be caries free, periodontally sound and endodontically vital. Deciduous teeth must not have undergone more than 1/3rd of root resorption. Planned extractions of deciduous teeth due to erratic eruption pattern of permanent teeth, teeth extracted to avoid crowding, or teeth extracted under interceptive orthodontics are ideal candidates for stem cell

OPEN ACCESS

*Correspondence:

Abhishek Singh Nayyar, Department of Oral Medicine and Radiology, Saraswati Dhanwantari Dental College and Hospital and Post-Graduate Research Institute, Parbhani, Maharashtra, India, Tel: 917350990780; E-mail: singhabhishek.rims@gmail.com

Received Date: 19 Sep 2016

Accepted Date: 24 Oct 2016

Published Date: 10 Nov 2016

Citation:

Nayyar AS, Turakhia H, Chawla S. Dental Stem Cell Banking, The Future is Here: A Case Report. *J Dent Oral Biol.* 2016; 1(3): 1011.

Copyright © 2016 Nayyar AS. This is an open access article distributed under the Creative Commons Attribution License, which permits unrestricted use, distribution, and reproduction in any medium, provided the original work is properly cited.

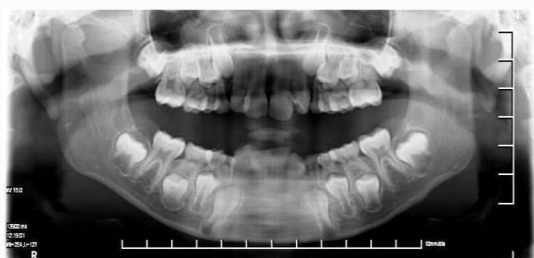

Figure 1: Pre-operative Orthopantomograph (OPG) of the patient.

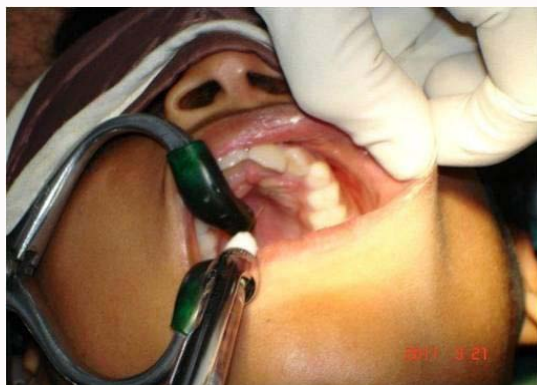

Figure 2: Administration of local anesthesia.

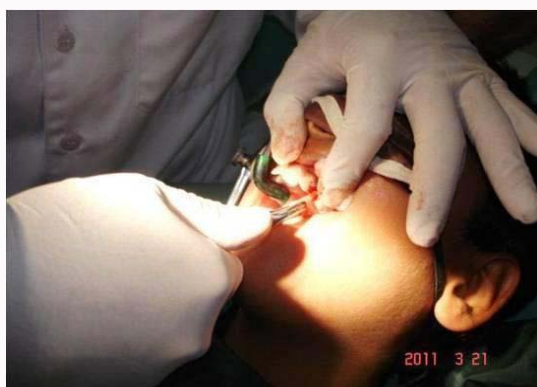

Figure 3: Atraumatic extraction being carried-out in the patient.

harvests. Sectioned teeth during surgery, teeth with root fractures, etc., on the other hand, are not acceptable. Discolored teeth suggestive of pulpal degeneration, also, get excluded. In the presented case, two teeth underwent planned extractions, both were sent at the same time for stem cell harvest, thereby, increasing the success rate.

Case Presentation

A 10 year old boy reported to our dental set-up with parents having a keen interest in banking his stem cells as the boy had an auditory problem supplemented with a cochlear implant. On clinical and radiographic examination, it was found that the boy had upper and lower anterior crowding due to erratic eruption pattern and timing of permanent dentition with poor oral hygiene but no dental caries. After thoroughly examining the orthopantomograph (OPG) (Figure 1) of the patient in addition to the relevant intra-oral periapical radiographs (IOPARs), it was decided to extract all deciduous canines to aid in the anterior space decompression and eruption of the permanent canines. These teeth were, also, considered, keeping

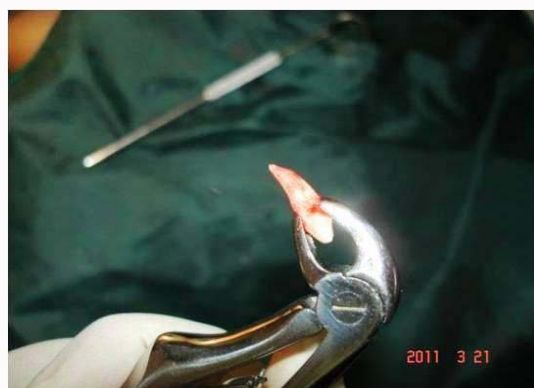

Figure 4: Extracted tooth without any gross damage to the crown or root structure.



Figure 5: Extracted tooth placed in storage medium in a special preservation vial.

in mind, the stem cell harvest as they had underwent less than 1/3rd of root resorption.

Surgical phase

Prior to the extraction, all necessary procedures including oral prophylaxis and restorative procedures were completed. Also, the STEMADE Team had sent a Pathologist for collection of the blood samples of the patient before the extraction procedure. The patient was made to rinse his mouth with 2% chlorhexidine mouth rinse twice. The teeth to be extracted were sprayed with topical anesthetic spray (Lidocaine hydrochloride 2% with adrenaline 1:80,000) along with topical anesthesia jelly applied to the teeth as well as their investing tissues. Following topical soft tissue anesthesia, local infiltration injection (Figure 2) was given in the labial vestibule (Lidocaine hydrochloride 4% with adrenaline 1:1,00,000, 1.8 ml cartridge) and the adequacy of anesthesia was tested with objective and subjective signs and symptoms to the patient. The soft tissue attachment was loosened around each tooth with the help of a Moon's probe/periosteal elevator making sure not to damage the tooth keeping in mind to carry-out the extraction as a traumatically as possible. On soft tissue reflection, a straight elevator was used with a very gentle pressure in an apical direction in wiggling motion, thereby, slowly luxating the tooth in a coronal direction. Once the tooth was sufficiently loosened, a force p was used in a rotatory motion to remove the tooth. (Figure 3) Once the tooth was out of the alveolar socket (Figure 4), it was made sure that it did not touch the inside of the oral cavity, or, any other surface and was immediately placed in the special vial (Figure 5) provided




Figure 6: Tooth and blood sample packed to be sent to the lab for cell harvest.

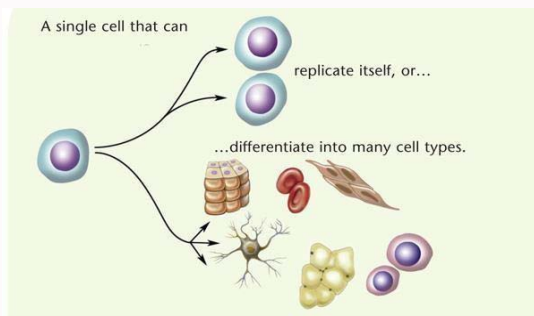


Image prepared by Catherine Twomey for the National Academies, *Understanding Stem Cells: An Overview of the Science and Issues from the National Academies*, www.nationalacademies.org/stemcells.

Figure 7: stem cell differentiation.

Dental Stem Cells

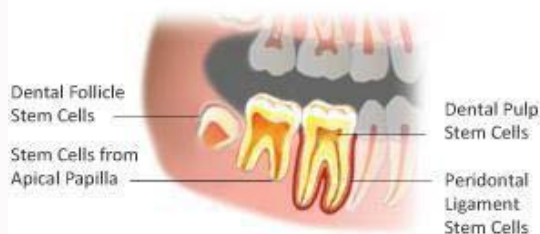

Figure 8: Dental stem cells.

by STEMADE which was, then, placed in a frozen gel pack. All the teeth were delivered one by one with similar technique making sure not to damage the tooth/root during the extraction procedure. The gel packs in thermo-insulated box were packed (Figure 6) and sent immediately to the laboratory for stem cell harvest. Post-operative compression and hemostasis was achieved at each surgical site and post-operative instructions were given to the patient and his parents.

Laboratory phase

Once in the lab, it required 15-30 days to process the tissue and harvest the mesenchymal cells from the dental pulp. Once successfully harvested, these cells were banked. Our centre was informed and a certificate for the parents was sent across mentioning the years for which it was banked with identification number for future reference.

Discussion

Stem cells (SCs) are undifferentiated cells capable of self-renewal and differentiation into multiple functional cell types. These cells are

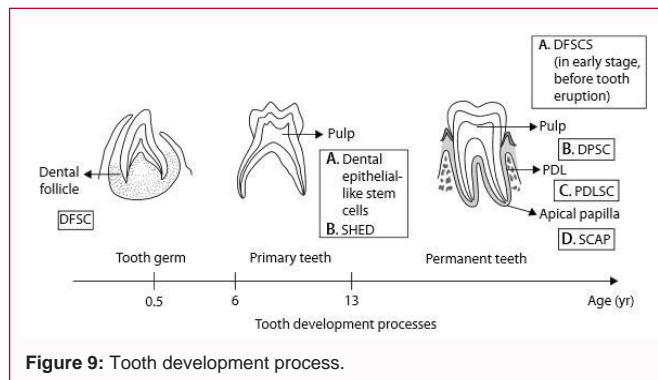


Figure 9: Tooth development process.

widely used in injury, repair and tissue regeneration. They have the remarkable potential to develop into many different cell types in the body during early life and growth. In addition, in many tissues, they serve as a sort of internal repair system dividing essentially without limit to replenish other cells as long as the person is still alive [2]. When a stem cell divides, each new cell has the potential either to remain a stem cell or, to become another type of cell with a more specialized function such as a muscle cell, red blood cell or, a brain cell. Stem cells are distinguished from other cell types by two important characteristics. First, they are unspecialized cells capable of renewing themselves through cell division, sometimes, after long periods of inactivity. Second, under certain physiological or, experimental conditions, they can be induced to become tissue-or, organ-specific cells with more specialized functions [3,4] (Figure 7).

There are two principal types of stem cells [5]: 1) Embryonic Stem Cells; and 2) Adult Stem Cells [Hematopoietic Stem Cells (HSCs)/ Mesenchymal Stem Cells (MSCs)].

Embryonic stem cells

Embryonic stem cells can be differentiated into any other cell in the human body. They are currently not being used in humans for treatment; yet, they are potential avenues in the research arena. These cells are very primitive in that they have not begun to take on any specific cell function and are derived from an unborn fetus.

Adult stem cells

Hematopoietic Stem Cells (HSCs): These stem cells give rise to all types of blood cells. They are primarily used to regenerate the hematopoietic tissues compromised by a disease process and are found in abundance within the hematopoietic tissues, especially, within the cord blood [6].

Mesenchymal Stem Cells (MSCs): These stem cells have the unique ability to differentiate into many types of tissues in the body including bone, heart, cartilage, and adipose and/or, neuronal tissues. They are an essential component for regenerative medicine and are found principally in dental pulp as well as numerous other tissues in the body [7]. Dental pulp contains pluripotent stem cells. If extracted in their vital state, these cells can be made to divide and preserved to be used at a later stage to repair and regenerate cells and tissues, and may be, even, to reverse numerous degenerative disorders. Scientists have identified these cells as the adult Mesenchymal Stem Cells (MSCs) inside the dental pulp. These cells are found in the pulpal tissues of both the deciduous as well as the permanent teeth, especially, the third molars [8]. This particular type of stem cells has the future potential to differentiate into a variety of other cell types including the [9]: Cardiomyocytes to repair the damaged cardiac

tissues following a heart attack; Neuronal cells to regenerate the neuronal tissues following a degenerative disorder;

Myocytes to repair muscles; Osteocytes to regenerate the bone; Chondrocytes to regenerate the cartilage; and

Adipocytes to regenerate the adipose tissue.

Dental stem cells have been found in several tissues and can be divided into dental mesenchymal stem cells and dental epithelial-like stem cells. Mesenchymal stem cells from human dental tissues include dental pulp stem cells (DPSCs) in human permanent teeth, stem cells from human exfoliated deciduous teeth (SHEDs), periodontal ligament stem cells (PDLSCs), and dental follicle stem cells (DFSCs) and stem cells from apical papilla (SCAP) from human third molars. Dental epithelial stem cells have, also, been found in continuously growing incisors in mice and in molars from various other mammalian species [10] (Figure 8 and 9).

Conclusion

The concept of Dental Stem Cell Banking is gaining popularity in view of its affordability, ease of extractions, awareness amongst the patients and parents in case of child patients to safeguard their children health and the emphasis in modern medical research towards therapies from regenerative tissues. Stem cell research is, here, to stay and the rate, at which clinical trials are being conducted and some clinical cases have achieved success, suggests dental stem cell banking is a sure shot way to harvest viable stem cells, given a thorough planning, and for those, who have missed the bus to bank the cord stem cells.

References

1. Cordeiro MM, Dong Z, Kaneko T, Zhang Z, Miyazawa M, Shi S, et al. Dental pulp tissue engineering with stem cells from exfoliated deciduous teeth. *J Endod.* 2008; 34: 962-969.
2. Weissman IL. Stem cells: Units of development, units of regeneration, and units in evolution. *Cell.* 2000; 100: 157-168.
3. Lovell-Badge R. The future for stem cell research. *Nature.* 2001; 414: 88-91.
4. Hemmat S, Lieberman DM, Most SP. An introduction to stem cell biology. *Facial Plast Surg.* 2010; 26: 343-349.
5. Bianco P, Robey PG, Simmons PJ. Mesenchymal stem cells: Revisiting history, concepts, and assays. *Cell Stem Cell.* 2008; 2: 313-319.
6. Arien-Zakay H, Lazarovici P, Nagler A. Tissue regeneration potential in human umbilical cord blood. *Best Pract Res Clin Haematol.* 2010; 23: 291-303.
7. Meirelles Lda S, Nardi NB. Methodology, biology and clinical applications of mesenchymal stem cells. *Front Biosci.* 2009; 14: 4281-4298.
8. Gronthos S, Mankani M, Brahimi J, Robey PG, Shi S. Post-natal human dental pulp stem cells (DPSCs) in-vitro and in-vivo. *Proc Natl Acad Sci USA.* 2000; 97: 13625-13630.
9. Gronthos S, Brahimi J, Li W, Fisher LW, Cherman N, Boyde A, et al. Stem cell properties of human dental pulp stem cells. *J Dent Res.* 2002; 81: 531-535.
10. Yen-Hua Huang, Jen-Chang Yang, Chin-Wei Wang, Sheng-Yang Lee. Dental Stem Cells and Tooth Banking for Regenerative Medicine. *J Exp Clin Med.* 2010; 2: 111-117.