



# Cranial Fasciitis of Childhood with Underlying Solid Aneurysmal Bone Cyst of Temporal Bone

Jassar A\*, Kumar VK and Kumar A

Departments of Pathology & Neurosurgery, Command Hospital, India

## Abstract

Cranial fasciitis is a rare variant of pseudosarcomatous fibroblastic/myofibroblastic proliferation, seen almost exclusively in children. Most cases are idiopathic, though in some a history of trauma has been elucidated. Cases of suspected cranial fasciitis must be worked up radiologically to rule out intracranial extension. We present a case of cranial fasciitis in a ten-year old girl that showed involvement of temporal bone radiologically and subsequently turned out to be a solid aneurysmal bone cyst of the temporal bone on biopsy. It is likely that extralesional stromal hemorrhages from the cyst incited a reactive fibroblastic response in the form of cranial fasciitis in this case.

**Keywords:** Cranial fasciitis of childhood; Solid variant of aneurysmal bone cyst; Temporal bone

## Introduction

Cranial fasciitis, a variant of nodular fasciitis, is a benign fibroblastic tumor of the skull, found almost exclusively in the scalp of young children. It was first described as a specific entity by Lauer and Enzinger [1] in 1980 and since then about 40 cases have been described in world literature. Cranial fasciitis is now considered a benign lesion of likely myofibroblastic origin but uncertain etiopathogenesis, though some authors have found an association with previous local trauma [2]. A case of cranial fasciitis in a ten-year-old girl who had an underlying solid aneurysmal bone cyst of temporal bone is presented here. The authors hypothesize that the cranial fasciitis in this child was a reactive response to extralesional stromal hemorrhages from the aneurysmal bone cyst. To the best of the authors' knowledge, this is the first such report in world literature.

## Case Presentation

A ten-year old girl presented with two months' history of a spontaneous, rapidly-growing painless swelling over the left temporal region of the scalp. There was no history of fever, vomiting, seizures or local trauma. On examination, a firm non-tender subcutaneous swelling (measuring approximately 6.5 cm × 4.5 cm) was seen over the left temporo-zygomatic area (Figure 1). The swelling had ill-defined edges and was fixed to underlying tissues. An initial biopsy of the mass revealed a polymorphous population of mature lymphocytes and giant 'ganglion cell-like' cells with multiple nuclei & prominent nucleoli in a myxoid background with foci of hemorrhage and hyalinization (Figure 2). Mitotic figures were 1-2 per HPF. However there was no necrosis, atypia or abnormal mitoses. A diagnosis of cranial fasciitis was offered.

On radiological work-up, there was a lytic skull lesion with destruction of both the inner and outer tables of left temporal bone. Computed Tomography (CT) scan head showed a tumor (69.4

## OPEN ACCESS

### \*Correspondence:

Jassar A, Departments of Pathology & Neurosurgery, Command Hospital, Jalandhar, Punjab, India, Tel: 09926522295;

E-mail: aneetajassar@gmail.com

Received Date: 19 Apr 2017

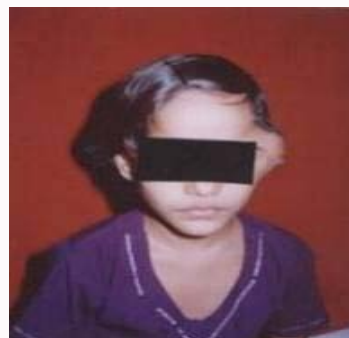Accepted Date: 30 May 2017

Published Date: 06 Jun 2017

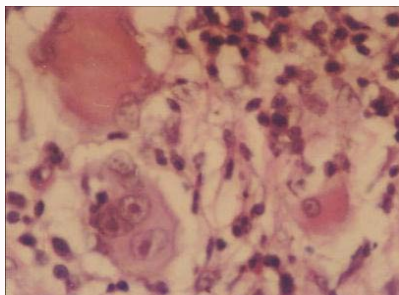
### Citation:

Jassar A, Kumar VK, Kumar A. Cranial Fasciitis of Childhood with Underlying Solid Aneurysmal Bone Cyst of Temporal Bone. *Ann Infect Dis Epidemiol.* 2017; 2(2): 1017.

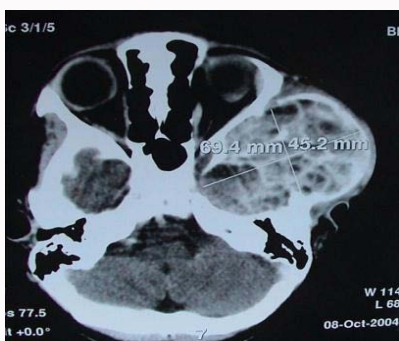
Copyright © 2017 Jassar A. This is an open access article distributed under the Creative Commons Attribution License, which permits unrestricted use, distribution, and reproduction in any medium, provided the original work is properly cited.



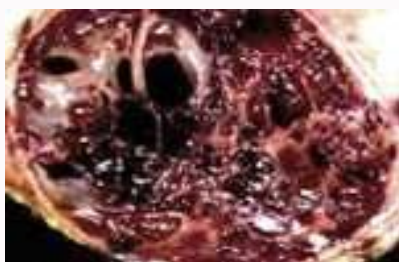**Figure 1:** Ten-year old with a painless, rapidly growing subcutaneous swelling over temporal region.



**Figure 2:** Biopsy of the swelling showed features of cranial fasciitis (haphazard arrangement of plump fibroblasts in a myxoid background and interspersed with inflammatory cells and RBCs) (H&E, 400X).



**Figure 3:** CT scan showing a solid-cystic lesion in temporal bone with bony destruction and intracranial extension.



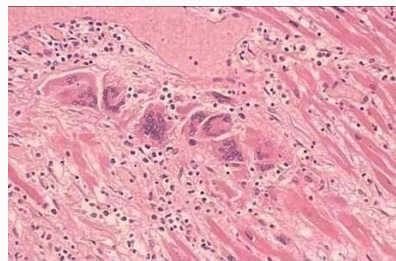
**Figure 4:** Gross appearance of the excised specimen showing a highly vascular appearance.

mm × 45.2 mm) in left temporal bone with intracranial extension and partial destruction of the greater wing of sphenoid bone (Figure 3). The tumor had destroyed the calvarial bone as well as part of the zygoma. The dura was pushed but not infiltrated and there was no midline shift. Per-operatively there was a large firm tumor of high vascularity. Cut section had a gritty feel and a ‘honey-combed’ appearance with few blood-filled spaces (Figure 4).

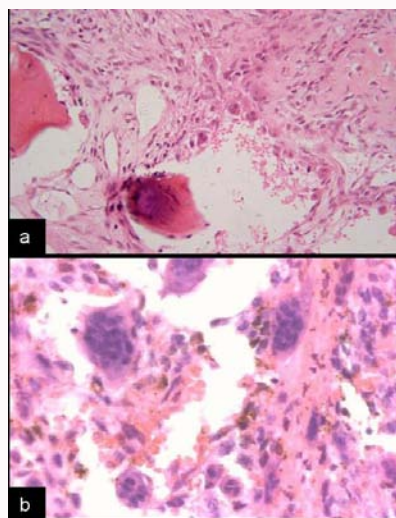
Histopathological examination of the excised mass showed features of cranial fasciitis in the superficial part (Figure 5) and a cellular lesion with florid fibroblastic proliferation, osteoclast-like giant cells, stromal hemorrhage, fragments of reactive bone and occasional angiectoid cavernous spaces without endothelial lining in the deeper part (Figure 6). The final histopathological diagnosis was cranial fasciitis of childhood with underlying solid aneurysmal bone cyst of temporal bone.

**Discussion**

Fasciitis of various types constitute a distinct category of soft



**Figure 5:** Plump multinucleated fibroblasts in a background of chronic inflammatory cells (H&E, 100X).



**Figure 6:** a) Predominantly solid tumor with few angiectoid spaces lacking an endothelial lining (H&E, 40X) and b) Cellular fibrous septae with fibroblasts and numerous giant cells (H&E, 100X).

tissue lesions which can closely mimic sarcomas clinically and even microscopically. Nodular fasciitis is the archetype of this group of ‘pseudosarcomatous’ lesions and cranial fasciitis is considered its unusual variant [3]. Cranial fasciitis of childhood, as described by Lauer and Enzinger [1], is a rare fibroblastic lesion occurring superficial to, or involving the cranial bones of children at a median age of 18 months, with a male predilection of 2:1. Clinically it presents as a rapidly growing, usually painless mass with an average pre-operative duration of two months [4]. Our case had a typical presentation.

Histologically, cranial fasciitis is described as a well-circumscribed, loose proliferation of stellate to spindle-shaped fibroblasts in a myxoid background with foci of hemorrhage and hyalinization. Mitotic figures, increased cellularity and cellular immaturity may be seen [4]. Immunohistochemically, the spindle cells show a strong positivity for smooth muscle actin. The exact etiopathogenesis of cranial fasciitis is poorly understood, though ultrastructural features suggest a myofibroblastic origin [4]. Okuyama et al. [2] investigated the relationship between head trauma and cranial fasciitis and found history of trauma in only 20% of the cases. The etiology of the remaining cases remains speculative. Our case gave no history of local trauma.

Some authors [5] have described cases of cranial fasciitis with destruction of calvarium and intracranial extension. The dura is usually pushed but not infiltrated. Our case also had an intracranial

extension of the lesion without dural infiltration. However, in this case the intracranial lesion turned out to be an aneurysmal bone cyst of the temporal bone on histology.

Aneurysmal bone cyst (ABC) is an uncommon, rapidly expanding, locally destructive lytic bone lesion, accounting for 1% to 2% of primary biopsied bone tumors. It may be conventional (95%) or solid (5%) [6]. Of the 200 cases of ABC in the Rizzoli institute files, only 15 had solid features on both gross and histological examination. Cranial bones are an unusual site for ABC and account for only 7% of all cases. Solid variant of ABC is not only rare but also difficult to recognize radiologically before biopsy or surgery [7]. Histologically it is characterized by florid fibroblastic proliferation, osteoclast-type giant cells, foci of reactive osteoid formation and only occasional or no aneurysmal sinusoids, lacking an endothelial lining [8]. Pathogenesis of ABC is not very clear, but according to some researchers it may be a congenital lesion of intraosseous blood vessel walls or may develop following trauma. Variant translocations involving 16q22 and 17p13 have been reported in solid variant and extraosseous forms of aneurysmal bone cyst [9].

In the case presented, superficial biopsy had shown features of cranial fasciitis. Radiologically, there was destruction of bone, intracranial extension and pushing of dura. The radiological diagnosis was cranial fasciitis with intracranial extension. Both cranial fasciitis and aneurysmal bone cyst can show overlapping radiological features like radiolucent, lytic lesion on X-ray, expansile osteolytic mass of mixed density on CT scan and erosion of bone. Characteristic fluid-fluid levels may be absent especially in the solid variant of aneurysmal bone cyst. Peroperatively, the mass was found to be highly vascular with occasional cystic blood-filled spaces. Gross and histopathological examination showed a solid variant of aneurysmal bone cyst with features of cranial fasciitis in the superficial part. The authors hypothesize that extralesional stromal hemorrhage from the microcysts of solid aneurysmal bone cyst probably induced a reactive fibroblastic/myofibroblastic response in the form of cranial fasciitis in this case.

Thus cases of cranial fasciitis must be thoroughly worked up and correlated on radiology, in order to rule out intracranial extension

or other underlying pathology. Complete surgical removal is the treatment of choice for an ABC and is curative [10]. It has been noted that recurrence of ABC of the calvaria is rare, unlike ABCs in other locations. This child underwent wide excision of tumor and repair of the bone defect by a graft. She has had no recurrence or neurological deficit during the two years of follow up.

## References

1. Lauer DH, Enzinger FM. Cranial fasciitis of childhood. *Cancer*. 1980;45(2):401-6.
2. Okuyama S, Kayama T, Sonoda Y, Sato S, Nakazato Y. A case of cranial fasciitis induced by trauma. *No To Shinkei*. 2003;55(4):361-5.
3. Samaratunga H, Searle J, O'Loughlin B. Nodular fasciitis and related pseudosarcomatous lesions of soft tissues. *Aust N Z J Surg*. 1996;66(1):22-5.
4. Sarangarajan R, Dehner LP. Cranial and extracranial fasciitis of childhood: a clinicopathologic and immunohistochemical study. *Human Pathol*. 1999;30(1):87-92.
5. Sayama T, Morioka T, Baba T, Ikesaki K, Fukui M. Cranial fasciitis with massive intracranial extension. *Childs Nerv Syst*. 1995;11(4):242-5.
6. Chidambaram B, Santosh V, Balasubramaniam V. Aneurysmal bone cyst of the temporal bone. *Childs Nerv Syst*. 2001;17(7):411-4.
7. Bertoni F, Bacchini P, Capanna R, Ruggieri P, Biagini R, Ferruzzi A, et al. Solid variant of aneurysmal bone cyst. *Cancer*. 1993;71(3):729-34.
8. Sanerkin NG, Mott MG, Roylance J. An unusual intraosseous lesion with fibroblastic, osteoclastic, osteoblastic, aneurysmal and fibromyxoid elements. "Solid" variant of aneurysmal bone cyst. *Cancer*. 1983;51(12):2278-86.
9. Dal Cin P, Kozakewich HP, Goumnerova L, Mankin HJ, Rosenberg AE, Fletcher JA. Variant translocations involving 16q22 and 17p13 in solid variant and extraosseous forms of aneurysmal bone cyst. *Genes Chromosomes Cancer*. 2000;2013:233-4.
10. Ansari S, Ahmad K, Gupta MK, Rauniyar RK. Aneurysmal bone cyst of temporal bone. *BMJ Case Rep*. 2013;2013:bcr2013009434.