



# Correction of Pectus Excavatum Anterior Chest Wall Deformity Using Custom Made Silicone Implant

De Baerdemaeker RA\*, Hendrickx B, Geeroms M, Zeltzer AA and Hamdi M

Department of Plastic and Reconstructive Surgery, University Hospital Brussels, Belgium

## Abstract

Pectus excavatum is the most common deformity of the chest wall. Most adult patients with pectus excavatum have no functional complaints. Silicone implants offer a minimally invasive solution to correct the chest wall deficit in adolescents beyond their growth spurt and adults with significant deformity. We present the cases of 3 male patients with pectus excavatum chest wall deformity without physiologic compromise. Their wish was to correct the deformity in a less invasive manner compared to other surgical techniques but with stable results.

A personalized custom made implant was manufactured based on three-dimensional reconstructions derived from a computed tomography scan. Unlike with classic methods, the implant was designed to fill the defect resulting from the deformity of the bony structures. This is superior to the previous implants created from molds based on the appearance of the anterior chest wall deformity on the skin, since the implant fits more accurately in the thoracic deficit. The subpectoral placement of the implant is a relatively minor surgical procedure under general anesthesia with short hospital stay and minimal morbidity. Except for two cases with small seroma formation, no complications occurred and patient satisfaction was very high.

**Keywords:** Pectus excavatum; Custom made implant; Computer aided design; Thoracic reconstruction; Silicone implant

## OPEN ACCESS

### \*Correspondence:

R De Baerdemaeker, Department of Plastic and Reconstructive Surgery, University Hospital Brussels, Vrije Universiteit Brussel (VUB), Laarbeeklaan 101, 1090 Brussels, Belgium,  
E-mail: randy.debaerdemaeker@uzbrussel.be

**Received Date:** 08 Nov 2018

**Accepted Date:** 14 Jan 2019

**Published Date:** 17 Jan 2019

### Citation:

De Baerdemaeker RA, Hendrickx B, Geeroms M, Zeltzer AA, Hamdi M. Correction of Pectus Excavatum Anterior Chest Wall Deformity Using Custom Made Silicone Implant. *Ann Plast Reconstr Surg.* 2019; 2(3): 1021.

**Copyright** © 2019 De Baerdemaeker RA. This is an open access article distributed under the Creative Commons Attribution License, which permits unrestricted use, distribution, and reproduction in any medium, provided the original work is properly cited.

## Introduction

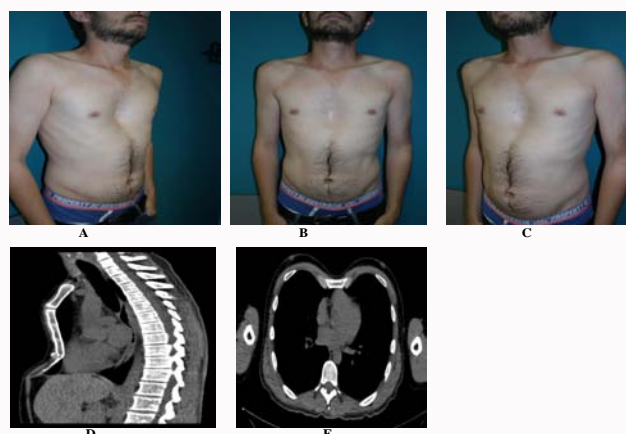
Pectus excavatum is the most common deformity of the chest wall marked by a sharp posterior curve of the sternum sweeping down from the manubrium, generally deepest just before its junction with the xyphoid. The lower costal cartilage bends to form a depression. Most cases are sporadic although there are patients with a positive family history. The deformity has a high incidence of association with Marfan's syndrome. Males are affected more commonly than females (4:1) [1-3]. Etiology is controversial but probably secondary to an overgrowth of the costal cartilages. The deformity is present at birth and progresses as the child grows. Associated deformities include a broad thin chest, anterior drooping of the shoulders, protuberant abdomen, hypomastia, dorsal kyphosis and scoliosis. The majority of patients with pectus excavatum have no cardiovascular or pulmonary complaints [2-4].

## Patient's selection

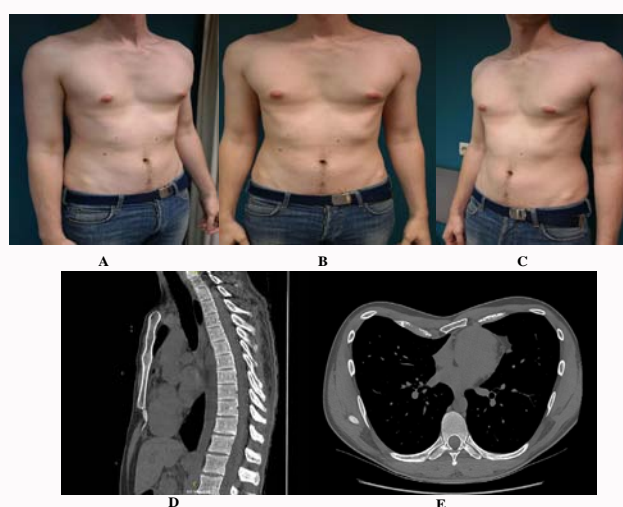
Three patients who came to our outpatient clinic in the Brussels University Hospital, and who desired a less invasive solution compared to other surgical techniques as the Ravitch sternochondroplasty [5], the Nuss procedure or the free sternal turn-over technique [6,7], were selected for inclusion in our study.

The first case was a 35-year old male (BMI 19.6 kg/m<sup>2</sup>) without medical history, except for gastric ulcerations, who presented at our office with the desire to correct his pectus excavatum anterior chest wall deformity (Figure 1). He was an active smoker but decreased his daily amount of smoked cigarettes significantly prior to surgery. The patient had some self-conscious apprehension to uncover his chest and wished to have a stable result after a correction in a minimally invasive manner. The deformity was too large to be corrected with fat grafting only, especially because the patient did not have abundantly available donor adipose tissue.

The second patient was a 25-year old man with a BMI of 21.4 kg/m<sup>2</sup> without medical history or tobacco use. He presented an asymmetric pectus excavatum with distinct costosternal angulation on the right side (Figure 2).



**Figure 1:** Patient #1. Figure A-C: Preoperative. Figure D&E: Sagittal and transverse CT images confirming the symmetrical anterior chest wall depression.



**Figure 2:** Patient #2. Figure A-C: Preoperative pictures. Figure D&E: Sagittal and transverse CT images demonstrating the asymmetrical pectus excavatum with right costosternal angulation.

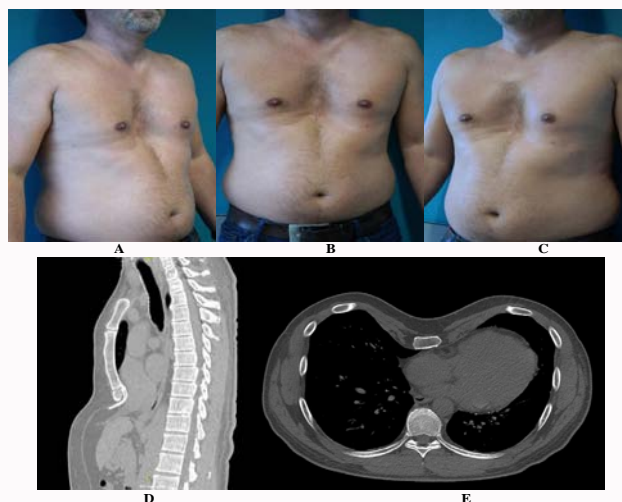
The third patient was a 46-year old man with BMI of 25.9 kg/m<sup>2</sup> who did not smoke and had no medical history except for rhinitis. Computed Tomographic (CT) imaging confirmed his pectus excavatum with a secondary minimal deviation of the heart (Figure 3). All three patients had a purely aesthetic concern and did not have any functional complaints. Placement of a Nuss Bar and Ravitch-type repair were briefly discussed with each patient and subsequently refused by the patients.

## Methods

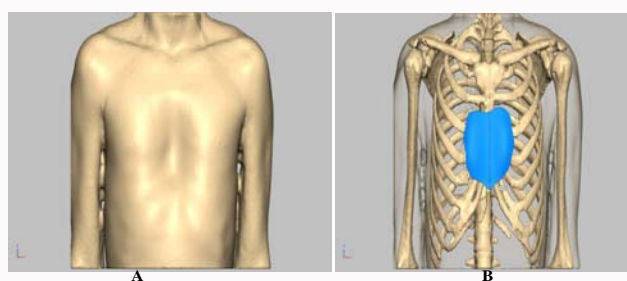
A (Computed Tomographic) CT scan of the thorax with adducted arms was performed for each patient (Figure 1D&1E, Figure 2D&2E, Figure 3D&3E). A personalized custom-made implant was manufactured by a specialized company (Anatomik Modeling, Toulouse, France; and Sebbin, Boissy-l'Aillerie, France) based on the three-dimensional reconstructions (Figure 4). The semi-solid silicone (NuSil MED-4805, Carpinteria, California, USA) implant was designed to fill up the defect resulting from the deformity of the bony structures (Figure 5). The cost for the implant was not reimbursed by Belgian social health care services and was entirely provided by the patient. The surgery itself was considered a reconstructive procedure. Operative instructions for the preoperative markings and dimensions for the pocket dissection were provided by

the manufacturer (volume, height, width, projection, distance sternal notch to distal border of implant) and the pocket edges were drawn on the patient's chest (Figure 6).

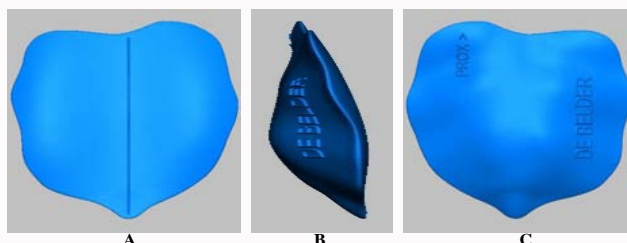
The patients were prepared for surgery by shaving both axillae and chest wall. One dose of peroperative antibiotics (cefazolin 2 g) was administered. Under general anesthesia and through a vertical presternal incision, dissection was carried out onto the anterior periosteum overlying the sternum. The presternal incision size was half of the length of the implant. This incision offers adequate access to the pocket and results in a discrete scar. The sternocostal insertion of the pectoral muscles was released from the sternum and the ribs which allowed us to create the subpectoral pocket by means of a light retractor and monopolar electrocautery (Figure 7A). Prophylactic antiseptic measures were taken (e.g. extensive rinsing of the implant and irrigation of the pocket with iodine solution, disinfection of the surrounding skin and the retractors, new surgical gloves) before implant placement (Figure 7B). Implant rotation was prevented by precise pocket dissection and by preserving a connective tissue band in the midline both superiorly and inferiorly. With a small cut at the corresponding locations on the implant, the implant was seated on these connective tissue strands (Figure 7C). The implant was not sutured to any nearby structure. A suction drain was left



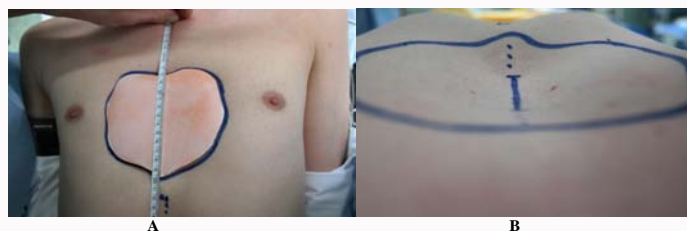
**Figure 3:** Patient #3. Figure A-C: Preoperative pictures. Figure D&E: Sagittal and transverse CT images indicate a secondary minimal deviation of the heart.



**Figure 4:** A&B: 3D reconstructions of the anterior chest wall with the cup-shaped concavity depicted in blue.



**Figure 5:** A-C: The implant is manufactured based on the exact dimensions of the deformity.

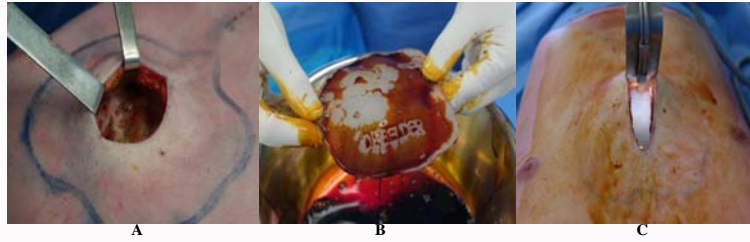


**Figure 6:** A&B: A template of the custom-made implant is placed in the defect and preoperative markings are made with the patient in supine position.

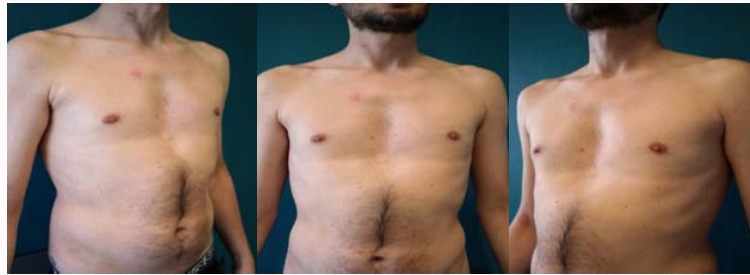behind in the implant pocket. Interrupted polyglactin-910 0 sutures were used for closure of the pectoral fascia, followed by interrupted poliglecaprone-25 3.0 sutures for the deep dermis (interrupted) and a running poliglecaprone-25 3.0 intradermal sutures. Cyanoacrylate skin glue was applied. The mean surgical time for the complete procedure was 57 minutes (range: 45-75 minutes). A thoracic binder was immediately applied and was postoperatively worn for 6 weeks.

## Outcome

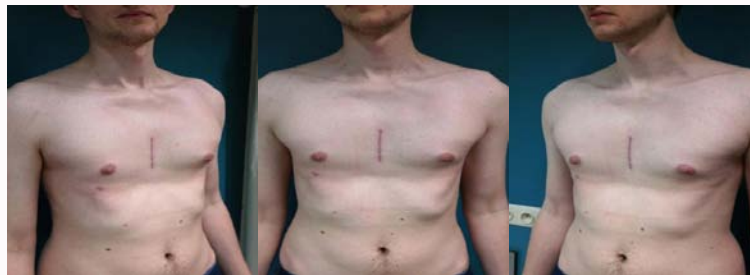Our three patients were able to leave the hospital on postoperative day 1. The first patient had the drain removed on the sixth postoperative day. At postoperative day 12 the patient underwent one aspiration of 15 ml serous fluid. No signs of infection or hematoma were present. The further postoperative course was uneventful and



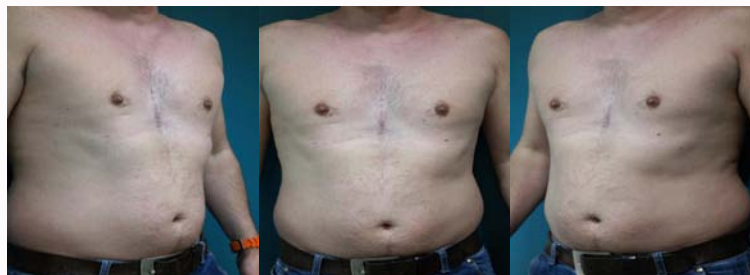**Figure 7:** (A) Through the presternal vertical incision, the subpectoral pocket was dissected. (B) The implant is rinsed in iodine before placement. (C) Implant rotation was avoided by preserving a connective tissue band at 12 h and 6 h. A small cut was made in the corresponding locations on the implant, which allowed these tissue strands to fit.



**Figure 8:** Patient #1, 2 years postoperatively.



**Figure 9:** Patient #2, 2 months postoperatively.



**Figure 10:** Patient #3, 19 days postoperatively.

the incision did not lead to an unsightly scar. The implant was neither visible nor palpable. The patient was very pleased with the result and did not feel any embarrassment anymore about going to the beach bare-chested, although the surgeon evaluated the defect as slightly under corrected. The patient has been followed for 2 years (Figure 8).

The second patient had an uneventful postoperative course except for a superficial venous thrombosis of the basilic vein in the left arm following the peripheral venous line. The drain was removed on postoperative day 8. At 2 months follow-up, the patient and surgeon were satisfied with the result (Figure 9), and no late complications occurred. The third patient had a postoperative drain until day 16.

On day 19, a 20-ml serosanguineous seroma was evacuated through needle aspiration. 3 months postoperatively, the operation resulted in a discrete scar and the patient was pleased with the result (Figure 10).

## Discussion

Pectus excavatum is the most common congenital chest wall anomaly, dominantly seen in men, leading most frequently to an aesthetic dissatisfaction, rather than functional complaints. In 1965 Murray described the insertion of a silicone implant to correct pectus excavatum. Different types of silicones were used and subsequent reports have been encouraging [1-3,8-10]. Some discussion on the grade of silicone and surface qualities do exist given that the defect



involves both soft and hard tissues to replace.

Some implants were created perioperatively using room temperature vulcanizing silastic elastomers [3], other were preformed based on skin molds [1,9-12], in paper mache or alginate, adjusted according to skin thickness studies. Final aesthetic outcome and avoidance of some of the recognized complications with implant reconstruction depend on the design and production of the custom-made implant. The use of bedside molding kits has limited accuracy due to the interposition of soft tissue. It is also time-consuming because on-table modification is needed to seat the implant on the rib cage. More accuracy is achieved with implants that are designed on CT imaging of the thoracic wall and mimic the defect of the bony structures [9-12]. The improvement in CT-scanning and 3D reconstructive software facilitates the production of silicone implants nearly identical to the chest wall defect, which is especially useful in female patients where the soft tissue of the breast fills out the bony defect, and in asymmetrical bony defects [10]. Currently computer aided design and 3D printing are easily accessible and affordable. The material used for 3D custom-made implants has very thin edges and is manufactured from a soft, more flexible grade of silicone which accommodates changes in body posture making it suitable for long-term implantation, easy to mold and less prone to the problem of subcutaneous show of the implant.

Different types of access incisions are used depending on technique, implant elasticity and presence of old scars (transverse subxyphoidal, presternal) [1-8]. Implant position evolved from being prepectoral to mainly subpectoral positioning which leads to better results with a thicker tissue coverage of the implant [8,9,11-13], less palpability and visibility of the implant, and less implant displacement.

Incorporation of holes into the implants has been suggested to be used for anchoring sutures and also to enhance integration with the surrounding tissue [9]. However, when positioned subpectorally with an accurate pocket dissection, no need for implant fixation exists. In our series, implant rotation was also prevented by preserving some connective tissue on the midline both superiorly and inferiorly. With a small cut at the corresponding location on the implant, the implant was seated on these connective tissue strands (Figure 7B).

Seroma was present 7 to 10 days postoperatively in 30% [1-8]. However, by using new positioning techniques, careful pocket dissection and the addition of oral anti-inflammatory medications, the incidence dropped significantly [10]. Other reported complications such as implant show, infection, displacement, capsular contracture, implant rupture or over- and under correction are reported to be rare with the use of accurate design, meticulous operative technique and production of the customized prosthesis based on the 3D CT scans [9,12,14,15].

Other indications for the use of these custom-made implants based on 3D reconstructions are Poland syndrome, pectoralis muscle tears, pectoralis muscle advancement, post-surgical chest wall deformity in well selected adult and even in pediatric postpubertal patients both as primary surgery and as a rescue procedure [10,13,15].

An important limitation to the presented surgical technique is the inability to reduce cardiorespiratory complaints or physiological compromise caused by the pectus excavatum. There for the placement of silicone implant is only recommended in patients without functional complaints. In some patients, symptoms only appear after

puberty and their growth spurt, which is why this procedure cannot be performed before the patient reaches skeletal maturity. On the other hand, in patients with functional complaints or with proven physiological compromise, a more invasive corrective surgery is indicated and preferred. Since these procedures increase the anterior-posterior thoracic dimensions, compression on cardiac chambers can be reduced, which can improve cardiopulmonary function during exercise [16-18].

## Conclusion

The subpectoral placement of the custom-made implant for pectus excavatum is a relatively minor surgical procedure under general anesthesia with short hospital stay and minimal morbidity. It avoids a major reconstruction of the chest wall with its inherent risks and complications and provides a pleasing aesthetic result. Except for a small seroma formation, no complications occurred and patient satisfaction is very high.

Adolescents beyond their growth spurt and adults who are asymptomatic are best served by the simple and direct approach of a silicone implant to correct the chest wall defect. To warrant a good result, the implant should be custom-made based on 3D imaging of the defect formed by the bony structures, the implant should be placed subpectorally in a carefully dissected pocket, and a suction drain should be left in place during a carefully executed short operative procedure. Reimbursement issues are to be dealt with so that this technique can be offered by plastic surgeons to any adult patient with pectus excavatum without functional compromise.

## References

1. Wechselberger G, Öhlbauer M, Haslinger J, Schoeller T, Bauer T, Piza-Katzer H. Silicone implant correction of pectus excavatum. *Ann Plast Surg.* 2001;47(5):489-93.
2. Marks WM, Argenta LC, Lee DC. Silicone implant correction of pectus excavatum: indications and refinement in technique. *Plast Reconstr Surg.* 1984;74(1):52-58.
3. Vecchione TR. Cosmetic correction of the mild or partially corrected pectus excavatum utilizing silastic implant. *Ann Plast Surg.* 1978;1(6):575-8.
4. Jaroszewski D, Notrica D, McMahon L, Steidley DE, Deschamps C. Current management of pectus excavatum: a review and update of therapy and treatment recommendations. *J Am Board Fam Med.* 2010;23(2):230-9.
5. Ravitch MM. The Operative Treatment of Pectus Excavatum. *Ann Surg.* 1949;129(4):429-44.
6. Nuss D, Kelly RE Jr, Croitoru DP, Katz ME. A 10-year review of a minimally invasive technique for the correction of pectus excavatum. *J Pediatr Surg.* 1998;33(4):545-52.
7. Ninkovic M, Schwabegger A, Gardetto A, Moser-Rummer A, Rieger M, Ninkovic M, et al. Free sternum turnover flap for correction of pectus excavatum deformity. *Plast Reconstr Surg.* 2003;112(5):1355-61.
8. Snel BJ, Spronk CA, Werker PMN, Van der Lei B. Pectus excavatum reconstruction with silicone implants: long-term results and a review of the English-language literature. *Ann Plast Surg.* 2009;62(2):205-9.
9. Saour S, Shaaban H, McPhail J, McArthur P. Customized silicone prostheses for the reconstruction of chest wall defects: technique of manufacture and final outcome. *J Plast Reconstr Aesthet Surg.* 2008;61(10):1205-9.
10. Hodgkinson DJ. Chest wall implants: their use for pectus excavatum, pectoralis muscle tears, Poland's syndrome, and muscular insufficiency. *Aesth Plast Surg.* 1997;21(1):7-15.

11. Bisbal Piazuelo J, De Barcia Valero JD. Pectus excavatum: aesthetic correction using customized implants. *Cir plast iberolatinoam*. 2010;36:345-53.
12. Wallmichrath J, Baumeister RG, Giunta RE, Holzbach T, Frick A. Correction of asymmetric pectus excavatum using a virtually designed silicone implant. *Aesth Plast Surg*. 2014;38(1):146-50.
13. Soccorso G, Parikh DH, Worrollo S. Customized silicone implant for the correction of acquired and congenital chest wall deformities: a valuable option with pectus excavatum. *J Pediatr Surg*. 2015;50(7):1232-5.
14. Iyer AR, Powell DK, Irish RD. Pectus excavatum with delayed diagnosis of implant tear on MRI apparently causing recurrent postoperative seromas: a case report. *Skeletal Radiol*. 2015;44(8):1153-6.
15. Johnson PE. Refining silicone implant correction of pectus excavatum through computed tomography. *Plast Reconstr Surg*. 1996;97(2):445-9.
16. Nevieri R, Montaigne D, Benhamed L, Catto M, Edme JL, Matran R, et al. Cardiopulmonary response following surgical repair of pectus excavatum in adult patients. *Eur J Cardiothorac Surg*. 2011;40(2):e77-82.
17. Maagaard M, Tang M, Ringgaard S, Nielsen HH, Frøkiær J, Haubuf M, et al. Normalized cardiopulmonary exercise function in patients with pectus excavatum three years after operation. *Ann Thorac Surg*. 2013;96(1):272-8.
18. Maagaard M, Heiberg J. Improved cardiac function and exercise capacity following correction of pectus excavatum: a review of current literature. *Ann Cardiothorac Surg*. 2016;5(5):485-92.