



## Controversies on Management of Multi-Ligament Injury of Knee: A Case Report and Review on Current Concepts

Anil R\*, Bishwa BN, Aditya KS, Satish K, Chaubey SP and Pradeep KM

Department of Orthopedics, All India Institute of Medical Sciences, Rishikesh, India

### Abstract

**Background:** Multi-ligamentous injury of the knee is a common condition, but difficult to deal with due to their complexity and heterogeneity of ligamentous structures inside knee. Systematic approach for diagnosis and treatment is required to achieve an adequate range of motion.

**Objective:** This paper presents the management of multi-ligamentous knee injury with reconstruction and discusses the controversial topic with suggested literature for management options such as conservative or operative, repair or reconstruction, the timing of surgery, graft selection, and rehabilitation protocol, as well as the proposed literature.

**Case Report:** A 22-year-old female with multi-ligamentous injury of the knee (ACL + PCL + MCL) managed with arthroscopic ACL + PCL reconstruction and open MCL repair after two month of injury, and gradual mobilization started in postoperative phase has a Lyshlom score of knees was 88, and a Tegner Activity Score was 7 at one year of follow-up.

**Discussion and Conclusion:** Early and Operative management is superior compared with non-operative or delayed management. There was a higher rate of inability to return to pre-injury level activity level, flexion loss and posterior sag with repair, although no significant difference exists between reconstruction and repair. Peroneus longus tendon graft has a better functional outcome than the hamstring tendon autograft, but the choice of graft depends on patients' and surgeons' preferences, as well as the number and availability of grafts. In a postoperative rehabilitation, early mobilization help to reduce arthrofibrosis.

**Keywords:** Multi-ligamentous injury; ACL reconstruction; PCL reconstruction; Lyshlom score; Level V

### OPEN ACCESS

#### \*Correspondence:

Anil Regmi, Department of Orthopedics,  
All India Institute of Medical Sciences,  
Rishikesh, India, Tel: 91 8865027410;  
E-mail: regmiaanil@gmail.com

**Received Date:** 17 Apr 2023

**Accepted Date:** 05 May 2023

**Published Date:** 09 May 2023

#### Citation:

Anil R, Bishwa BN, Aditya KS,  
Satish K, Chaubey SP, Pradeep KM.  
Controversies on Management of Multi-  
Ligament Injury of Knee: A Case Report  
and Review on Current Concepts. *Ann  
Med Medical Res.* 2023; 6: 1059.

**Copyright** © 2023 Anil R. This is an  
open access article distributed under  
the Creative Commons Attribution  
License, which permits unrestricted  
use, distribution, and reproduction in  
any medium, provided the original work  
is properly cited.

### Introduction

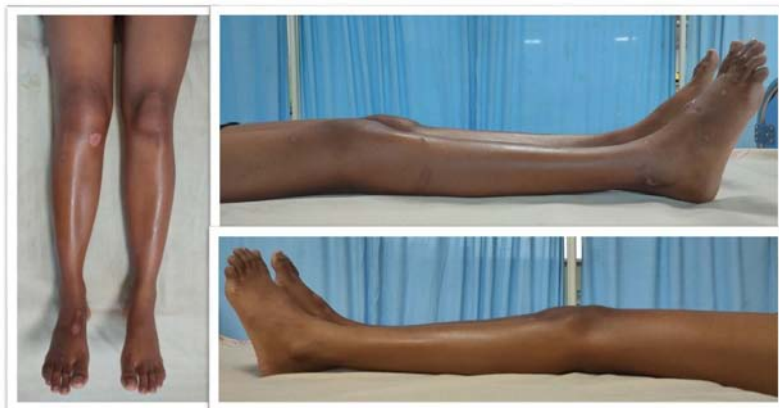Multiple ligaments of knee are involved in approximately one percent of orthopedic injuries [1]. Proper systematic approach and attention to detail for diagnosis and treatment is needed in these cases due to their due complexity and heterogenicity [2]. Proper assessment of injury pattern as well as preoperative assessment of all the structures involved is necessary as it helps to determine the operative plan [3]. Achievement of adequate range of motion before surgery is an essential goal in case of treatment in acute injury [4].

Although a lot of controversies exist regarding the techniques of operation, a lot of effort has been put in, to define the anatomy of ligaments, and to conduct biomechanical tests in ligament-deficient and reconstructed knees, also providing insight regarding the reconstruction of ligaments more anatomically that improvise stability and function [2,4,5].

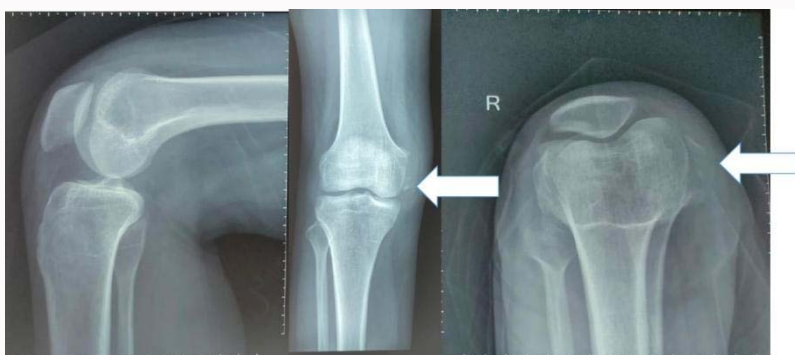This paper presents the treatment of a multi-ligamentous knee injury with ligamentous reconstruction and discusses the controversial topic with suggested literature for management options such as conservative or operative, repair or reconstruction, the timing of surgery, graft selection, and rehabilitation protocol, as well as the proposed literature.

### Case Presentation

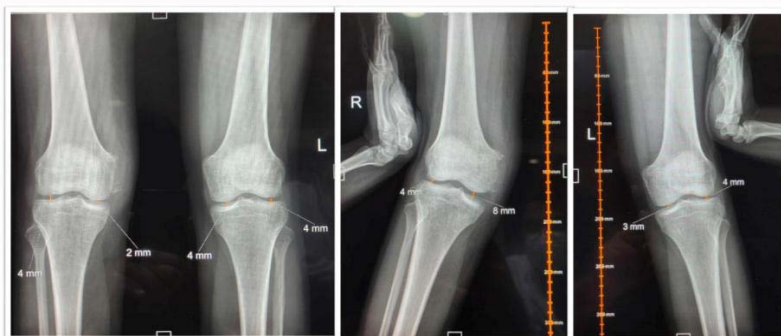A 22-year-old female, student by occupation, presented to the outpatient department Arthroscopic clinic with a complaint of pain and swelling of the right knee joint with a feeling of giving away on the right knee and difficulty walking on the right lower limb for the past two months. She allegedly skidded and fell off a two-wheeler two months ago, sustaining right knee injuries. The patient was managed conservatively on the above-knee slab for the first two weeks. Non-smoker,



**Figure 1:** Preoperative clinical image showing diffuse swelling on right knee, with healed abrasions measuring 6 cm, without any obvious valgus/varus or flexion deformity.



**Figure 2:** Preoperative plain radiograph of the right knee; Lateral, Antero-posterior and Skyline view showing comminuted avulsion fracture of the medial condyle of the femur (arrow).



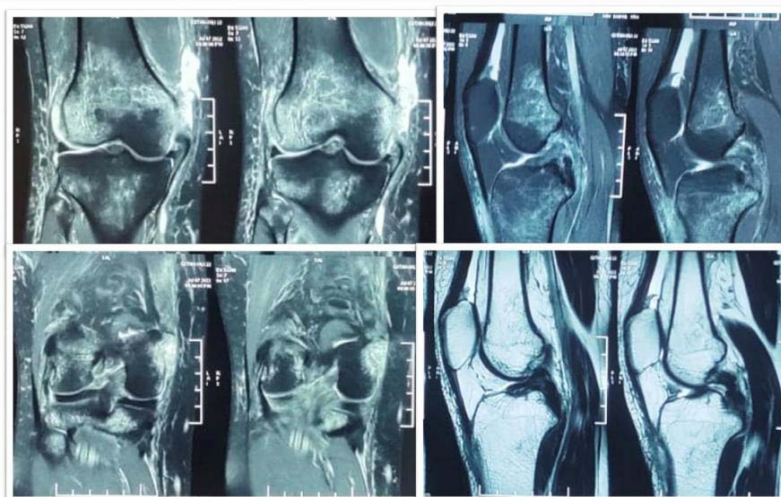
**Figure 3:** Preoperative stress view radiograph, showing significant medial end opening of 8 mm on lateral stress view.

Non-alcoholic. No significant past medical and surgical history. No any drug or any known allergic history. No history of any known comorbidities. No significant family history.

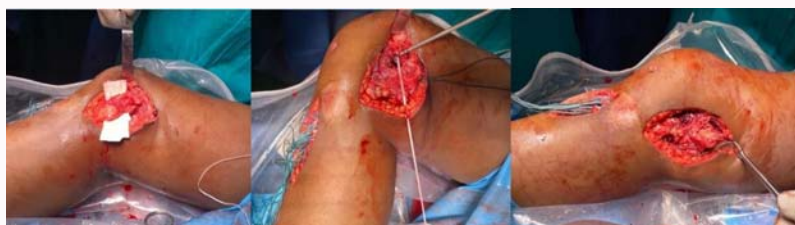At presentation, there was diffuse swelling right knee, with healed abrasions measuring 6 cm, without any obvious valgus/varus or flexion deformity (Figure 1). On palpation, there was tenderness at the medial femoral condyle and palpable crepitus at the medial femoral condyle, and the patellar tap test was positive. The range of motion of the right knee was 0 to 110 degrees. The distal neurovascular system was intact. On further assessment, there was a Lachmann test positive with the soft endpoint. The anterior drawer test was positive, the

Pivot shift test was positive, the Posterior drawer test was positive, the McMurray test was negative for Medial and Lateral meniscus, the Posterior sag was seen on the gravity sign, the Valgus stress test was also positive.

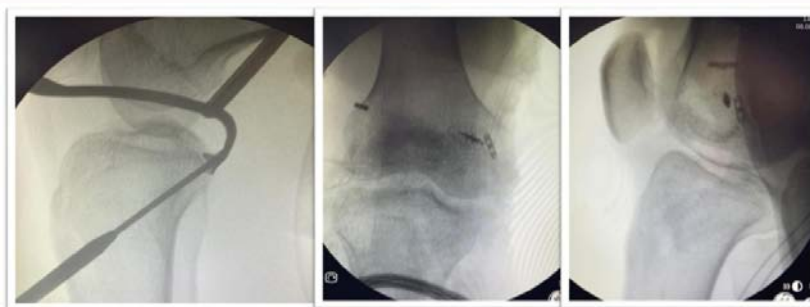A plain radiograph of the right knee was performed, which revealed a comminuted avulsion fracture on the medial femoral condyle (Figure 2). On the stress view radiograph, there is a medial end opening of 8 mm on lateral stress view (Figure 3). MRI revealed gross edema around knee with a comminuted avulsion fracture of medial condyle of femur, there was a partial tear of Anterior Cruciate Ligament injury (ACL) on femoral attachment and intra-substance



**Figure 4:** Preoperative MRI showing gross edema around the knee joint with a comminuted avulsion fracture of the medial condyle of femur, with a partial tear of Anterior Cruciate Ligament injury (ACL) on femoral attachment and intra-substance hyper-intensity with a complete tear of Posterior Cruciate Ligament (PCL) on its mid-substance with empty notch sign, and an avulsion of the Medial Collateral Ligament (MCL).



**Figure 5:** Intraoperative image showing open MCL repair using an anchor suture.



**Figure 6:** Intra-operative fluoroscopy image showing placement of zig for PCL reconstruction and a final construct where the EndoButton of ACL and PCL with the Suture Anchor of MCL in place.

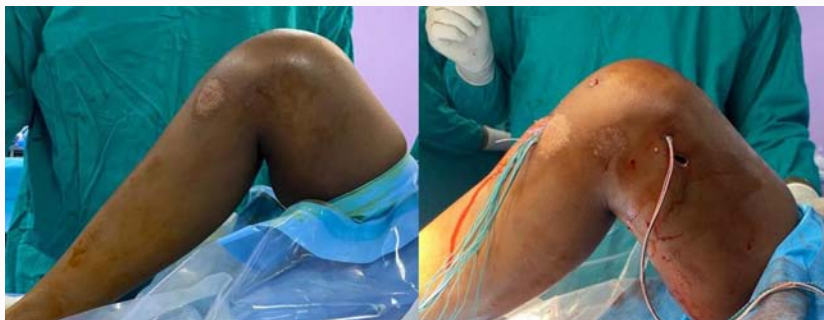hyperintensity with a complete tear of Posterior Cruciate Ligament (PCL) on its mid-substance with empty notch sign, also the evidence of avulsion of the Medial Collateral Ligament (MCL) was present, however, both the menisci were normal (Figure 4). Then the final diagnosis of Multi-ligamentous injury (ACL + PCL + MCL) right knee was made.

After taking the written consent form patient, the patient was taken for surgery under spinal anesthesia. The procedure was performed by the team of Arthroscopic Orthopedic surgeon at Level 1 University level tertiary care center. Ipsilateral Semitendinosus graft and contralateral Peroneus Longus autograft were taken, and augmentation with fiber tape was done for arthroscopic PCL reconstruction. Ipsilateral Peroneus Longus with ipsilateral Gracilis

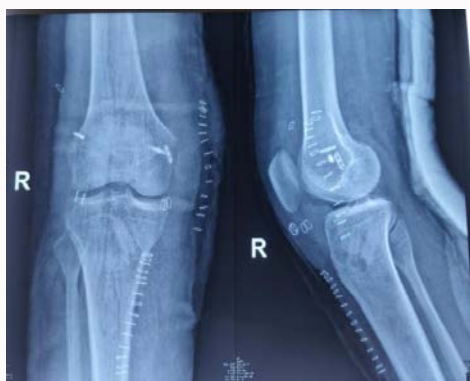autograft were taken, and augmentation with fiber tape was done for arthroscopic ACL reconstruction. Later an open MCL repair was done using an anchor suture (Figure 5). The final construct was confirmed under a fluoroscopy image, where the EndoButton of ACL and PCL with the Suture Anchor of MCL was seen in place (Figure 6). The posterior sag sign present preoperatively also improved clinically after the final construct (Figure 7).

The postoperative period was uneventful. The immediate postoperative radiograph showed EndoButton of ACL and PCL with a suture anchor of MCL seen in place (Figure 8). The patient was maintained on an extended knee brace and started on non-weight-bearing mobilization with the help of a walker on postoperative day 2. On a postoperative day 3, the patient was discharged on an extended





**Figure 7:** Intraoperative image showing posterior sag sign present which improved clinically after the final construct.



**Figure 8:** Postoperative radiograph showing EndoButton of ACL and PCL with a suture anchor of MCL seen in place.

knee brace, converted to a hinged knee range of motion brace on two weeks follow-up. Closed chain Knee range of motion exercise and toe touch bearing mobilization was started two weeks postoperative, and full weight bearing mobilization was started six weeks postoperative. Back to normal activity was initiated three months after the postoperative phase. On follow-up of a patient for one year, the patient did not develop any local or systemic complication, a Lysholm score of knees was 88, and a Tegner Activity Score was 7.

## Discussion

There exists a controversy regarding the management of multi-ligamentous injuries [5]. Although many authors advocate its early management, doubt exists regarding surgical management and improved results [4]. Closed immobilization (casting or external fixation) was used in the past for the management of multi-ligament knee injuries in the past ages [6]. Some recent studies have compared surgical management with non-operative management [7-9]. Thus, the question remains whether the multi-ligamentous knees would be better managed surgically or conservatively [2]. Open dislocation, irreducibility, and disruption and displacement of the popliteal artery require immediate surgery associated with multi-ligamentous injuries [10].

There exists controversy as to repairing or reconstructing damaged structures in the multi-ligamentous injury of the knee. It is well documented in the literature regarding repairs and reconstruction of knee ligamentous structure [6,9,11]. Wide variety of surgical techniques have been reported successful in repairing and reconstructing knee ligaments. Also, there exists a controversy regarding the timing of the surgery [6,9,12]. Although the definitive treatment for chronic injuries can be done anytime, acute injuries

are usually managed within three weeks after trauma [13]. A critical window of three weeks when the tissue structures are intact and the tissue plane are identifiable allows re-approximation and suture placement, is considered crucial [6]. Identification of torn or avulsed anatomy on the lateral aspect of the knee could be difficult for a surgeon due to aggressive anatomy [14]. In studies comparing the timing of surgery, early treatment is associated with improved functional and clinical outcomes. In certain instances of multi-ligamentous knee injuries, the need of early surgeries can't be avoided [6,9]. On the other hand, concomitant life-threatening injuries, and extensive soft tissue loss might prevent early treatment [1]. Due to the higher incidence of arthrofibrosis, acute management is not much considered [12].

## Management; Conservative or Operative

For the management of multi-ligamentous knee injuries, new and more aggressive treatment trend was started during the last decade of 20<sup>th</sup> century [15]. Most studies prefer open surgical repair and reconstruction. Peskun et al. [8], in a systematic review, evaluated a 865 knees in 855 patients which were managed operatively, and 61 knees in 61 patients managed non-operatively. They found a Lysholm score of 84.3 at a mean follow-up of 57.7 months who were operated on and a Lysholm score of 67.2 at a mean follow-up at 70 months who were managed conservatively, which was a statistically significant finding ( $P=0.027$ ). Similarly, the meta-analysis by Dedmond et al. [7] in their study with 132 knee dislocations who were managed surgically and 73 knee managed non-operatively, a significant difference ( $P<0.001$ ) was also found in the Lysholm scores, with a surgical group mean of 85.2, and a non-operative group means of 66.5 at 36 months of follow-up. In a systematic review published by Vincenti et al. [9]. 134 patients managed conservatively has Lysholm score of 67.1 at mean follow up of 53 months and, 987 patients managed operatively had mean Lysholm score of 84.7 at mean follow up of 46.9 months.

Overall, the operative management was superior in terms of clinical and functional outcomes in the available literatures of meta-analysis, systematic reviews, and evidence-based reviews.

## Timing of Surgery; Early or Delayed

A lot of controversies surround regarding the timing of surgery. Surgery performed within three weeks within the injury was considered early surgery in any of the investigations, while delayed surgery was considered surgery performed at any time beyond three weeks [16]. In a systematic review published by Levy et al. [6] on the evaluation of five comparative cohort studies with 80 patients in the early surgery group and 50 patients in the late group at the mean timing of surgical intervention at two weeks in early and mean 51 weeks at

Table 1: Review of literatures.

	Author	Year	Design	Intervention	Number of Knees	Follow up	Lysholm score	P-value	Remarks
Conservative or Operative	Dedmond et al.	2001	Meta-analysis	Conservative	73	36	66.5	<0.001	Operative management is superior compared with non-operative management
				Operative	132	36	85.2		
	Peskun et al.	2011	Systematic review	Conservative	61	70	67.3	0.027	
				Operative	865	57.7	84.3		
	Vicenti et al.	2019	Systematic review	Conservative	134	53	67.1		
				Operative	987	46.9	84.7		
Timing of Surgery	Levy et al.	2009	Systematic review	Early (2wks)	80	40	90		Early surgical treatment resulted in higher functional scores than delayed
				Late (51wks)	50	43	82		
	Vicenti et al.	2009	Systematic review	Early (1.9wks)	86	47.8	89.3		
				Late (54.6wks)	59	50.5	81.7		
	Mook et al.	2009	Systematic review	Acute	244	NA	83.1		
				Chronic	106	NA	85.4		
Staged				46	NA	85			
Repair or Reconstruction	Frosch et al.	2013	Meta-analysis	Repair	40	47	77.5		No significant difference in outcome scores for reconstruction versus repair. However, higher rates of flexion loss, posterior sag, and inability to return to pre-injury activity levels with the repair.
				Reconstruction	73	47	73.3		
	Vicenti et al.	2009	Systematic review	Repair	102	49.3	83.9		
				Reconstruction	109	47.8	84.3		
	Levy et al.	2009	Systematic review	Repair	52	58	87		
				Reconstruction	28	58	88		
Graft Choice	He et al.	2020	Systematic review and meta-analysis	Peroneus longus tendon	102	19	92.48	0.02	Peroneus longus tendon graft has a better functional outcome than the hamstring tendon autograft. But the choice of graft depends on patients' and surgeons' preferences, as well as the number and availability of grafts.
				Hamstring tendon	112	10	91		
Rehabilitation protocol	Mook et al.	2009	Systematic review	Early mobilization	169	NA	82		No difference, but early mobilization helps to reduce arthrofibrosis
				Late mobilization	75	NA	87.5		

late repair found that mean Lysholm Score of 90 in early intervention at mean 40 months of follow up and 82 in late intervention at mean 43 months of follow up. In a systematic review published by Vicenti et al. [9] where they evaluated six articles with early versus delayed surgery, with 86 patients in the early group and 59 patients in the late group, which were operated on at 1.9 weeks in the early and 54.6 weeks in the late group found that the Lysholm score of 89.3 in early and 81.7 in the late intervention group at mean 47.8 months and 50.5 months respectively, with included three studies showing a statistical difference for Lysholm score in favor of the early treatment group. A systematic review by Mook et al. [12] compared the patients operated on acutely in the chronic phase. A staged procedure with 244 patients in the acute phase, 106 in the chronic phase, and 46 patients in a staged procedure found the Lysholm score of 83.1, 85.4, and 85.0 in acute, chronic, and staged procedures, respectively.

The early surgical treatment of multi-ligament knee injuries resulted in higher mean Lysholm scores than delayed treatment. A recently published systematic review on early versus delayed surgery, it was found to be having a significantly better outcome for early intervention. Also, staged approach to multi-ligamentous knee injury was proposed where PCL medial and lateral structures were repaired acutely and ACL later on if needed.

## Surgery; Repair or Reconstruction

Controversy also exists about whether to repair or reconstruct the damaged structures in a multi-ligament injured knee. A systematic

review published by Vicenti et al. [9], including six comparative studies with 102 repairs and 109 reconstructions, has a mean Lysholm score of 83.9 for repair and 84.3 for reconstruction at a mean follow of 49.3 months and 47.8 months, respectively. Frosch et al. [11], on their meta-analysis including nine articles, comparing an aggregate of 195 patients; out of which 40 patients, who had undergone suture repair of the ACL and PCL, showed Lysholm Score of 77.5, whereas 73 with ACL and PCL reconstruction had Lysholm Score of 73.3 at mean follow up of 47 months on both the groups. In a systematic review by Levy et al. [6], including two comparative cohort studies of repair versus reconstruction, 52 patients in repair and 28 patients in reconstruction had a mean Lysholm Score of 87 in repair and 88 in reconstruction at a mean follow-up of 58 months in both groups.

Reconstruction of cruciate ligament is considered superior to repair, evidenced from the single ligament repair and majority of the authors opt this approach [15]. Still dislocated knee doesn't have adequate evidence to support the superiority of reconstruction to repair [13]. Ligament repair is associated with higher rates of inability to return to pre-injury activity levels, flexion loss and posterior sag but studies have showed no significant difference in outcomes between repairs vs. reconstruction.

Regarding PLC, the option of repair or reconstruction depends on variables such as tear pattern, timing of surgery and surgical technique [17]. Few comparative studies have shown superiority of PLC reconstruction to repairs with better outcomes [18,19].

Evidence based systematic review of surgical management (repair and/or reconstruction) of MCL in the vicinity of multi ligamentous injury by Kovacevich et al. [20] suggests lower failure rates with reconstruction as to repair, similar to that of posterolateral corner.

## Graft Choice; Hamstring or Peroneus Longus

Ipsilateral autologous hamstrings are frequently used to reconstruct at least one ligament [2]. Some surgeons also use contralateral hamstrings, while others avoid use of contralateral limb due to associated donor site morbidity [21]. Double ligament reconstruction is usually not problematic for patients who wish to avoid allograft tissue [22]. However, in case if we require more than two ligaments require reconstruction, the contralateral limb will likely be required for harvest, which carries the disadvantage of injuring the previously uninjured extremity [23]. A systematic review and meta-analysis by He et al. [24], comparing the functional outcome following hamstrings and peroneus longus autograft in ACL reconstruction compared 102 patients with peroneus longus tendon has a Lysholm score of 92.48 and 112 patients with Hamstring tendons has a Lysholm score of 91.00 at 19 months of follow up on both group, which shows a statistically significant difference in two groups with a p-value of 0.02.

Although the peroneus longus tendon graft has a better functional outcome than the hamstring tendon autograft, the choice of graft depends on the preference of the surgeon and patient, as well as the availability of graft sources and the number of ligaments requiring reconstruction or augmentation.

## Rehabilitation Protocol; Early or Delayed Mobilization

An early postoperative range of motion has been proposed to help to reduce arthrofibrosis [25]. However, immediate postoperative immobilization is typically expected to help patients to achieve more excellent joint stability [4]. Mook et al. [12], in their systematic review, compared early vs. late mobilization in the postoperative phase, following the multi-ligamentous injury cases, where 169 patients were subjected to early mobilization and 75 were subjected to late mobilization, following which they had a mean Lysholm score of 82.0 in early mobilization and 87.5 in late mobilization, which suggests that there were no significant differences in the average Lysholm score between any of the groups when compared based on the timing of rehabilitation.

The type of rehabilitation in patients for whom surgery is delayed may not affect the outcome as significantly as it does for those who undergo operative treatment immediately.

## Conclusion

Multi-ligamentous injury of the knee is a common condition, but difficult to deal with due to their complexity and heterogeneity of ligamentous structures inside knee. Systematic approach for diagnosis and treatment is required to achieve an adequate range of motion. Early and operative management is superior compared with non-operative or delayed management. There were higher rates of inability to return to pre-injury level activity level, flexion loss and posterior sag with repair, although no significant difference exists between reconstruction and repair. Peroneus longus tendon graft has a better functional outcome than the hamstring tendon autograft, but the choice of graft depends on patients' and surgeons' preferences,

as well as the number and availability of grafts. In a postoperative rehabilitation, early mobilization help to reduce arthrofibrosis.

## References

1. Cole BJ, Harner CD. The multiple ligament injured knee. *Clin Sports Med.* 1999;18(1):241-62.
2. Pardiwala DN, Subbiah K, Thete R, Jadhav R, Rao N. Multiple ligament knee injuries: Clinical practice guidelines. *J Arthrosc Surg Sports Med.* 2021;3(1):40-9.
3. Ockuly AC, Imada AO, Richter DL, Treme GP, Wascher DC, Schenck RC, et al. Initial evaluation and classification of knee dislocations. *Sports Med Arthrosc Rev.* 2020;28(3):87-93.
4. Filbay SR, Grindem H. Evidence-based recommendations for the management of Anterior Cruciate Ligament (ACL) rupture. *Best Pract Res Clin Rheumatol.* 2019;33(1):33-47.
5. Fanelli GC, Stannard JP, Stuart MJ, MacDonald PB, Marx RG, Whelan DB, et al. Management of complex knee ligament injuries. *JBJS.* 2010;92(12):2235.
6. Levy BA, Dajani KA, Whelan DB, Stannard JP, Fanelli GC, Stuart MJ, et al. Decision making in the multiligament-injured knee: An evidence-based systematic review. *Arthrosc J ArthroscRelat Surg.* 2009;25(4):430-8.
7. Dedmond BT, Almekinders LC. Operative versus nonoperative treatment of knee dislocations: A meta-analysis. *Am J Knee Surg.* 2001;14(1):33-8.
8. Peskun CJ, Whelan DB. Outcomes of operative and nonoperative treatment of multiligament knee injuries: An evidence-based review. *Sports Med Arthrosc Rev.* 2011;19(2):167.
9. Vicenti G, Solarino G, Carrozzo M, De Giorgi S, Moretti L, De Crescenzo A, et al. Major concern in the multiligament-injured knee treatment: A systematic review. *Injury.* 2019;50:S89-94.
10. Peskun CJ, Levy BA, Fanelli GC, Stannard JP, Stuart MJ, MacDonald PB, et al. Diagnosis and management of knee dislocations. *Phys Sportsmed.* 2010;38(4):101-11.
11. Frosch KH, Preiss A, Heider S, Stengel D, Wohlmuth P, Hoffmann MF, et al. Primary ligament sutures as a treatment option of knee dislocations: A meta-analysis. *Knee Surg Sports Traumatol Arthrosc.* 2013;21(7):1502-9.
12. Mook WR, Miller MD, Diduch DR, Hertel J, Boachie-Adjei Y, Hart JM. Multiple-ligament knee injuries: A systematic review of the timing of operative intervention and postoperative rehabilitation. *JBJS.* 2009;91(12):2946.
13. Maslaris A, Brinkmann O, Bungartz M, Krettek C, Jagodzinski M, Lioudakis E. Management of knee dislocation prior to ligament reconstruction: What is the current evidence? Update of a universal treatment algorithm. *Eur J Orthop Surg Traumatol.* 2018;28(6):1001-15.
14. Tzurbakis M, Diamantopoulos A, Xenakis T, Georgoulis A. Surgical treatment of multiple knee ligament injuries in 44 patients: 2-8 years follow-up results. *Knee Surg Sports Traumatol Arthrosc.* 2006;14(8):739-49.
15. Medvecky MJ, Zazulak BT, Hewett TE. A Multidisciplinary approach to the evaluation, reconstruction and rehabilitation of the multi-ligament injured athlete. *Sports Med.* 2007;37(2):169-87.
16. Manandhar RR, Chandrashekhar K, Kumaraswamy V, Sahanand S, Rajan D. Functional outcome of an early anterior cruciate ligament reconstruction in comparison to delayed: Are we waiting in vain? *J Clin Orthop Trauma.* 2018;9(2):163-6.
17. Stannard JP, Brown SL, Farris RC, McGwin G, Volgas DA. The posterolateral corner of the knee: Repair versus reconstruction. *Am J Sports Med.* 2005;33(6):881-8.
18. Treme GP, Salas C, Ortiz G, Gill GK, Johnson PJ, Menzer H, et al. A biomechanical comparison of the Arciero and LaPrade reconstruction

- for posterolateral corner knee injuries. *Orthop J Sports Med.* 2019;7(4):2325967119838251.
19. McCarthy M, Ridley T, Bollier M, Cook S, Wolf B, Amendola A. Posterolateral knee reconstruction versus repair. *Iowa Orthop J.* 2015;35:20-5.
20. Kovachevich R, Shah JP, Arens AM, Stuart MJ, Dahm DL, Levy BA. Operative management of the medial collateral ligament in the multi-ligament injured knee: An evidence-based systematic review. *Knee Surg Sports Traumatol Arthrosc.* 2009;17(7):823-9.
21. Bartlett RJ, Clatworthy MG, Nguyen TN. Graft selection in reconstruction of the anterior cruciate ligament. *J Bone Joint Surg Br.* 2001;83(5):625-34.
22. Howells NR, Brunton LR, Robinson J, Porteus AJ, Eldridge JD, Murray JR. Acute knee dislocation: An evidence based approach to the management of the multiligament injured knee. *Injury.* 2011;42(11):1198-204.
23. Weiss NG, Kaplan LD, Graf BK. Graft selection in surgical reconstruction of the multiple-ligament-injured knee. *Oper Tech Sports Med.* 2003;11(3):218-25.
24. He J, Tang Q, Ernst S, Linde MA, Smolinski P, Wu S, et al. Peroneus longus tendon autograft has functional outcomes comparable to hamstring tendon autograft for anterior cruciate ligament reconstruction: A systematic review and meta-analysis. *Knee Surg Sports Traumatol Arthrosc.* 2021;29(9):2869-79.
25. Shelbourne KD, Wilckens JH, Mollabashy A, DeCarlo M. Arthrofibrosis in acute anterior cruciate ligament reconstruction: The effect of timing of reconstruction and rehabilitation. *Am J Sports Med.* 1991;19(4):332-6.