Annals of Clinical Otolaryngology

Case Report
Published: 24 May, 2021

Conservative Treatment of Suprastomal Granuloma

Losano TI, Castellani GB, Zackova M and Uneddu M*

Montecatone Rehabilitation Institute, Bologna, Italy

Abstract

We report a case of a post-tracheotomy suprastomal granuloma causing airway obstruction in a 51-year-old man suffering from a Guillain-Barre Syndrome. The patient had undergone a percutaneous tracheostomy. During rehabilitation period, the patient presented stridor when tracheotomy tube was closed and alteration of the respiratory functionality. An endoscopy procedure was performed and revealed the airway was obstructed by a suprastomal tracheal granuloma. A CT (Computed Tomography) scan confirmed it. The granuloma was managed with the positioning of a Rusch TPS multiflex armored tracheostomy retainer number 6 adapted to the patient's anatomy. The patient was successfully decannulated 2 months after the positioning of the prosthesis with no granuloma recurrence. To the best of our knowledge, the conservative treatment of a tracheal granuloma using a TPS multiflex tracheal silicone prosthesis has not been previously reported. This procedure gives us a chance to treat fragile patients with a minimally invasive technique.

Introduction

Some of the late complications of tracheostomy described in literature include bleeding secondary to a tracheo-innominate fistula, trachea mucosa or stomal the formation of a tracheoesophageal or tracheocutaneous fistula; the development of granulation material around the stoma in the trachea, suprastomal or subglottic area; suprastomal collapse and tracheal or subglottic stenosis [1]. We describe a case of suprastomal granuloma treated conservatively with silicone prosthesis, during inpatient rehabilitation period.

One of the most important goals of the neurological rehabilitation is the tracheostomy tube weaning and the breathing through natural ways achievement.

Case Presentation

The case of a 51 year old man with a Guillain-Barre Syndrome, with a percutaneous tracheostomy was reported. The patient presented a restrictive pulmonary syndrome secondary to the compromised left phrenic nerve and inspiratory stridor with the finger occlusion of the tracheostomy tube. Flexible video endoscopy was performed to evaluate the area, and an anterior, non friable, firm tracheal mass superior to the stoma, with an occlusion of the 50% of the airway (Figure 1) was detected. A TC scan confirmed a soft tissue image closing the airway upper the stoma (Figure 2). Under local anesthesia a Rusch TPS multiflex armored tracheostomy retainer number 6 was placed adapting the prosthesis to the patient's anatomy (Figure 3). It was left in situ for 3 weeks. The prosthesis is available in multiple sizes and is held in position by two flexible inner flanges and an outside faceplate (Figure 4).

After the removal of the prosthesis a cuffless tracheostomy tube number 6 was placed (Figure 5). The patient's vocalization with finger occlusion of the tracheotomy tube improved, inspiratory stridor disappeared and he was able to breathe correctly through his nose with the tracheostomy tube closed. The tracheostomy tube was removed 1 month after its placement.

Discussion

Many changes in the airway secondary to prolonged use of a tracheostomy tube have been reported in literature. These include subglottic and tracheal (suprastomal, stoma and distal) granulomas, tracheal stenosis, tracheal erosion and tracheal collapse [1]. Distal tracheal granulomas are caused by mucosal injury and necrosis from suction tips and tracheostomy tubes. Proximal tracheal and laryngeal granulomas are generally caused when the trachesotomy is high (upper than the second cartilaginous tracheal ring) due to several tracheal and laryngeal trauma when the patient swallows. Soft granulomas develop into a fibrous and covered layer of squamous epithelium that forms fibrosis. With the maturation of fibrosis, stenosis appears as the lateral and anterior feature of the tracheal wall, narrowing the airway [2]. It is very important to treat the granuloma immediately

OPEN ACCESS

Correspondence:
Losano TI, Montecatone Rehabilitation Institute, Bologna, Italy, E-mail: losano.tomas.ignacio@gmail.com

Received Date: *27 Apr 2021*
Accepted Date*: 19 May 2021*
Published Date*: 24 May 2021*

Citation:
Losano TI, Castellani GB, Zackova M, Uneddu M. Conservative Treatment of Suprastomal Granuloma. Ann Clin Otolaryngol. 2021; 6(1): 1051.

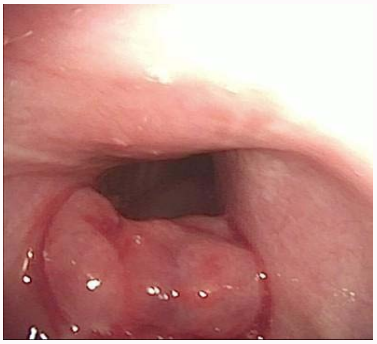

Figure 1: Flexible video endoscopy was performed to evaluate the area, and an anterior, non friable, firm tracheal mass superior to the stoma, with an occlusion of the 50% of the airway was detected.

Figure 2: A TC scan confirmed a soft tissue image closing the airway upper the stoma.

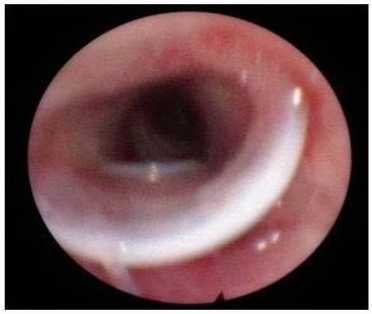

Figure 3: Under local anesthesia a Rusch TPS multiflex armored tracheostomy retainer number 6 was placed adapting the prosthesis to the patient's anatomy.

in order to avoid the evolution to fibrosis and stenosis which is more difficult and risky to treat.

Antibiotics, steroids, and modifications in suction technique may result in the resolution of these granulomas if they are relatively small in size.

Small suprastomal granulomas (less than 30% of the airway) do not require intervention, but larger ones lead do secondary to airway obstruction, bleeding, and represent a risk of death from accidental decannulation [3].

Yellon described 6 rare instances in which suprastomal granulation tissue became a significant complication by obstructing the airway, presumably as a result of abnormal wound healing. Suprastomal granuloma formation is likely due to stasis of secretions, chronic infection, friction or foreign body reaction at the tracheostomy site. Yellon suggested that poorly controlled Gastroesophageal

Figure 4: The prosthesis is available in multiple sizes and is held in position by two flexible inner flanges and an outside faceplate.

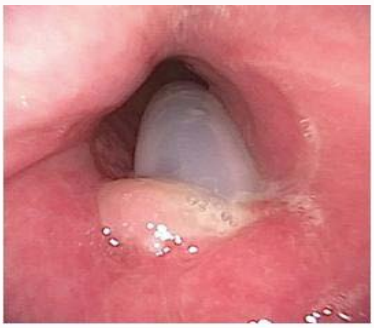

Figure 5: After the removal of the prosthesis a cuffless tracheostomy tube number 6 was placed.

Reflux Disease (GERD) may also contribute by causing mucosal damage and epithelial cell hyperplasia. He also speculated that these 6 patients might have been exposed to an improperly sized and/or secured tracheotomy tube, which might have inflicted trauma on the suprastomal area and increased the risk of granulation tissue formation [4]. In order to prevent further lesions from GERD, our patient was treated with Proton Pump Inhibitor (PPI) medication, 30 mg daily of lansoprazole.

While some suprastomal granulomas can be managed conservatively, surgical excision is necessary in the presence of completely tracheostomy tube obstruction, bleeding, limited phonation or delay in decannulation. The conservative treatment includes dilatation, intralesional steroid injection, Stenting: T-tubes, intraluminal. Granulomas can be removed by means of cold steel (hook eversion, cup forceps, or sphenoid punch), laser (CO_2, KTP, Nd-YAG), microdebrider or coblation. Techniques for treating granulomas include endoscopic techniques and external excision using the endotracheal tube. Excellent visualization and precise excision of suprastomal granulomas can usually be achieved with an endoscopic approach, making it the preferred approach [5,6]. One risk inherent to all types of techniques is the dislodgement of granuloma into the distal bronchi which can lead to acute respiratory failure [7].

Stents play an integral role in managing lower airway obstruction, either in the primary treatment or as an adjunct to reconstruction. Stents support the compromised airway, permit phonation and provide access to the airway lumen. Stenting of narrowed or obstructed tracheal segments with a silastic Tracheal tube (T-tube) was first reported by Montgomery in 1965 [8]. He found this technique most useful in patients in whom previous attempts at laryngotracheal stenosis had failed and in patients who were too sick to undergo more extensive open procedures. But in this case, the underlying motor impairment due to severe quadriplegia, did not allow the use of upper arms to remove the prosthesis in case of obstruction and sudden respiratory failure.

Conclusion

Airway lesions secondary to the placement of the tracheostomy tube must be avoided as well as the morbidity and mortality of fragile patients who have a tracheostomy tube for a long period of time. Therefore, we consider that a multidisciplinary team and a close endoscopy follow up with an early detection of the airway lesions is needed to avoid worse complications. A multidisciplinary team should take decisions about the cannula management in order to frequently cuff pressure measurement with monometer. Therefore, a shared protocol to define suction pressure and techniques for the correct aspiration could be implemented. The protocol should include not only advice on the decannulation process, on the use of fenestration cannula and the unidirectional valve, but also on humidification modalities through tracheostomy tube and correct stoma medication. Finally, the GERD treatment should be managed.

Treating a lower airway obstruction requires a flexible approach that is unique for each patient. Information obtained from the history and physical examination, endoscopic assessment and CT evaluation defines therapy.

Decreasing total cannulation time is beneficial as patients with tracheostomy are subject to high rates of complications and adverse event [9,10].

Conflict of Interest

The authors have no financial considerations to disclose or competing interests in relation to this article.

Acknowledgements

We specially thank Professor Livio Presutti (Bologna University) and Dr Giacomo Ceroni Compadretti (Imola Hospital) for their contribution to this article.

References

1. Bhatia G, Abraham V, Louis L. Tracheal granulation as a cause of unrecognized airway narrowing. J Anaesthesiol Clin Pharmacol. 2012;28(2):235–8.
2. Sue RD, Susanto I. Long-term complications of artificial airways. Clin Chest Med. 2003;24(3):457-71.
3. Gupta A, Cotton RT, Rutter MJ. Pediatric suprastomal granuloma: Management and treatment. Otolaryng. Head Neck Surg. 2004;131(1):21-5.
4. Yellon RF. Totally obstructing tracheotomy-associated suprastomal granulation tissue. Int J Pediatr Otorhinolaryngol. 2000;53(1):49-55.
5. Brown CS, Ryan MA, Ramprasad VH, Karas AF, Raynor EM. Coblation of suprastomal granulomas in tracheostomy-dependent children. Int J Pediatr Otorhinolaryngol. 2017;96:55-8.
6. Shires CB, Shete MM, Thompson JW. Management of suprastomal tracheal fibroma: Introduction of a new technique and comparison with other techniques. Int J Pediatr Otorhinolaryngol. 2009;73(1):67–72.
7. Gupta A, Cotton RT. Rutter MJ. Pediatric suprastomal granuloma: Management and treatment. Otolaryngol Head Neck Surg. 2004;131(1):21–5.
8. Montgomery WW. T tube tracheal stent. Arch Otolaryngol. 1965;82:320-1.
9. Mitchell RB, Hussey HM, Setzen G, Jacobs IN, Nussenbaum B, Dawson C, et al. Clinical consensus statement: Tracheostomy care. Otolaryngol Head Neck Surg. 2013;148(1):6-20.
10. Wilkinson KA, Freeth H, Kelly K, Mason M. On the right trach? A review of the care received by patients who underwent a tracheostomy. National confidential enquiry into patient outcome and death. 2014.