



## Comparison of Spontaneous and Secondary Pneumomediastinum

Natsuki Kawata<sup>1</sup>, Fumihiro Oshita<sup>2\*</sup>, Yuichi Kurakami<sup>1</sup>, Keisuke Iwabuchi<sup>1</sup> and Kohichiro Yoshie<sup>1</sup>

<sup>1</sup>Department of General Medicine, Kanagawa Prefectural Ashigarakami-hospital, Japan

<sup>2</sup>Department of Pulmonary Medicine, Kanagawa Prefectural Ashigarakami-hospital, Japan

### Abstract

**Backgrounds:** Pneumomediastinum (PM) is an uncommon event which defined as the presence of free air in the mediastinum.

**Methods:** We retrospectively examined backgrounds, onset, treatments and outcomes of PM and compared spontaneous and secondary PM.

**Results:** There were ten and 5 patients in spontaneous and secondary PM. Patients with secondary PM had interstitial pneumonitis, COPD or pneumonia. Every patient of both groups had slender body such as Body Mass Index range 14.2 to 24.2. Spontaneous PM occurred at rest or desk work in 5 of 10 patients. Onset was unknown in 4 of 5 patients of secondary PM. Every patient except early death of both groups was improved by bed rest with or without oxygen therapy in several to 15 days. All 5 patients of secondary group died with coexisting pulmonary illness within 3 months.

**Conclusion:** Both spontaneous and secondary spontaneous PM are well prognosis, however coexisting illness determine prognosis in secondary PM.

### OPEN ACCESS

### Introduction

Pneumomediastinum (PM) is an uncommon event which defined as the presence of free air in the mediastinum. Its clinical picture includes retrosternal chest pain, subcutaneous emphysema, dyspnea, dysphagia, dysphonia and asthenia. PM is further divided into two groups of patients: spontaneous PM, without any obvious primary source, and secondary PM, with a specific responsible pathologic event, such as trauma, intrathoracic infections and violation of the aerodigestive track or others.

Spontaneous PM was originally described in 1939; thus, the crepitus heard with the heartbeat on chest auscultation is known as the Hamman sign [1]. Spontaneous PM is generally described as a benign condition, presenting in young adults exposed to a sudden pressure change within the intrathoracic cavity. According to first report of pathogenesis of spontaneous PM, a sudden increase in intrathoracic pressure results in increased intra-alveolar pressure [2]. The pressure differential created within the pulmonary parenchyma leads to alveolar rupture with further leakage of air throughout the interstitium and bronchovascular tissue sheath following a centripetal pattern toward the mediastinum. In clinical practice, spontaneous PM often develops as a result of various precipitating events triggering a strong Valsalva maneuver, creating the pressure differential needed for its genesis. In respiratory PM, released alveolar air centripetally dissects through the pulmonary interstitium along the bronchovascular sheaths toward the pulmonary hila, into the mediastinum [3]. This pathophysiological mechanism was described by Macklin and Macklin [4], and is known as the Macklin effect. This effect appears on thoracic computed tomography (CT) as linear collections of air contiguous to the bronchovascular sheaths [5-7]. The air dissects into the pulmonary hila and from there enters the mediastinum.

Secondary PM comprises the bulk of experience with PM. In the majority of cases, it is initiated by blunt or penetrating trauma, recent interventions in the esophageal or tracheobronchial tree, rupture of a hollow viscus, tissue dissection originating from a spontaneous pneumothorax, pulmonary or mediastinal infection by gas-forming organisms [8]. Spontaneous PM is often difficult to differentiate from more subtle causes of secondary PM, such as contained esophageal perforation, minor tears in the central tracheobronchial tree, and smoldering pulmonary and mediastinal infections. It is essential to confirm the absence of a secondary pathological event responsible for

#### \*Correspondence:

Fumihiro Oshita, Department of Pulmonary Medicine, Kanagawa Prefectural Ashigarakami-hospital, Matsudasoryo 866-1, Matsuda, Kanagawa 258-0003, Japan, Tel: +81-465-83-0351; E-mail: foshita@ashigarakami-hospital.jp

Received Date: 01 Aug 2017

Accepted Date: 11 Sep 2017

Published Date: 18 Sep 2017

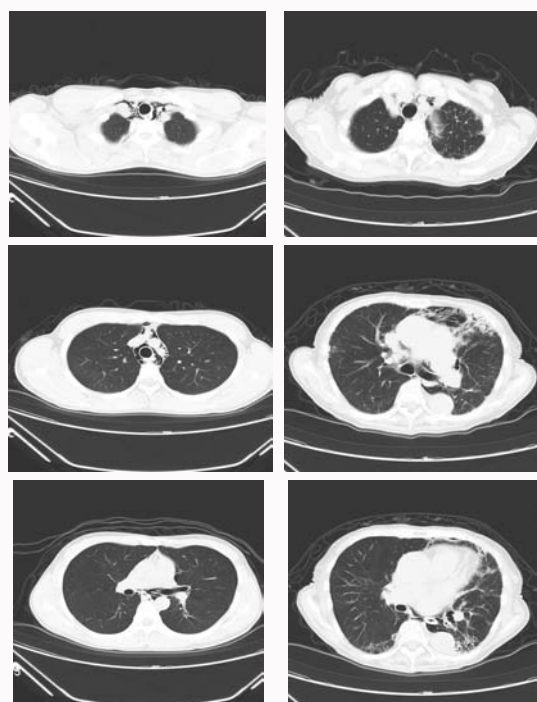
#### Citation:

Kawata N, Oshita F, Kurakami Y, Iwabuchi K, Yoshie K. Comparison of Spontaneous and Secondary Pneumomediastinum. *J Respir Med Lung Dis.* 2017; 2(3): 1022.

ISSN: 2475-5761

Copyright © 2017 Fumihiro Oshita.

This is an open access article distributed under the Creative Commons Attribution License, which permits unrestricted use, distribution, and reproduction in any medium, provided the original work is properly cited.



(A) 19-years-old, male  
Spontaneous case

(B) 91-years-old, female  
Secondary case

**Figure 1:** Chest CT revealed pneumomediastinum; (A) spontaneous case and (B) secondary case with interstitial pneumonitis.

the presence of mediastinal air.

In this retrospective study, we examined backgrounds, onset, treatments and outcomes of PM and compared spontaneous and secondary PM.

## Patients and Methods

Patients who diagnosed as PM on CT in Kanagawa Prefectural Ashigarakami Hospital were entered in this retrospective study. Patients who experienced recent aero digestive tract interventions, recent thoracic, cardiac, abdominal, or cervical surgical interventions, cervical soft tissue or intrathoracic infection and esophageal perforation were excluded. Trauma-related patients were also excluded. They were divided two groups; spontaneous and secondary PM. Secondary PM was defined who have other pulmonary lesions. We examined their backgrounds such as age, weight, height, smoking history, and coexisting illness, onset of the PM, treatments and outcomes. We compared these factors in each groups.

## Results

Between January 2011 and February 2016, fifteen patients were detected PM on Chest CT (Figure 1). There were ten patients in spontaneous PM (Table 1). Nine were male and another was female. Their age range was 16 to 25 years old. Their heights were various, but weights of them were 46.6 kg to 62.0 kg and body mass index (BMI) was low such as median 18.1 and range 15.8 to 22.6. Smoker was only 2 patients. Nine patients visited our hospital because their cervical to anterior chest pain continued for several to 12 hours (Table 2). One patient was discovered at unconsciousness status and was transferred by emergency car. Five of 10 patients experienced pain attack at rest or desk working. Only one of 10 patients showed mild tachycardia and hypotension. Vital signs of other nine patients were normal. Nobody

**Table 1:** Patient characteristics.

Total			Spontaneous	Secondary
			number of patients	number of patients
			10	5
Gender	male		9	3
	female		1	2
Age (years)	median	19	82	
	range	16-25	76-91	
Height (cm)	median	173	168	
	range	160-183	150-168.5	
Weight (kg)	median	54.5	43	
	range	46.6-62.0	39-55	
BMI	median	18.1	17.1	
	range	15.8-22.6	14.2 - 24.2	
Complication	yes		1	5
	no		9	0
Smoking	yes		2	1
	no		8	4

**Table 2:** Patient complaints and vital signs.

		number of patients	
		Spontaneous	Secondary
Onset	At rest	1	1
	Desk work	4	0
	Standing work	2	0
	Swimming	2	0
	Sneeze	1	0
	Unknown	0	4
Symptoms*	Chest pain	8	0
	Cervical or shoulder pain	5	1
	Dyspnea	2	2
	Chest oppression	1	1
	Cough	0	1
Duration (onset to visit)	hours	10	0
	days	0	4
	unknown	0	1
Fever	None	6	3
	Low grade	4	2
Hypoxia (Sat O <sub>2</sub> <95 torr)		0	1
Tachycardia (>100/min)		1	3
Hypotension (Sys. Pressure<100)		1	0

\* Some patients complained several symptoms.

showed hypoxia. Besides, five patients of secondary PM were elderly aged 76 to 91 years old (Table 1). Their BMI was low such as median 17.1 and range 14.2 to 24.2. All 5 patients could not remember onset of their condition and visited our hospital because of vague cervical or chest pain or dyspnea continuing for several days (Table 2). Three of them showed tachycardia with low grade fever at administration and 1 showed hypoxia. Laboratory data in peripheral blood and biological examination revealed almost normal in every 15 patient. Every patient of both groups kept rest in bed. Seven and 3 patients received oxygen

**Table 3:** Patient outcomes.

		Spontaneous	Secondary
		number of patients	number of patients
Improve	yes	10	3
	no	0	2
Days to improve	median	4	7
	range	2-8	6-15
Prognosis	alive	10	0
	death	0	5
Days to death	median	-	30
	range	-	16-90

treatment in spontaneous and secondary group, respectively (Table 3). Two patients in spontaneous group required pain reliever drugs. One patient with secondary PM received corticosteroid therapy against his complicated interstitial pneumonitis. Spontaneous PM improved after administration in 2 to 9 days. PM recurred after 6 and 7 months in 2 patients but improved at rest. On the other hands, secondary PM of 3 patients improved in 6 to 15 days, however other 2 patients did not show the recovery because they died at day 6 or at day 30. Every 5 patients complicated secondary PM died within 3 months because of coexisting pulmonary illness.

## Discussion

The diagnosis of PM is revealed by radiographic examination. Caceres et al. [9] described that only 69% of cases were discovered by plain chest X-ray. It was difficult to detect PM with only a plain chest X-ray film and required CT for its diagnosis in every patient in our study. The similar data was described in previous report [10]. CT has the gold standard for diagnosing this lesion. Respiratory PM is a result of rupture along the alveolar tree, which leads to an abrupt increase in the intra-alveolar pressure. Released alveolar air centripetally dissects through the pulmonary interstitial along the bronchovascular sheaths toward the pulmonary hila, into the mediastinum [3,11], CT scans of our patients did not show these signs, who admitted after several hours passed from onset, it is possible these signs on CT disappear within several hours from its onset.

Most series describe the presence of a triggering event before the development of spontaneous PM. Numerous immediate preceding events have been noted, including forceful emesis, intense coughing, inhalational drugs, physical activity, intense screaming, spirometry, childbirth, bronchospasm, and playing of wind instruments [12-17]. There are variable data in the literature regarding triggering events responsible for the origin of the spontaneous PM; however, reported triggering events lists the most frequent ones as emesis, intense physical activity, coughing, and intense screaming. The trigger of our defined secondary PM was considered intense coughing and intense screaming, however 5 of 10 spontaneous group experienced at rest or desk work. They did not remember trigger of PM, they might be caused as a result of a mild to moderate Valsalva maneuver at desk work.

Nine of ten spontaneous PM in our study occurred in young male adults. Their median BMI was 18.1. This showed the lesion occurred in patients with slender body which is similar to spontaneous pneumothorax. Pulmonary organ might develop gradually and complete in 20 to 30 years old. Tracheobronchial tree might be weak at end-stage of growth phase. Muscle or fat tissues of slender body

are considered less. Thus this PM may be occur in young slender adult. Otherwise, secondary PM without traumatic events occurred as a result of fibrotic destroyed lung. Secondary pneumothorax occurs in pulmonary lesions to induce fibrotic change. Both PM and pneumothorax is terminal phenomenon of destroyed lung disease. Thus, we agreed all patients experienced secondary PM died within 3 months.

Although chief complaint was chest pain, pain reliever was required in only 2 patients. This might suggest PM recovery initiated from onset of the lesion. Both spontaneous and secondary PM in our study did not impair cardiac and pulmonary functions at admission. Improvement of PM was rapid in several days by rest and special treatment such as pneumothorax is not required. PM in our study, whichever spontaneous or secondary coexisting pulmonary lesions, were improved within 2 weeks and are considered a benign condition.

In conclusion, we compared PM between spontaneous and secondary with coexisting pulmonary illness. Both occurred in patients with slender body and improved in several days to 2 weeks by rest with or without oxygen therapy. Patients of spontaneous PM have well prognosis, however those of secondary PM showed poor because they die with coexisting pulmonary disease.

## References

- Hamman L. Spontaneous mediastinal emphysema. *Bull Johns Hopkins Hosp.* 1939;64:1-21.
- Mecklin CC. Transport of air along sheaths of pulmonary blood vessels from alveolus to mediastinum. *Arch Int Med.* 1979;64:913-26.
- Wintermark M, Wicky S, Schnyder P, Capasso P. Blunt traumatic pneumomediastinum: using CT to reveal the Macklin effect. *AJR Am J Roentgenol.* 1999;172(1):129-30.
- Macklin MT, Macklin CC. Malignant interstitial emphysema of the lungs and mediastinum as an important occult complication in many respiratory diseases and other conditions: interpretation of the clinical literature in the light of laboratory experiment. *Medicine.* 1944;23(4):281-358.
- Sakai M, Murayama S, Gibo M, Akamine T, Nagata O. Frequent cause of the Macklin effect in spontaneous pneumomediastinum: demonstration by multidetector-row computed tomography. *J Comput Assist Tomogr.* 2006;30(1):92-4.
- Kaneki T, Kubo K, Kawashima A, Koizumi T, Sekiguchi M, Sone S. Spontaneous pneumomediastinum in 33 patients: yield of chest computed tomography for the diagnosis of the mild type. *Respiration.* 2000;67(4):408-11.
- Franquet T, Giménez A, Torrubia S, Sabaté JM, Rodríguez-Arias JM. Spontaneous pneumothorax and pneumomediastinum in IPF. *Eur Radiol.* 2000;10(1):108-13.
- Macia I, Moya J, Ramos R, Morera R, Escobar I, Saumench J, et al. Spontaneous pneumomediastinum: 41 cases. *Eur J Cardiothorac Surg.* 2007;31(6):1110-4.
- Caceres M, Ali SZ, Braud R, Weiman D, Garrett HE Jr. Spontaneous pneumomediastinum: a comparative study and review of the literature. *Ann Thorac Surg.* 2008;86(3):962-6.
- Abolnik I, Lossos IS, Breuer R. Spontaneous pneumomediastinum. A report of 25 cases. *Chest.* 1991;100(1):93-5.
- Murayama S, Gibo S. Spontaneous pneumomediastinum and Macklin effect: Overview and appearance on computed tomography. *World J Radiol.* 2014;6(11):850-4.
- Mondello B, Pavia R, Ruggeri P, Barone M, Barresi P, Monaco M. Spontaneous pneumomediastinum: experience in 18 adult patients. *Lung.* 2007;185(1):9-14.

13. Koullias GJ, Korkolis DP, Wang XJ, Hammond GL. Current assessment and management of spontaneous pneumomediastinum: experience in 24 adult patients. *Eur J Cardiothorac Surg.* 2004;25(5):852-5.
14. Gerazounis M, Athanassiadi K, Kalantzi N, Moustardas M. Spontaneous pneumomediastinum: a rare benign entity. *J Thorac Cardiovasc Surg.* 2003;126(3):774-6.
15. Nemet D, Suchard JR, DiBernardo LM, Mukai DS, Cooper DM. Pneumomediastinum and subcutaneous emphysema after pulmonary function tests in a young healthy woman. *Eur J Emerg Med.* 2004;11(2):105-7.
16. Miura H, Taira O, Hiraguri S, Ohtani K, Kato H. Clinical features of medical pneumomediastinum. *Ann Thorac Cardiovasc Surg.* 2003;9(3):188-91.
17. Praski A, Kupis W, Florczak M, Szpetnar M. [Mediastinal and subcutaneous emphysema as a complication of labor]. *Ginekol Pol.* 2007;78(4):329-32.