



Central Catheter Placement in Severe Lipomatous Hypertrophy of the Interatrial Septum

Kyle Luecke¹, Cesar Lam², Rikesh Makanji², David Carroll¹, Daniel Jeong^{2*}

¹Department of Radiology, University of South Florida, USA

²Department of Radiology, Moffitt Cancer Center, USA

Abstract

Lipomatous Hypertrophy of the Interatrial Septum (LHIS) is an anatomical variant condition defined by a thickened fat containing interatrial septum. It is an incidental finding on radiologic imaging and echocardiography exams seen on approximately 2% of computed tomography exams, however a large spectrum of this condition exists. Atypical LHIS has been used to describe more diffuse lipomatous infiltration which can extend to the superior vena cava, right atrium, and left atrium. Life threatening complications have been reported which warranted surgical intervention. We present a case of severe atypical lipomatous hypertrophy of the interatrial septum and important considerations surrounding central catheter placement.

Keywords: Lipomatous hypertrophy of the interatrial septum

Introduction

Abnormalities of cardiovascular anatomy can often complicate central venous catheter placement. Lipomatous Hypertrophy of the Interatrial Septum (LHIS) is an anatomical variant that involves fatty proliferation of the cardiac interatrial septum, however a rarer atypical severe form has been associated with multiple complications. We report a case of central venous catheter placement in a patient with severe cavoatrial stenosis secondary to atypical LHIS, and discuss potential complications that should be anticipated following catheter placement.

Case Presentation

A 68 year old female with a history of hypertension, hyperlipidemia, diabetes mellitus, coronary artery disease, and stage IV non-small cell lung cancer presented to interventional radiology for port placement in anticipation of chemotherapy administration. Pre-procedural review of the initial staging computed tomography (CT) exam revealed incidental extensive non-enhancing fat density in the interatrial septum contiguous with the upper right atrial wall and Lower Superior Vena Cava (SVC), resulting in high grade stenosis near the cavoatrial junction (Figure A,B). No collateral vessels were identified in the mediastinum or chest wall to suggest chronic SVC obstruction. Findings were compatible with atypical severe LHIS causing high grade cavoatrial stenosis. On clinical exam, the patient had no signs or symptoms of SVC syndrome, associated dyspnea, or attributable arrhythmias. A tunneled Mediport was placed via a right internal jugular vein approach and no complications were encountered. The intervention list experienced no difficulties passing the guide wire or catheter, and fluoroscopic imaging of the catheter demonstrated appropriate location of the catheter tip in the proximal right atrium. Subsequent CT examination performed 8 weeks after port placement showed the port catheter traversing the stenotic cavoatrial junction. No change in LHIS or evidence of catheter related complications such as thrombus or malposition were identified, and at 12 weeks no clinical signs or symptoms of SVC syndrome were noted.

Anatomic abnormalities such as LHIS can introduce unexpected difficulties and consequences when placing central venous catheters. Lipomatous hypertrophy of the interatrial septum is an uncommon but typically benign condition characterized by fatty infiltration of the interatrial septum with a thickness of > 2 cm and sparing of the fossa ovalis, creating a characteristic bilobar or hourglass configuration on imaging [1]. The reported incidence has ranged from 1% found on autopsy to 8% in reviews of transthoracic echocardiography. While the exact etiology is unclear, predisposing factors include obesity, advanced age, female sex, and patients with metabolic disorders [1,2].

OPEN ACCESS

*Correspondence:

Daniel Jeong, Department of radiology, Moffitt cancer center, FL 33612, Tampa, Florida, USA, Tel: 813 745 8910; Fax: 813 745 5762;

813 745 5762;

E-mail: Daniel.jeong@moffitt.org

Received Date: 02 Mar 2018

Accepted Date: 12 Apr 2018

Published Date: 19 Apr 2018

Citation:

Luecke K, Lam C, Makanji R, Carroll D, Jeong D. Central Catheter Placement in Severe Lipomatous Hypertrophy of the Interatrial Septum. *Ann Obes Relat Dis*. 2018; 1(1): 1001.

Copyright © 2018 Daniel Jeong. This is an open access article distributed under the Creative Commons Attribution License, which permits unrestricted use, distribution, and reproduction in any medium, provided the original work is properly cited.

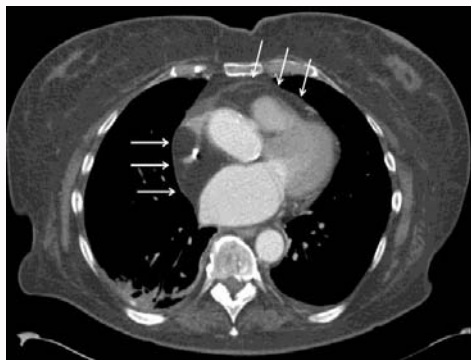

Figure A: Contrast enhanced axial CT image demonstrates fat density tissue (-90 Hounsfield units) arising from the interatrial septum which circumferentially narrows the lower SVC and proximal right atrium. Fat density tissue extends to the lateral right atrial wall and anteriorly along the right ventricular outflow tract (arrows). Post-processing revealed the cavoatrial lumen to measure 0.65 cm² area (normal 6.79- 10.02 cm²)(8) with the catheter tip occupying approximately 0.23 cm².

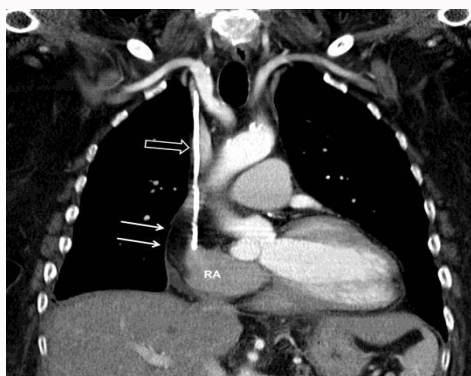


Figure B: Coronal oblique reformatted CT image shows catheter (open arrow) terminating in the right atrium. Circumferential fat density tissue (arrows) narrows the superior vena cava lumen and extends along the lateral wall of the right atrium.

Although LHS is usually asymptomatic, the atypical severe form has been associated with significant symptoms including atrial arrhythmias, obstructive flow symptoms, congestive heart failure, valvular disruption, and sudden cardiac death [1,2]. Central venous catheter placement, too, has been independently associated with obstruction, thrombosis, and arrhythmias [3]. Acute SVC syndrome has been reported following central venous catheter placement, attributed to catheter occlusion of previous subclinical stenosis of the SVC [2,4]. Furthermore, obstruction at the cavoatrial junction has been shown to create turbulent flow within the SVC, which can contribute to the formation of thrombi [5]. Transesophageal echocardiography has been used to better visualize LHS and facilitate the passage of catheters past an obstructing mass [5,6].

While internal jugular vein access is the favored site for port catheter placement, alternative sites may also be considered including femoral vein access. Successful femoral vein approach port placement has been performed in cases of complete SVC occlusion and in multiple cases of bilateral mastectomy [7,8]. However, there is a relative increased risk of infection using femoral access compared to internal jugular access. In addition, folding of the subcutaneous course of the catheter can occur in overweight patients impeding flow. In our patient, the decision was made to place the port from an internal jugular approach given the lack of classic SVC obstructive symptoms. The patient was monitored closely after port placement with a low threshold for SVC syndrome symptomatology, in which case catheter removal with alternative site placement would be indicated.

Although LHS is typically a benign finding, it is important to recognize complications that might arise from atypical LHS following catheter placement. Moreover, close clinical monitoring is warranted following internal jugular approach central catheter placement in patients with atypical LHS.

References

1. Xanthos T, Giannakopoulos N, Papadimitriou L. Lipomatous hypertrophy of the interatrial septum: a pathological and clinical approach. *Int J Cardiol.* 2007;121(1):4-8.
2. Cheezum MK, Jezior MR, Carbonaro S, Villines TC. Lipomatous hypertrophy presenting as superior vena cava syndrome. *J Cardiovasc Comput Tomogr.* 2014;8(3):250-1.
3. Gibson F, Bodenham A. Misplaced central venous catheters: applied anatomy and practical management. *Br J Anaesth.* 2013;110(3):333-46.
4. Woodyard TC, Mellinger JD, Vann KG, Nisenbaum J. Acute superior vena cava syndrome after central venous catheter placement. *Cancer.* 1993;71(8):2621-3.
5. Hsieh TC, Schiller NB, Joshi RV. Extensive lipomatous hypertrophy of the interatrial septum with involvement of the right atrium. *Anesth Analg.* 2010;110(3):725-6.
6. Scholten KJ, Soran PD, Van der Starre PJ. Obstruction of pulmonary artery catheterization because of lipomatous hypertrophy of the interatrial septum. *J Cardiothorac Vasc Anesth.* 2008;22(5):751-2.
7. Heiss P, Stroszczyński C, Gossmann H. [Superior vena cava occlusion: Radiological placement of a central venous port system via femoral vein access]. *Radiologe.* 2012;52(5):455-8.
8. Bergman R, Afifi AK, Miyauchi R. *Illustrated Encyclopedia of Human Anatomic Variation: Opus II.* 2015.