Annals of Orthopedic Surgery Research

Research Article
Published: 13 May, 2019

# Cementless Total Hip Arthroplasty with Transverse Subtrochanteric Shortening Osteotomy in Developmental High Dislocated Hips and Minimum 6 Years Follow-up

***Berk Güçlü****

*Department of Orthopaedics and Traumatology, Ufuk University, Turkey*

## Abstract

**Introduction:** The purpose of this paper was to evaluate the functional and clinical results of the developmental high-dislocated hip patients applied subtrochanteric transverse shortening osteotomy fixed axially and rotationally by cementless femoral stem and the acetabular component placed into the anatomical place.

**Methods:** In this retrospective study, the results of fifty consecutive primary cementless total hip arthroplasty in twenty-eight patients (twenty-six female and two male) all of whom had Crowe 4 (Hartofilakidis type 3) high dislocations were evaluated. The arthroplasty was performed in combination with a subtrochanteric transverse shortening osteotomy and Zweymüller femoral stem (SL plus) without any fixation instruments for the osteotomy site and with placement of the acetabular component at the level of anatomic hip center.

**Results:** The mean Harris Hip Score increased from 24.03 points preoperatively to 82.88 points at the time of final follow up. Ten of the fifty hips had an early or late complications and/or revisions. None of the subtrochanteric osteotomies were resulted with nonunion and no other complications concerning the femoral site were encountered. There was one case of isolated loosening of acetabular component. Two hips dislocated postoperatively which were treated by closed reduction and bracing for 12 weeks. One sciatic neurapraxic injury was identified which resolved conservatively within 6 month time. Intraoperative femoral fracture was seen in three hips. One of them on the proximal part (trochanteric site) and the other two on the distal femur. All were fixed by cerclage and cables. Heterotopic ossification was seen in three hips.

**Conclusion:** Subtrochanteric shortening osteotomy and cementless total hip arthroplasty for the treatment of Crowe 4 (Hartofilakidis type 3) high dislocations of the hip were associated with high rates of successful fixation of the femoral component and the acetabulum. Adequate union has seen at the osteotomy site within the eight weeks' time without any complications.

**OPEN ACCESS**

***Correspondence:***
*Berk Güçlü, Department of Orthopaedics and Traumatology, Ufuk University, Turkey,*
*E-mail: gucluberk@yahoo.com*

**Received Date**: *19 Apr 2019*
**Accepted Date***: 06 May 2019*
**Published Date***: 13 May 2019*

***Citation:***
*Güçlü B. Cementless Total Hip Arthroplasty with Transverse Subtrochanteric Shortening Osteotomy in Developmental High Dislocated Hips and Minimum 6 Years Follow-up. Ann Orthop Surg Res. 2019; 2(1): 1007.*



## Introduction

High Developmental Dislocation of Hip (DDH) is a rare and challenging clinical issue and one of the most common reasons of leg length discrepancy. In high DDH, the affected hip joint has some anatomical distortions. The femoral head articulates with iliac wing, superiorly (and posteriorly in some cases) to the true acetabulum. The true acetabulum is hypo plastic, porotic and fibrotic. The anterior wall is thin whereas posterior wall is thick and depth is inadequate [1]. Femoral intramedullary canal is narrow, femoral ante version is increased and greater trochanter is located posteriorly. In addition to these, due to the chronicity of dislocation, soft tissues surrounding the hip joint are contracted [2]. The sciatic nerve is shortened and the course of the femoral nerve and the profunda femoris artery is distorted [3]. Proximal displacement of the femoral head leads to not only more horizontal direction of the abductor muscles but also elongation of the abductor muscles [4-7].

In 1988, Hartofilakidis et al. classified dysplasia in three groups based on anatomical correlations. For dislocated hips (type 3), two distinct patterns of dislocations were outlined [8]. In this study, all of the hips have no articulation with any part of the true acetabulum.

The successful placement of the acetabular cup demands on anatomic reduction without causing excessive compressive loads across the hip joint. To achieve this, it is recommended that THA

**Figure 1:** Preoperative X-ray of 54 years old female patient's right hip with DDH Crowe type 4. The length of the resection was calculated by the vertical distance between teardrop lines drawn through the edge of teardrops. She had undergone right total hip arthroplasty for her right hip previously.

should be combined with femoral shortening [9]. Femoral shortening osteotomy was first described by Klisic and Jankovic for high DDH and was adapted by Sponseller and McBeath in 1993 [2].

The purpose of our study was to evaluate the functional and clinical results of the developmental high-dislocated hips after subtrochanteric transverse shortening osteotomy fixed axially and rotationally by the cementless femoral stem and acetabular component placed into the anatomical place.

## Materials and Methods

We evaluated results of fifty hips undergoing primary cementless total hip arthroplasty in twenty-eight patients having Crowe 4 (Hartofilakidis type 3) high dislocations. The arthroplasty was achieved with subtrocanteric transverse shortening osteotomy fixed with Zweymüller femoral stem (SL plus) without any additional fixation instruments and placement of the acetabular component at the level of anatomic hip center. Twenty-two patients were operated bilaterally. In bilateral cases, interval between first operation and second operation was minimum 3 months. Twelve patients had previous pelvic, periacetabuler and femoral osteotomies. The type and size of the prosthesis was determined by using templates on 1:1 scale X-rays before the operation. Trilogy acetabular system and alloclassic zweymüller femoral stems (Zimmer, Warsaw, IN), Biomet Exceed ABT acetabular cups (Warsaw, IN) and PPF femoral stems (Warsaw, IN) were used in patients undergoing primary cementless total hip arthroplasty. We usually preferred to use tapered designs to achieve proximal stability with rectangular shape.

The direct anterolateral approach was performed in supine position for all patients. Reaming was performed according to the antero-posterior diameter of the acetabulum. In cases where the superior segmental defect affected the stability of the cup, grafts obtained from the femoral head were used in order to fill the defect. In all cases, subtrochanteric transverse shortening osteotomy was performed, and length of the resection was calculated by the vertical distance between teardrop lines drawn through the edge of teardrops on preoperative AP X-rays and applied intraoperatively according to the measured length (Figure 1).

Since the best bone stock was present in the posterior acetabulum, we started to ream the acetabulum towards to posterior aspect with small reamer sizes such as 36 mm and 38 mm, and then reamer size was increased consecutively. The stability of cementless acetabuler cup was supported with 2 or 3 screws which are applied to superior-posterior of the Wasielewski Quadrant. The femoral stem was applied from proximal to distal part of the femur and press-fit stabilization was achieved (Figure 2). In order to receive adequate femoral stability, distal fixation was reamerized more than two times the diameter of the distal Osteotomy site, which usually corresponded to the femoral isthmus. Stability of the Osteotomy site was secured through cross-sectional geometry of the rectangular square femoral stem.

Preoperative two grams cefazolin was used for all patients and antibiotic prophylaxis was continued for 24 h. Antiembolic stockings and Low Molecular Weight Heparin (LMWH) was used for deep venous thrombosis prophylaxis and administered for 30 days. Hemovac drain was withdrawn within 24 h. The patients are instructed to perform partial weight bearing with walker for at least 6 weeks. If no problem was seen at the first follow-up, which was at 6 weeks, the patients were released to full weight bearing. Follow-up was done routinely at the 6$^{th}$ week as well as the 3$^{rd}$, 6$^{rd}$ and 12$^{th}$ months and the annually afterwards.

The postoperative and preoperative Harris Hip Scores (HHS) were calculated for each patient. The postoperative HHS scores calculated at the final follow up. Scores calculated on the www.orthopaedicscores.com and saved. Scores were evaluated as excellent (90-100), good (80-89), fair (70-79) and poor (<70). Post operative standing AP and lateral X-rays of the patient's hip were taken and the independent observer evaluated these images.

## Statistical Analysis

Statistical analyses were performed using the SPSS v.15 for Windows (SPSS Inc., Chicago, IL, USA). The variables were investigated using visual (histograms, probability plots) and analytical methods (Kolmogorov-Simirnov/Shapiro-Wilk test) to determine whether or not they are normally distributed. Descriptive analyses were presented using means and stand art deviations for normally distributed variables (preop and postop Harris Hip Scores). Paired Student's t-test was used to compare the measurements at two time points (preop and postop 12 months) for HHS. A p-value of less than 0.05 was considered to show a statistically significant result.

## Results

Twenty-eight patients (50 hips) were followed for a mean of 94.5 month (72-117 month) after surgery. Statistically significant difference was found between preoperative and postoperative HHS respectively, 82.8 and 24.03 ($p<0.05$). Excellent results (90-100) were achieved in 11 hips, while good (80-89), fair (70-79), and poor results (<70) were obtained in 23.13 and 3 hips, respectively. Excellent and good results were achieved in 68% of the 50 hips. Shortening with sub-trochanteric transverse osteotomy was performed in all 50 hips. All cases required femoral shortening, because the vertical length between inter teardrop line and center of the rotation of the hip was more than 2 cm in all hips. The mean shortening length was 3 cm (range 2 cm to 4 cm). Final limb length discrepancies were corrected in all patients. Nonunion was not seen at the femoral transverse osteotomy site. Any femoral aseptic loosening was not observed in follow-up period.

Various complications seen in 10 of 50 hips (Table 1). Intraoperative femoral fractures were seen in three hips. One of them on the proximal part (trochanteric site) and the other two on the distal femur. All were fixed with cerclage and cable wires and no further

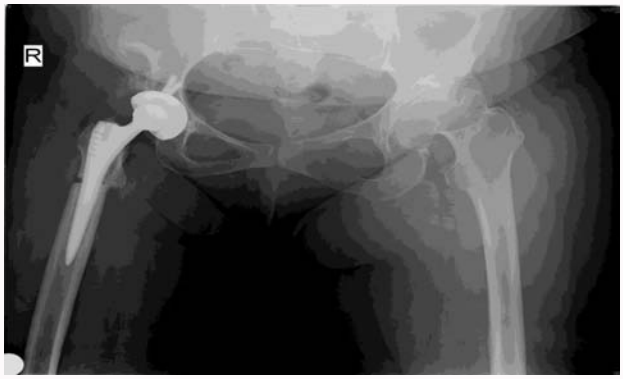

**Figure 2A:** Postoperative X-ray of the patient. The acetabulum was replaced in the anatomic position and rotational stability was achieved by rectangular design of the femoral stem.

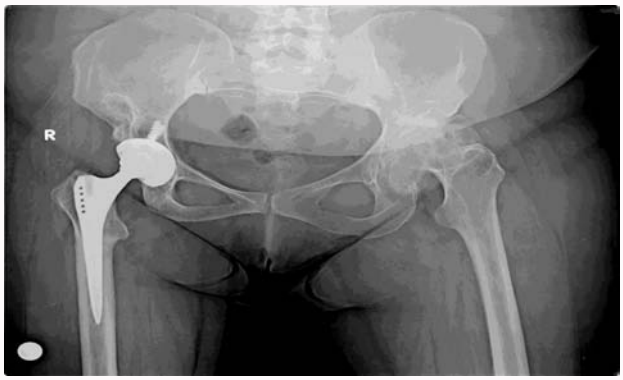

**Figure 2B:** The X-ray of the same patient after 11 years follow-up. Note complete union with well fixed components.

complications were seen. Heterotopic ossification was seen in three hips. Revision surgery was performed to one patient for acetabular component loosening.

## Discussion

THA is not only the most commonly performed operation but also the most effective operation for Crowe 4 (Hartofilakidis type 3) high dislocation in adult patients having coxarthrosis associated with DDH [10]. Porous coated, and press-fit acetabular cup was applied to the true acetabulum in each patient having coxarthrosis in our study. In the literature, it is reported that aseptic loosening occurs less frequently and better fixation is achieved in porous-coated components placed with the press-fit method [11]. In addition to this, a 15-year follow-up showed that the rate of loosening of the acetabular component placed at the true acetabulum site was 13% compared with 42% when it was placed proximal to the roof of the true acetabulum. Second, greater bone stock at the site of the true acetabulum provides better coverage than at the site of the false acetabulum. Additionally, a more stable acetabular component can be used. Third, this site restores normal hip biomechanics and abductor function, and improves the limb-length discrepancy [12].

In our study the HHS improved from 24.03 preoperatively to 82.88 postoperatively. Our results show compatibility with the results in the literature. According to Ozan et al. in 32 hips (25 patients), HHS improved from 49 (25-72) to 87 (74-94) postoperatively. In a study by Sofu et al. [10] in 73 hips (68 patients), HHS improved from 38.6 (± 2.9) preoperatively to 83.7 (± 6.8) postoperatively. Lastly, in a study by Desteli et al., in 60 hips (52 patients), HHS improved from 39 (25-60) preoperatively to 93 (80-100) postoperatively. In all three studies, type of DDH was 3 and 4 and all of the authors performed subtrochanteric femoral transverse osteotomy with cementless system [13].

**Table 1:** Summary of the complications.

| | No of hips ( n=10) |
|---|---|
| Acetabular component aseptic loosening | 1 |
| Dislocation | 2 |
| Intraoperative Femoral Fracture | 3 |
| Sciatic neurapraxic | 1 |
| Heterotopic Ossification | 3 |

According to the survival rates, literature shows better outcomes for cementless prostheses. Perka et al. reported that, in 9.3 years follow up, survival rate for the acetabular component is 97.5% and for the femoral stem is 100%. However, polyethylene wear causing aseptic loosening was the major mechanism of prosthetic failure in their study [14]. Another long-term follow-up study showed that the 14-year survivorship analysis of cementless THA with a third-generation ceramic-on-ceramic bearing surface was 97.9% for the cup, 97.8% for the stem, and 95.7% for the overall implants [15]. In another literature, Linde et al. [16] found that the rate of mechanical loosening of the acetabular cup was 13% in the group with the anatomical position of acetabular components compared with 42% in the group with superior placement of the acetabular cups at 15 years follow-up, and the difference revealed significance [16]. According to Wang et al., in 56 hips, only 2 hips showed acetabular component loosening (3.5%) due to acetabular fracture and screw breakage [13].

There are several shortening osteotomies described for the femur to avoid neurologic deficits in patients having coxarthrosis associated with DDH [17,18]. Subtrochanteric osteotomies can be performed as a transverse, an oblique, a step-cut or a chevron type [19,20]. A biomechanical study by Muratli et al. [21] compared four different subtrochanteric osteotomies techniques, and demonstrated that there was no single inherent feature increasing the stability of the osteotomy designs [21]. Trochanteric osteotomy is especially recommended for hips with high dislocation. It provides better and safer exposure as well as reconstruction of both acetabulum and femur. In the literature, transverse osteotomy may be recommended compared with other techniques due to technical simplicity, convenience of adjusting the anteversion angle, correction of the rotational deformity, preservation of the proximal femoral metaphysis, relatively short learning curve for precise performance and minimal damage of the periosteum in patients with severe DDH [20,22]. Therefore, we preferred subtrochanteric transverse osteotomy for hips with high dislocation. Abductor muscles and the trochanter major are not damaged in the transverse subtrochanteric osteotomy method.

In this study, rotational stability was provided by means of cementless rectangular cross-section prosthesis. Researchers have been trying to enhance the rotational stability of Osteotomy, in order to improve bone union. Meanwhile, additional remarks should be made that rotational stability is influenced by not only the method of Osteotomy, but also the design of implant used. Götze et al. [23] reported that the rotational stability would be secured by cross-sectional geometry of the stem design. Cross section and coating of femoral prostheses vary due to different designs. More importantly,

press-fit femoral stem used in cementless THA mainly rely on proximal fixation, which might be insufficient to provide favorable stability for Subtrochanteric osteotomy, for Subtrochanteric Osteotomy itself require stable fixation of both proximal and distal femur, on metaphysis and diaphysis, respectively [24]. In recent years, some researchers applied modular femoral stem to these patients and there were few reports on nonunion among them [22]. Due to its distinctive design, modular stem guarantees both proximal and distal fixation, and thus has potential advantages in providing rotational stability for subtrochanteric osteotomy. Despite not using a modular femoral stem, the osteotomy site healed within the eight weeks without any complications in our cases.

We used the direct lateral approach in all of our patients. This was first described by Hardinge in 1982 [25]. This approach requires bisection of the anterior half of the periosteum overlying the greater trochanter and reflection of the gluteus medius and minimus muscles. The superior gluteal nerve and artery are at risk if the approach is extended proximally. The advantage of this approach is that it can be extended distally for greater exposure of the femur where necessary and theoretically has a lower dislocation risk than the posterior approach [26].

Complications occurred in 10 (20%) of the 50 hips in our study. In DDH, the femoral stem placement has some difficulties because of the narrow femoral canal, extreme distortion and ante version [27]. The incidence of intraoperative femoral fracture ranges from 2.95% to 27.8% with cementless femoral components in primary THA [21,28,29]. Perka et al. [14] treated 121 DDH with zweymuller stems and the incidence of intraoperative fracture was 8%, however it was noticed that the intraoperative fracture did not affect the clinical outcome. Intraoperative femoral fractures were seen in three (6%) hips in our series. These fractures were fixated with cables and successful results were seen during postoperative follows-ups. The low incidence of intraoperative fracture in our study was seen because of careful preoperative planning. It is also suggested that the cup should be placed in the anatomic level in order to provide stable fixation in the acetabular component, maintain the abduction strength and equalize the leg lengths [30,31]. Sciatic palsy occurred in 1 patient on whom subtrochanteric osteotomy was performed. This patient was followed up with physiotherapy and neurologic recovery was seen after 6 months. It was reported that elongation should be limited less than 4 cm in order to prevent neurologic complications [11]. However, Eggli et al. [32] reported that there was not any relation between the amount of elongation and nerve injury incidence, and neuronal damage mainly occurred due to direct or indirect mechanical trauma [32]. In our case, sciatic palsy occurred although excessive elongation was not performed. In order to lessen sciatic nerve tension, we keep both hip and knee at the flexed position postoperatively.

One of the common complications of the transverse femoral osteotomy is nonunion. Union rates were reported between 86% and 100% in literature [33,34]. In a retrospective study performed by Wang et al. [13], in 56 hips (49 patients), union rate in osteotomy site were 96.4% [13]. We didn't detect any nonunion at subtrochanteric osteotomy site and aseptic femoral loosening in follow-up period.

## Conclusion

Subtrochanteric shortening osteotomy and cementless total hip arthroplasty for the treatment of developmental dysplasia and dislocations of the hip were associated with high successful rates for both fixation of femoral and acetabular components and Harris Hip Scores. The osteotomy site healed excellent without any complications.

## References


1. Marcel K, Moussa H, Luc K. Total hip Arthroplasty for Crowe type 4 developmental hip dysplasia, a long-term follow-up study. J Arthroplasty. 2001;16(Supl 1):170-6.
2. Park MS, Kim KH, Jeong WC. Transverse Subtrochanteric Shortening Osteotomy in Primary Total Hip Arthroplasty for Patients with Severe Hip Developmental Dysplasia. J Arthroplasty. 2007;22(7):1031-6.
3. Papachristou G, Hatzigrigoris P, Panousis K, Plessas S, Sourlas J, Levidiotis C, et al. Total hip arthroplasty for developmental hip dysplasia. Int Orthop. 2006;30(1):21-5.
4. Charley J, Feagin JA. Low friction arthroplasty in congenital subluxation of the hip. Clin Orthop Relat Res.1973;(91):98-113.
5. Crowe JF, Mani VJ, Ranawat CS. Total hip replacement in congenital dysplasia and dislocation of the hip. JBJS. 1979;61(1):15-23.
6. Delee JF, Charnley J. Radiological demarcation of cemented sockets in total hip replacement. Clin Orthop Relat Res.1976;12(1):20-32.
7. Dunn HK, Hess WH. Total hip reconstruction in chronically dislocated hips. J Bone Joint Surg Am. 1976;58(6):838-45.
8. Jawad MU, Scully SP. In Brief Crowe's Classification Arthroplasty in Developmental Dysplasia of the Hip. Clin Orthop Relat Res. 2011;469(1):306-8.
9. Klisić P, Janković L, Basara V. Long term results of combined operative reduction of the hip in older children. J Pediatr Orthop. 1988;8(5):532-4.
10. Sofu H, Ahin VS, Gürsu S, Yildirim T, Issin A, Koçkara N. Cementless total hip arthroplasty in patients with Crowe type-4 developmental dysplasia. Hip Int. 2013;23(5):472-7.
11. Eskelinen A, Helenius I, Remes V, Ylinen P, Tallroth K, Paavilainen T. Cementless total hip arthroplasty in patients with high congenital hip dislocation. J Bone Joint Surg Am. 2006;88(1):80-9.
12. Luo Z, Chen M, Hu F, Ni Z, Ji X, Zhang X, et al. Cementless total hip arthroplasty with extended sliding trochanteric osteotomy for high congenital hip dislocation. A retrospective study. Medicine (Baltimore). 2017;96(14):e6581.
13. Wang D, Li D-H, Li Q, Wang H-Y, Luo Z-Y, Yang Y, et al. Subtrochanteric Shortening Osteotomy During Cementless Total Hip Arthroplasty in Young Patients with Severe Developmental Dysplasia of the Hip. BMC Musculoskelet Disord. 2017;18(1):491.
14. Perka C, Fischer U, Taylor WR, Matziolis G. Developmental hip dysplasia treated with total hip arthroplasty with a straight stem and a threaded cup. J Bone Joint Surg Am. 2004;86(2):312-9.
15. Sugano N, Takao M, Sakai T, Nishii T, Miki H, Ohzono K. Eleven-to 14-year follow-up results of cementless total hip arthroplasty using a third-generation alumina ceramic-on-ceramic bearing. J Arthroplasty. 2012;27(5):736-41.
16. Linde F, Jensen J, Pilgaard S. Charnley arthroplasty in osteoarthritis secondary to congenital dislocation or subluxation of the hip. Clin Orthop Relat Res. 1988;227:164-71.
17. Daniel N, Christoph T, Ulrich D. Femoral shortening and cementless arthroplasty in Crowe type 4 congenital dislocation of the hip. Int Orthop. 2012; 36(3):499-503.
18. Bao NR, Meng J, Zhou LW, Guo T, Zeng X, Zhao J. Lesser trochanteric osteotomy in total hip arthroplasty for treating CROWE type IV developmental dysplasia of hip. Int Orthop. 2013;37(3):385-90.
19. Kiliçoğlu Oİ, Türker M, Akgül T, Yazicioğlu O. Cementless total hip arthroplasty with modified oblique femoral shortening osteotomy in

Crowe Type IV congenital hip dislocation. J Arthroplasty. 2013;28(1):117-25.

20. Sofu H, Kockara N, Gursu S, Issin A, Oner A, Sahin V. Tranverse subtrochanteric shortening osteotomy during cementless total hip arthroplasty in Crown type-III or IV developmental dysplasia. J Arthroplasty. 2015;30(6):1019-23.

21. Muratli KS, Karatosun V, Uzun B, Celik S. Subtrochanteric shortening in total hip arthroplasty: biomechanical comparison of four techniques. J Arthroplasty. 2014;29(4):836-42.

22. Li C, Zhang C, Zhang M, Ding Y. Comparison of transverse and modified subtrochanteric femoral shortening osteotomy in total hip arthroplasty for developmental dysplasia of hip: a meta-analysis. BMC Musculoskelet Disord. 2014;15:331.

23. Götze C, Winkelmann W, Gosheger G, Rödl R. Is there a need of an additional extramedullary fixation in transverse subtrochanteric shortening in primary total hip arthroplasty for patients with severe hip dysplasia? Short-term experience in seven patients with congenital dislocation. Z Orthop Unfall. 2007;145(5):568-73.

24. Takao M, Ohzono K, Nishii T, Miki H, Nakamura N, Sugano N. Cementless modular total hip arthroplasty with subtrochanteric shortening osteotomy for hips with developmental dysplasia. J Bone Joint Surg Am. 2011;93(6):548-55.

25. Hardinge K. The direct lateral approach to the hip. J Bone Joint Surg Br. 1982;64(1):17-9.

26. Talia AJ, Coetzee C, Tirosh O, Tran P. Comparison of Outcome Measures and Complication Rates Following Three Different Approaches for Primary Total Hip Arthroplasty: A Pragmatic Randomised Controlled Trial. Trials. 2018;19(1):13.

27. Hartofilakidis G, Stamos K, Karachalios T. Treatment of high dislocation of the hip in adults with total hip arthroplasty. Operative technique and long-term clinical results. J Bone Joint Surg Am. 1998;80(4):510-7.

28. Queen RM, Appleton JS, Butler RJ, Newman ET, Kelley SS, Attarian DE, et al. Total Hip Arthroplasty surgical approach does not alter postoperative gait mechanics one year after surgery. PM R. 2014;6(3):221-6.

29. Jensen JS, Retpen JB. Failures with the Judet noncemented total hip. Acta Orthop Scand. 1987;58(1):23-6.

30. Yoder SA, Brand RA, Pedersen DR, O'Gorman TW. Total hip acetabular component posi on a ects component loosening rates. Clin Orthop Relat Res. 1988;(228):79-87.

31. Pagnano W, Hanssen AD, Lewallen DG, Shaughnessy WJ. The effect of superior placement of the acetabular component on the rate of loosening a er total hip arthroplasty. J Bone Joint Surg Am. 1996;78(7):1004-14.

32. Eggli S, Hankemayer S, Müller ME. Nerve palsy after leg lengthening in total replacement arthroplasty for developmental dysplasia of the hip. J Bone Joint Surg Br. 1999;81(5)843-5.

33. Krych AJ, Howard JL, Trousdale RT, CAbanela ME, Berry DJ. Total hip arthroplasty with shortening subtrochanteric osteotomy in Crowe type-IV developmental dysplasia. J Bone Joint Surg Am. 2010;92(Suppl 1 Pt 2):176-87.

34. Erdemli B, Yılmaz C, Atalar H, Güzel B, Cetin I. Total hip arthroplasty in developmental high dislocation of the hip. J Arthroplasty. 2005;20(8):1021-8.