



## Case Report: A Rare Case of Extensive Subcutaneous Emphysema from Extra-Peritoneal Rectal Injury in a Patient with Unstable Pelvic Fracture

Segni Kejela\*

Department of Surgery, Tikur Anbessa Specialized Hospital, Addis Ababa University, Ethiopia

### Abstract

**Background:** Pelvic injuries and its associated pelvic organ injuries are not rare, but extensive subcutaneous emphysema from extra-peritoneal rectal injury is; especially in trauma scenarios.

**Case Description:** Our case is a 16 years old male patient presented after a fall accident from a moving vehicle sustaining unstable Tile C pelvic fracture with hemorrhagic shock, extra-peritoneal bladder and rectal injury with extensive subcutaneous emphysema. The patient was investigated with X-ray and CT scan imaging and resuscitated with crystalloids and blood products. He succumbed at the emergency department after significant delay for operative management decision and preparation.

**Conclusion:** This is truly a diagnosis that should have been made intraoperatively and no delay should have occurred for any diagnostic modality in such patient in extremis.

**Keywords:** Subcutaneous emphysema; Rectal injury; Unstable pelvic fracture

### Abbreviations

CBC: Complete Blood Count; CT: Computed Tomography; Hgb: Hemoglobin

### Introduction

Pelvic injuries are common scenarios in trauma surgery [1]. Associated injuries of pelvic organs are not that rare in the medical literatures [2]. But the occurrence of extra-peritoneal rectal injuries with extensive subcutaneous emphysema is sparse. Here we present a case of unstable pelvic fracture with extra-peritoneal bladder and rectal injury with extensive subcutaneous emphysema presented in hemorrhagic shock.

### Case Presentation

This is a 16 years old male presented 16 h from a regional hospital 320 km away after sustaining trauma after he fall accident from a moving pick up truck. He landed on his buttock followed by his lower limb and back. He had bleeding from perineal area with intense pelvic area pain immediately and didn't lose any consciousness. He was taken to the referring hospital and at presentation, he was complaining pain on the back and pelvic area with referral paper stating, tachycardia of 110/min and tachypnea of 26/min and blood pressure was maintained at 100/60 mmHg. He was transfused with 4 units of cross-matched blood (initial Hemoglobin from referral, 3.3 g/dl and 3 liters of normal saline) and he was referred 8 h post injury. Upon transfer of the patient, the patient started to complain shortness of breath and he lost consciousness and he arrived at 4 am on duty hours. Upon arrival, the patient had intact airway and the emergency team applied Philadelphia neck collar. On breathing, Kussmaul breathing pattern with rate at 26 breaths/min. resonant chest and vesicular breath sound, oxygen saturation of 92% with atmospheric air. He was put on intranasal oxygen at 5L/min. On Circulation, cold extremities, feeble pulse and delayed capillary refill time, Initial blood pressure 60/30 mmHg, minimal bleeding from perineal areas. No abdomen distention but Pelvic instability was detected and pelvic binder was applied. Bilateral Intravenous (IV) lines were secured and initial 1 liter of crystalloid was given and cross-match blood sample sent. The 4 lead cardiac and non invasive blood pressure measurement monitor was applied. Patient was catheterized with 600 ml frank blood as output. Disability, pupils were reactive bilaterally, intact cremasteric reflex and patient moves all extremities on painful stimulus, GCS 8/15 (E3 V2 M3). The patient was exposed and had a degloved perineal wound involving the scrotum with minimal bleeding

### OPEN ACCESS

#### \*Correspondence:

Segni Kejela, Department of Surgery,  
Tikur Anbessa Specialized Hospital,  
Addis Ababa University, College  
of Health Sciences, Ethiopia, Tel:  
+251917083212;

E-mail: [segnikejo@gmail.com](mailto:segnikejo@gmail.com)

Received Date: 28 Feb 2020

Accepted Date: 19 Mar 2020

Published Date: 23 Mar 2020

#### Citation:

Kejela S. Case Report: A Rare Case of  
Extensive Subcutaneous Emphysema  
from Extra-Peritoneal Rectal Injury in a  
Patient with Unstable Pelvic Fracture.  
*Ann Trauma Acute Care.* 2020; 4(1):  
1019.

**Copyright** © 2020 Segni Kejela. This is  
an open access article distributed under  
the Creative Commons Attribution  
License, which permits unrestricted  
use, distribution, and reproduction in  
any medium, provided the original work  
is properly cited.

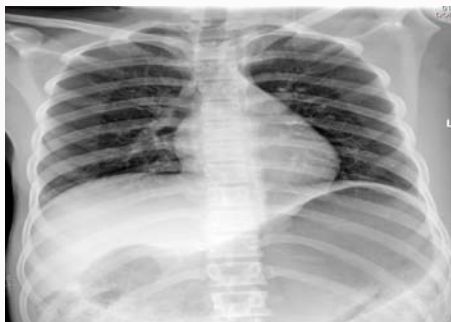

Figure 1: Supine Chest X-ray of the patient at presentation.

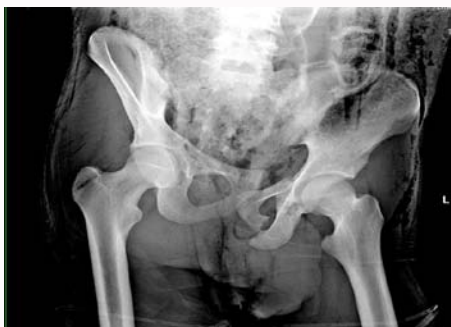

Figure 2: Anteroposterior pelvic X-ray of the patient at presentation.

and extensive crepitations all over the back and gluteal area up to the nape. Digital rectal examination showed palpable urinary catheter balloon in the cul-de-sac, bright red blood on examining finger. The 30 min after presentation, the blood pressure had no improvement and another 1 liter of crystalloid was administered and trauma series imaging with clear chest X-ray, pelvic X-ray showing vertical shear Tile C fracture as shown below, fast examination showing no fluid collection in the peritoneal cavity and CBC was done and showed Hgb of 6.3 g/dl, Platelet 120,000/microliter (Figure 1 and 2). The findings elicited the emergency team to consult the orthopedic team and decision was made for CT scanning of the pelvis. CT scans of the head, the spine, abdomen and pelvis of the patient opportunistically. After imaging and 4 h after arrival general surgery team was consulted. After imaging, extensive subcutaneous emphysema, unstable pelvic fracture, hemorrhagic shock secondary to Zone III retroperitoneal injury, extra-peritoneal urinary bladder injury rectal injury and thoracolumbar compression fracture was entertained. The subcutaneous emphysema was tracked for source and extra-peritoneal rectal injury was the only source found both clinically and radiology. There was no head or neck injury (Figure 3 and 4). No arterial blood gas, coagulation profile, Thromboelastography (TEG), base deficit or lactate level was done because of unavailability. Decision was made for damage control pelvic surgery by orthopedic and general surgery team and resuscitation was continued with 3 units of blood and 2 units of platelet (plasma was not available). And in the mean time, skeletal traction with distal femoral pin was done in an attempt to decrease pelvic cavity volume. Unfortunately, logistics further delayed preparation of operating table, and the patient kept on fluid resuscitation for further 4 h with additional 4 L of normal saline and additional 6 units of packed red cells, and platelets were ordered (no massive transfusion protocol in Ethiopia). The 8 h after presentation, 4 h after surgical consultation was made; the patient succumbed from cardiac arrest secondary to hemorrhagic shock at

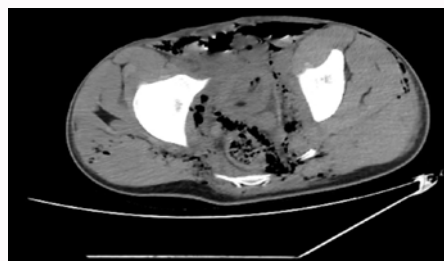


Figure 3: Axial Pelvic non contrast CT scan showing pelvic subcutaneous emphysema with extra-peritoneal rectal wall disruption.

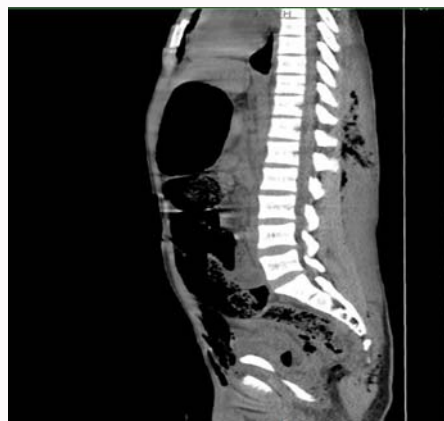

Figure 4: Non contrast CT with Sagittal reconstruction thoraco-lumbar compression fracture.

emergency unit.

## Discussion

Trauma in Ethiopia is a major cause of morbidity and mortality [3]. Facilities capable of managing such complex trauma cases are quite few, in fact located only in the capital, Addis Ababa (Tikur Anbessa Specialized Hospital, and Addis Ababa Burn, Emergency and Trauma Hospital). This may have led significant overload on the two hospitals in managing all severely injured patients. Rectal injury is found in only 1% to 2% of patients with pelvic fracture [4]. Subcutaneous emphysema is quite a rare entity in medical literatures. Traumatic rectal injury induced subcutaneous emphysema was first reported in Borgstrom in 1953 stating extra-peritoneal rectal perforation could cause air accumulation in retroperitoneal space and could mimic intra-peritoneal air [5]. The most report of recent traumatic rectal injury with subcutaneous emphysema, excluding iatrogenic, was a case of an 8 year old child sustaining straddle injury after falling from height for which diversion sigmoid colostomy was done and the patient had uneventful postoperative course [6]. Even though it is certainly intriguing to diagnose extra-peritoneal injury with extensive subcutaneous emphysema, the diagnosis itself should be regarded as a failure in the proper management of the patient. As insightfully described by Kam et al., CT scan is indeed death tunnel for patient with pelvic fracture in extremis and certainly doesn't add any benefit to the initial life saving measure intended [7]. In the same article, 10 commandments exsanguinating pelvic fracture management, it was stated that, for such patients, transfusion is only a temporizing measure and damage control orthopedics/surgery should be mandated [7]. Finally, we felt it is important to note the following probable errors in the management of this particular

case. A suboptimal resuscitation during transportation and after arrival, failure to recognize the need for abbreviated surgery earlier, inappropriate utilization of resources and delayed consultation of a surgical team have been acknowledged.

## References

1. Hauschild O, Strohm PC, Culemann U, Pohlemann T, Suedkamp NP, Kostler W, et al. Mortality in patients with pelvic fractures: Results from the German pelvic injury register. *J Trauma*. 2008;64(2):449-55.
2. Demetriades D, Karaiskakis M, Toutouzas K, Alo K, Velmahos G, Chan L. Pelvic fractures: epidemiology and predictors of associated abdominal injuries and outcomes. *J Am Coll Surg*. 2002;195(1):1-10.
3. Misganaw A, Haregu TN, Deribe K, Tessema GA, Deribew A, Melaku YA, et al. National mortality burden due to communicable, non-communicable, and other diseases in Ethiopia, 1990-2015: Findings from the global burden of disease study 2015. *Population Health Metrics*. 2017;15(29):1-17.
4. Gwak J, Lee MA, Yu B, Choi KK. Rectal injury associated with pelvic fracture. *J Korean Soc Traumatol*. 2016;29(4):201-3.
5. Borgstrom S. Subcutaneous emphysema following rectal perforation. *Acta Chir Scand*. 1953;104:465.
6. Kam CW, Law PKJ, Lau HWJ, Ahmad R, Tse CLJ, Cheng M, et al. The 10 commandments of exsanguinating pelvic fracture management. *Hong Kong J Emerg Med*. 2019;26(6):357-70.
7. Thomas PRS. Ano-rectal injury causing extraperitoneal and subcutaneous emphysema. *Injury*. 1987;18(6):426-7.