



# Carotid Body Tumor Associated with Papillary Thyroid Carcinoma

Luis PO<sup>\*1</sup>, Martínez JA<sup>2</sup> and Ayala OA<sup>3</sup>

<sup>1</sup>Department of Head and Neck Surgery, Hospital Vozandes Quito, Ecuador

<sup>2</sup>Department of Endocrinology, Hospital Carlos Andrade Marín, Ecuador

<sup>3</sup>Department of General Surgery, Hospital Vozandes Quito, Ecuador

## Abstract

**Introduction:** Carotid Body Tumors (CBT) are rare benign neoplasms of neural crest origin located at carotid bifurcation. They are more common at high altitudes. On the other hand, incidence of Papillary Thyroid Cancer (PTC) is steadily rising in the whole world. We report a small series of patients who presented a CBT associated with PTC simultaneously or at different times.

**Materials and Methods:** Among 255 clinically diagnosed CBT, 230, arising in 217 patients (13 bilateral), were operated in Quito, Ecuador. In 13 (6%) cases, a malignancy at other localization was found. A PTC was treated surgically in 8 of them, 3 previously, and 3 after the CBT surgery and 2 simultaneously.

**Results:** There were no postoperative complications. Median follow up was of 66 months after CBT surgery and 66 months for thyroid cancer surgery. One patient died for malignant local recurrence and pulmonary metastasis of a CBT. No recurrence of PTC occurred in any patient.

**Conclusion:** Association of CBT and PTC is very uncommon but it could be expected to occur less rarely in regions where both lesions have higher incidence. If they are present simultaneously an adequate and complete surgical procedure for both lesions can be performed without morbidity.

**Keywords:** Carotid Body Tumors; Papillary Thyroid Carcinoma; Second primary malignancy

## Introduction

Carotid Body Tumors (CBT) are rare neoplasm's with greater incidence in high altitude regions [1]. They are located in the adventitia, poster medially to the bifurcation of the common carotid artery and arise from embryonic neuroepithelium. They are asymptomatic, slowly growing, hypervascularized, laterally mobile neck masses, under the angle of the jaw. They occur more frequently in female patients in the fourth to sixth decades of life. Doppler ultrasound and angio-CT offer practically a 100% of certain diagnosis [2]. Surgical resection is the treatment of choice with a low morbidity rate and no mortality. On the other hand, a sustained increasing incidence of Papillary Thyroid Carcinomas (PTC) has been reported in both developed and developing countries such as Ecuador [3]. PTC is currently diagnosed by Fine Needle Aspiration Biopsy (FNAB) of a suspicious non-palpable thyroid nodule found in an ultrasound examination of an asymptomatic patient. In approximately 20% of cases, a PTC can appear with clinically lateral neck lymph nodes [4,5]. If these nodes are located in levels II and III an independent or associated carotid body tumor should occasionally be ruled out. The aim of this study was to review our clinical experience in the diagnosis and surgical management of patients with a CBT associated to PTC.

## Methods and Materials

The clinical records of all the patients with CBT and those with PTC surgically treated at the Social Security Hospital "Carlos Andrade Marín" in Quito, Ecuador, South America, during a 35-year period were retrospectively reviewed. All of them had histologic diagnosis of paraganglioma and differentiated papillary thyroid carcinoma. Among 255 clinically diagnosed CBT, 230, arising in 217 patients (13 bilateral), were operated on in Quito, Ecuador. In 13 (65%) of these CBT operated patients, a malignancy in other localization was found and in 8 of them this malignancy was a differentiated PTC. These thyroid tumors were operated, before the CBT surgery in 3 cases, afterwards in 3 cases or at the same time in 2 cases. Seven patients were female (87%) and mean age at the time of CBT surgery was 47.4 (35 to 63) years. Demographics, clinical stage of PTC,

## OPEN ACCESS

### \*Correspondence:

Luis Pacheco-Ojeda, Department of Head and Neck Surgery, Hospital Vozandes Quito, Quito 170150, Ecuador;

E-mail: [luispacheco.o@hotmail.com](mailto:luispacheco.o@hotmail.com)

**Received Date:** 30 Mar 2020

**Accepted Date:** 14 Apr 2020

**Published Date:** 16 Apr 2020

### Citation:

Luis PO, Martínez JA, Ayala OA. Carotid Body Tumor Associated with Papillary Thyroid Carcinoma. *Am J Otolaryngol Head Neck Surg.* 2020; 3(2): 1089.

**Copyright** © 2020 Luis PO. This is an open access article distributed under the Creative Commons Attribution License, which permits unrestricted use, distribution, and reproduction in any medium, provided the original work is properly cited.

**Table 1:** Clinical and surgical features, and outcomes of CBT.

Carotid body tumors: 8/217 patients (3.7%)	
Imaging diagnosis	
Ultrasound	6
Angio-CT	5
Angio-MRI	1
Shamblin Classification	
I	3
II	3
III	2
Perioperative vascular accident	1
Blood transfusion	0
Complications	0
Mean follow up	60 months
Clinical condition	
No evidence of disease	5
Local recurrence	2
Death with metastases	1

\*CBT: Carotid Body Tumor; Angio-CT: Angio Computed Tomography; Angio-MRI: Angio Magnetic Resonance Imaging.

Shambling type of CBT, surgical procedures and outcomes appear on Table 1, 2.

Among the two patients operated on simultaneously, one had a clinical diagnosis of a 9 cm lateral neck cyst (probably branchial cyst) associated with a homolateral CBT. Both lesions were removed through a lateral neck incision and the pathological study reported a papillary cystic thyroid carcinoma within a branchial cyst with no extracapsular extension; a total thyroidectomy was performed two months later and no tumor was found in the at the pathological study; after a follow up of 7 years no evidence of recurrence has been found. For the second patient, the senior author (L.P-O) was called

**Table 2:** Clinical and surgical features, and outcomes of PTC.

Papillary thyroid carcinoma: 8/896 patients (0.9%)	
Diagnosis time*	
Previous	3
Simultaneous	2
Subsequent	3
TNM stage	
I	7
II	1
Type of surgery	
TT	2
TT + CND	3
TT + CND + LND	2
TT + ETR	1
Mean follow up	66 months
Clinical condition:	
No evidence of disease	8**

\*In relation to CBT surgery, \*\* No evidence of PTC but one patient dead for metastatic CBT

PTC: Papillary Thyroid Carcinoma; TT: Total Thyroidectomy; CND: Central Node Dissection; LND: Lateral Node Dissection; ETR: Ectopic Thyroid Resection

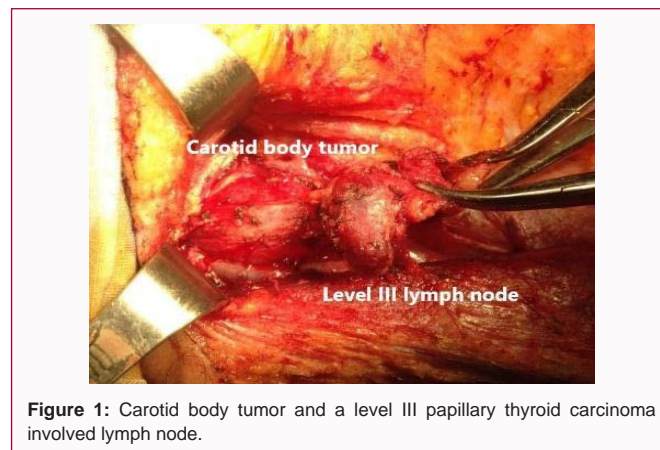
to assist a young surgeon for an operation scheduled for a thyroid carcinoma. This was a 35-year-old otherwise healthy woman who presented with right lateral asymptomatic neck mass which had appeared 12 months earlier. The only previous work up had been a neck ultrasound that reported a moderately vascularized, 2.6 cm level III right neck mass, probably a lymph node, and multinodular thyroid gland. A fine needle aspiration biopsy had reported a PTC metastatic node. Preoperatively (at the operating room), the lateral neck mass appeared slightly firm, well defined, with suspicion of a CBT. A Kocher incision extended to the right mastoid was performed. A CBT located deeper to a lymph node mass was palpated intraoperatively. After performance of levels II and III lymph node dissection, the CBT was resected according to the usual surgical technique. Two minimal (3 mm) artery disruptions were repaired with 6/0 prolene sutures. Lateral neck dissection was completed and a total thyroidectomy and right central neck dissection performed (Figures 1-3). A classical 1.5 cm PTC with 2 out of 12 positive lymph nodes were reported at pathological study. Postoperative recovery was uneventful and the patient was discharged on the third postoperative day. Adjuvant iodine therapy was administered six weeks after surgery. The patient is currently well 3 years after surgery.

**Results**

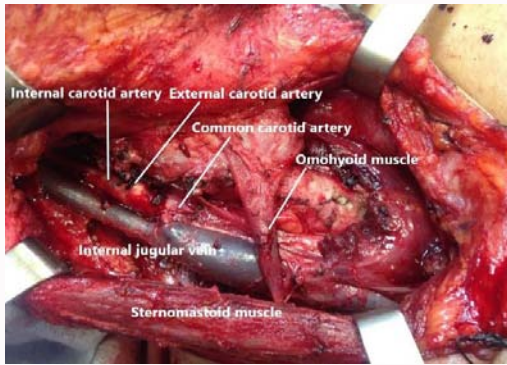
There were no postoperative complications after surgery of either type of lesions. Radioactive iodine adjuvant therapy was given to all the patients. Median follow up was of 66 months after CBT surgery and 66 months for thyroid cancer surgery. Two patients developed a small size and asymptomatic CBT recurrences that were not reoperated these patients are otherwise currently healthy. One patient died for malignant local recurrence and pulmonary metastasis of a CBT. No recurrence of PTC occurred in any of the 8 patients.

**Discussion**

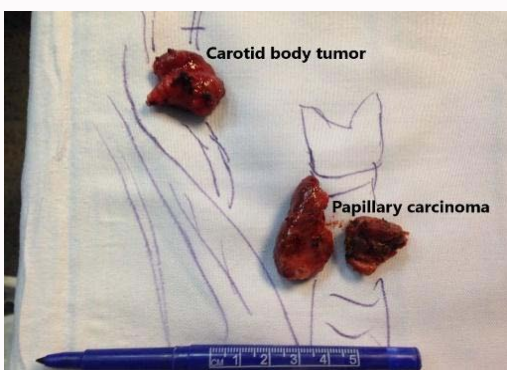
As incidence of CBT in most places in the world is very low, an additional synchronous or metachronous malignancy in the same patient could be expected to be found in extremely rare occasions. However, the frequency of the type of this additional malignancy should be related to the incidence of cancer in a given population. The incidence of CBT in the United States would be of 1/1.000.000 and 7.5/1.000.000 in Ecuador [6,7]. In this country, the Andean valleys are located over 9,000 feet above sea level. On the other hand, the incidence of thyroid cancer among females is of 22.3/100000 inhabitants in the United States, and of 15.7 in Ecuador. In this country, this malignancy is currently the most common malignancy



**Figure 1:** Carotid body tumor and a level III papillary thyroid carcinoma involved lymph node.



**Figure 2:** Surgical aspect after carotid body tumor resection, lateral neck dissection, total thyroidectomy and central node dissection.



**Figure 3:** Carotid body tumor and total thyroidectomy specimens.

in women before breast and cervix uteri cancers, and consequently, the most common malignancy of the neck [3]. Thus, the association of these two tumors is expected to be somewhat higher in Ecuador. These two types of tumors are more frequent in women: 60% to 89% of CBT [6,7] and 89% of PTC as seven of the 8 patients in this series [5].

Increased risk of Second Primary Malignancy (SPM), mainly bone, joint, and salivary gland tumors, in PTC has been reported [8]. Additionally, other malignant and benign tumors such as lymphomas, squamous cell carcinomas of the aerodigestive superior tract and parathyroid tumors can also be found occasionally in the neck. As PTC surgery is increasingly frequent, surgeons can occasionally face discovery of other neck tumors, including CBT, that could be treated simultaneously or immediately if no important additional risks and postoperative complications are expected to occur. Few studies, mostly case reports, of CBT associated with thyroid malignancies have been published in literature. Albores-Saavedra and Espino [9] published in 1968 the probably earliest report of two cases of association of CBT and PTC. One patient was operated simultaneously for both lesions and in the other, both tumors were operated separately. In 1981, Larraza-Hernandez et al. [10] reported a case of nonfunctioning pituitary adenoma, a multicentric papillary thyroid carcinoma, bilateral carotid body paragangliomas, parathyroid hyperplasia, gastric leiomyoma and systemic amyloidosis. The authors proposed for this case, a new MEN syndrome genetically determined and inherited as autosomal dominant. In 1994, Kuratomi et al. [11] reported a patient of CBT associated with a primary differentiated thyroid carcinoma, in whom, an embolization was done previously to CBT resection and total thyroidectomy. Subsequently, the patient

received radiotherapy. More recently, Hlatshwayo et al. [12] reported a case of CBT with thyroid involvement. In this report only imaging studies were presented and there were no pathological diagnoses of the carotid body and thyroid lesions. Kim et al. [13] reported a very unusual case of coexistence of CBT and a thyroglossal duct carcinoma with cervical lymph node metastasis. This patient underwent a Sistrunk type operation with radical neck dissection but the CBT was not resected. In a study of 175 patients with 224 head and neck Paragangliomas (PGL) (68 CBT), two cases of papillary thyroid carcinoma were present. One of these patients, with multiple PGL, was carrier of mutation of the Succinate Dehydrogenase (SDH) D subunit gene [14]. After review of the literature, we have not found any study of genetic association between CBT and PTC. When both a CBT and a PTC are diagnosed in different moments, surgery of these lesions can be planned and carried out as usual, according to the extent of them. In case of simultaneous diagnosis of CBT and PTC, as in two of our patients, the surgeon must be prepared to perform a technically challenging operation such as total or partial thyroidectomy, central neck dissection and lateral neck dissection, as indicated, and resection of the CBT. An adequate and complete surgical procedure can be planned and the family informed, before taking the patient to the operating room.

Postoperative complications occur in 27% of cases after CBT and are related to Shamblin type of tumors [7]. After total thyroidectomy for PTC the most remarkable complications are permanent hypoparathyroidism (1.6%) and permanent vocal cord paralysis (1.7%) [15]. Fortunately, we did not have any postoperative complications in any of our patients.

An unusual clinical situation occurred in one of the two patients who were operated simultaneously for both a CBT and PTC. In this patient, an ectopic PTC was found in a clinically diagnosed 9 cm neck cyst. Ectopic thyroid tissue seems to occur in 7% of adults, mostly along the course of thyroglossal duct [16]. Ectopic primary PTC within a branchial cyst seems to be extremely rare with only ten cases reported [17,18]. The second of these two patients were taken to the operating room with a clinical diagnosis of PTC in a lateral neck node and additionally a CBT was removed. It appears interesting to remark at this point that a homogeneously-stained mass in conventional angiography located at the carotid bifurcation mimicking a CBT may result to be a PTC at the pathologic study after resection [19].

Malignant CBT occur in approximately 3% of cases and prognosis is generally good in patients with locoregional disease but is very poor if metastasis have developed [20]. On the other hand, PTC prognosis is excellent [5]. In our series, only the patient who developed CBT pulmonary metastasis died.

## Conclusion

Association of CBT and PTC is very uncommon but it could be expected occur less rarely in regions where both lesions have higher incidence as the Andean region of Ecuador. Fortunately, both lesions can be correctly diagnosed preoperatively nowadays in most cases. If they are present simultaneously, an adequate and complete surgical procedure for both lesions can be performed without morbidity as in the current series. Prognosis is excellent for both types of tumors except in exceptional cases of malignant metastatic CBT.

## References

1. Rodríguez-Cuevas S, López J, Labastida AS. Carotid body tumors in

- inhabitants of altitudes higher than 2000 meters above sea level. *Head Neck*. 1998;20(5):374-8.
2. Pacheco-Ojeda LA, Martínez VMA. Preoperative imaging diagnosis of carotid body tumors. *Int Surg*. 2010;95(3):242-6.
  3. Bray F, Colombet M, Mery L, Piñeros M, Znaor A, Zanetti R, et al. Cancer incidence in five continents. International Agency for Research on Cancer. 2017;11.
  4. So YK, Kim MJ, Kim S, Son YI. Lateral lymph node metastasis in papillary thyroid carcinoma: A systematic review and meta-analysis for prevalence, risk factors, and location. *Int J Surg*. 2018;50(2):94-103.
  5. Ito Y, Miyauchi A, Kihara M, Fukushima M, Higashiyama T, Miya A. Overall survival of papillary thyroid carcinoma patients: A single-institution long-term follow-up of 5897 patients. *World J Surg*. 2018;42(3):615-22.
  6. Dua A, Spees T, Hernandez F, Igbadumhe AA, Algodí M, Desai SS. Trends in the incidence of carotid body tumors in the united states from 1998 to 2011. *Vasc Dis Manag*. 2014;11(12):298-302.
  7. Pacheco-Ojeda LA. Carotid body tumors: Surgical experience in 215 cases. *J Craniomaxillofac Surg*. 2017;45(9):1472-7.
  8. Endo M, Liu JB, Dougan M, Lee JS. Incidence of second malignancy in patients with papillary thyroid cancer from surveillance, epidemiology, and end results 13 dataset. *J Thyroid Res*. 2018;2018(6):8765369.
  9. Albores-Saavedra J, Espino DM. Association of thyroid carcinoma and chemodectoma. *Am J Surg*. 1968;116(12): 887-90.
  10. Larraza-Hernandez O, Albores-Saavedra J, Benavides G, Krause LG, Perez-Merizaldi JC, Ginzo A. Multiple endocrine neoplasia. Pituitary adenoma, multicentric papillary thyroid carcinoma, bilateral carotid body paraganglioma, parathyroid hyperplasia, gastric leiomyoma, and systemic amyloidosis. *Am J Clin Pathol*. 1982;78(4):527-32.
  11. Kuratomi Y, Kumamoto Y, Sakai Y, Komiyama S. Carotid body tumor associated with differentiated thyroid carcinoma. *Europ Arch Otorhinolaryngol*. 1994;251(8):91-4.
  12. Hlatshwayo B, Panicker A, Tsatsi LDR. Carotid body tumor with thyroid involvement. *IJCRI*. 2013;4(8):448-51.
  13. Kim JW, Lee SW, Hong HS, Koh ES, Choi EC, Koh YW. Coexistence of a carotid body tumor and thyroglossal duct carcinoma with cervical lymph node metastasis. *Clin Exp Otorhinolaryngol*. 2014;7(1):69-72.
  14. Papaspyrou K, Mewes T, Rossmann H, Fottner C, Schneider-Raetzke B, Bartsch O, et al. Head and neck paragangliomas: Report of 175 patients (1989-2010). *Head Neck*. 2012;34(5):632-7.
  15. Meltzer C, Hull M, Sundang A, Adams JL. Association between annual surgeon total thyroidectomy volume and transient and permanent complications. *JAMA Otolaryngol Head Neck Surg*. 2019;(7):1752.
  16. Fumarola A, Trimboli P, Cavaliere R, Coletta I, Veltri A, Di Fiore A, et al. Thyroid papillary carcinoma arising in ectopic thyroid tissue within a neck branchial cyst. *World J Surg Oncol*. 2006;4(5):24.
  17. Klubo-Gwiedzinska J, Manes RP, Chia SH, Burman KD, Stathatos NA, Deeb ZE, et al. Clinical review: Ectopic cervical thyroid carcinoma-review of the literature with illustrative case series. *J Clin Endocrinol Metab*. 2011;96(9):2684-91.
  18. Xu JJ, Kwan K, Fung K. Papillary thyroid carcinoma in a lateral neck cyst: primary of ectopic thyroid tissue versus cystic metastasis. *J Laryngol Otol*. 2013;127(7):724-7.
  19. Korkmaz O, Göksel S, Özlü H, Berkan Ö. Papillary thyroid cancer located in the carotid bifurcation mimicking carotid body tumor. *Ulus Cerrahi Derg*. 2014;31(1):52-4.
  20. Pacheco-Ojeda L. Malignant carotid body tumors: Report of three cases. *Ann Otol Rhino Laryngol*. 2001;110(1):36-40.