



## Bull Horn Injure in Neck and Face Bones: Case Report and Literature Review

Fuenmayor G Luis<sup>1</sup>, Liceaga R Rodrigo<sup>2\*</sup>, Band O Rogelio<sup>3</sup> and Bustos A Luis<sup>4</sup>

<sup>1</sup>Autonomous University of Baja California, Mexico

<sup>2</sup>Department of Maxillofacial Surgery, General Hospital of Campeche, Mexico

<sup>3</sup>Regional General Hospital No. 1 IMSS, Mexico

<sup>4</sup>Cuauhtémoc University, Mexico

### Abstract

Injuries produced by bull goring in our country are very frequent in most Ibero-American region where bullfighting shows makes these wounds more common. Such wounds maybe presented in the rural area, where these animal are used in load or drag activities, and not in bullfights. Traumatism in the maxillofacial area are less common, being the pelvic members most affected. We present a case of a 76 year old male patient, with a bull goring penetrating injury in the right cervicofacial region, during agriculture activities. An open reduction was performed with plates and screws. Intra oral approach was combined to reduce and fix zygomatic fracture to properly align the bone fractures and suturing soft tissue injure finally.

**Keywords:** Bull gorin; Facial wound; Facial trauma

### Introduction

The trend in maintaining bulls on farms for livestock production has dramatically changed over the past century. Up to the late 1940s, almost every dairy farm or beef operation owned one or more mature bulls for breeding purposes. Many farmers and ranchers also raised bulls for replacement or for sale as an additional source of income. The unpredictability of bulls plus their strength and substantial mass are significant contributors to the potential for injury while handling or working around them. Knowing how to “read” a bull’s behavior can save one’s life [1-3]. Facial Trauma inflicted by Bulls and other Gored animals are very commonly South America and other Latin countries; Most of them due to Taurine festival and fair. Other professionals who handle bulls also can suffer goring injuries, such as veterinarians, cattle owners, slaughterers, etc. According to the characteristics of these animals, patients who have been gored by a bull must be considered as a patient with multiple injuries and treated as such from the first time the patient is seen. The wounds caused by bull horn usually produced damaged so severe that the person who suffers it, must be considered a polytraumatized patient [4,5].

Large farm animal-inflicted injuries are rare and most commonly occur among people living in rural areas with head injuries being the most common [6]. Injures cause by bull goring are classified based on the bullfighting terminology: a) Lance: contusion resulting from the horn’s transversal collision; b) Puntazo (a light horn puncture wound or scratch): structural continuity of skin and subcutaneous cellular tissue caused by the tip of the horn and not involving the muscles; c) Cornada (goring): small entry, lacerated contused wound involving the muscles or body cavities; d) Cornada despistante (misleading goring): entry wound is far away from the most significant trauma area; e) Cornada envainada (penetrating goring): deep injury with severe internal lesions without structural continuity in the skin [7].

### Case Presentation

A 76 years old man farmer who was herding cattle by the time of injures. He was rammed by a bull which gored him in the right side of the neck. The patient was delivered to emergency room at Juarez Hospital of Mexico. Oral and Maxillofacial Surgery Service was called to check up the patient (Figure 1). He enters stable and conscious. Clinical examination reveals a wound flap, torn in the right side of the neck with facial vessels exposed and mandible fracture (Figure 2). Computed Tomography, reveal body and ramus mandible fracture and Zygomatic complex Fracture as well

### OPEN ACCESS

#### \*Correspondence:

Liceaga R Rodrigo, Department of Maxillofacial Surgery, General Hospital of Campeche, Mexico, E-mail: r\_liceaga@hotmail.com

Received Date: 30 Oct 2019

Accepted Date: 05 Dec 2019

Published Date: 09 Dec 2019

#### Citation:

Luis FG, Rodrigo LR, Rogelio BO, Luis BA. Bull Horn Injure in Neck and Face Bones: Case Report and Literature Review. *World J Oral Maxillofac Surg.* 2019; 2(4): 1036.

Copyright © 2019 Liceaga R

Rodrigo. This is an open access article distributed under the Creative Commons Attribution License, which permits unrestricted use, distribution, and reproduction in any medium, provided the original work is properly cited.

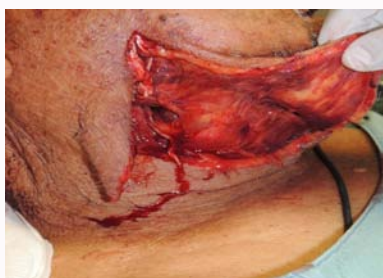

Figure 1: ER wound checking.

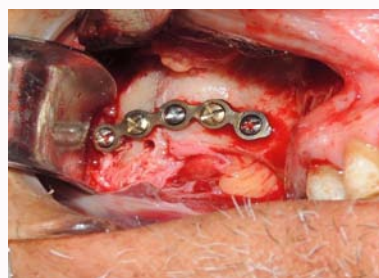


Figure 5: Malar fracture fixation.

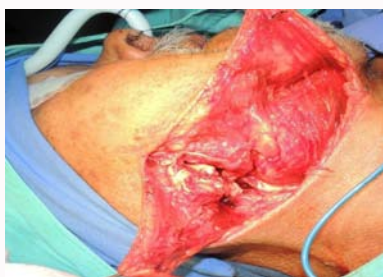

Figure 2: Wound flap expose.

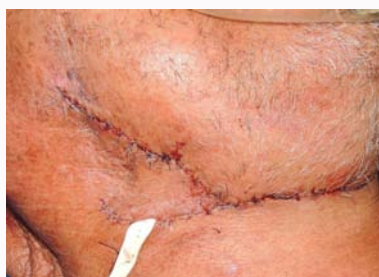

Figure 6: Wound closed.

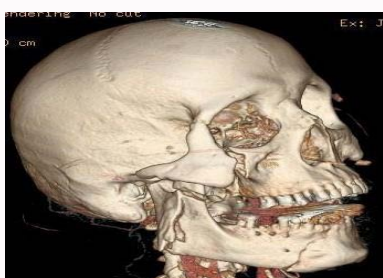

Figure 3: CT scan 3-D reconstruction.

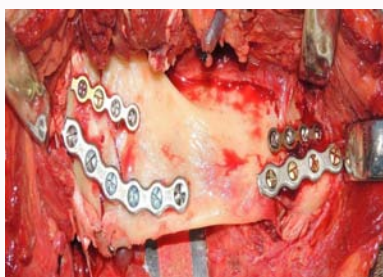


Figure 4: Mandible fracture fixation.

(Figure 3 and 4). The patient entered to operating room under nasotracheal intubation, we used the same wound flap to approach the mandible; Facial vessels were ligated, exposing fractures. An open reduction was performed with plates and screws. Intra oral approach was combined to reduce and fix zygomatic fracture to properly align the bone fractures and suturing soft tissue injure finally, with Penrose drainage (Figure 5 and 6). Patient evolution was successful with no infection and proper healing process.

## Discussion

In the literature there's not much information about gored injures, most of them are related to bullfighting. A retrospective study in Spain with a review of medical records of patients admitted

to the General Surgery service of the General Hospital of Castellón, with diagnosis of wound by bull gored, between January 1978 and October 2005 shows the location of the main wounds as its follow: Head and neck 12, thorax 21 (10 piercing and 11 non-penetrating), upper extremities 19, abdomen 44 (31 penetrating), perineum 41, lumbar region-back 6 and lower extremities 244 [8]. Caglayan et al. [9], regarding animal-related injuries reported that 29% of injuries were attributed to cow attack, with maxillofacial and cranial injuries comprising 44% and 18% of all injuries. Wounds of the facial area represent 8% of all wounds caused by bull goring and are divided equally between the facial and cervical regions. the wounds anfractuosis affecting superficial planes (cutaneous, subcutaneous or muscular) the most frequent type of injury of the facial mass, and fractures most frequently produced in this type of accidents are for this order the jaw, the malar and the of the nasal bones. The other types of injuries more frequent at the level of the facial mass are the vascular lesion (facial and lingual artery), intraoral lesions that interest planes deep and the injuries that affect to nasal cartilages or headphones. As well they observed in their series avulsions dental injuries, facial nerve injuries and section of the Stenon duct according with our case [10].

In other regions of the earth like Africa, animal encounters are more common. A retrospect study made by Ugboko a Cols [11]. In contrast with other series much appreciable number of facial fractures injuries was seen in this study.

Cakabay show in here retrospective study that traumas due to farm animals have been identified as the most frequent reasons in maxillofacial fractures. Due to the necessity of being very close to animals during their care and cleaning and labor times, these fractures take place as a result of blows from cows, bulls, and horses. Seeing nasal fractures as the most common injure [12].

Preoperative and postoperative antibiotic therapy and tetanus vaccination: bull horn injuries are very dirty and should be considered contaminated and likely to develop serious infective complications from the time of occurrence.

Horns carry aerobic and anaerobic bacteria, so antibiotic prophylaxis and treatment are a high priority in these patients. Wounds from bull horn are highly contaminated due to the presence of germs in the antler and the natural environment so it is imperative complete tetanus prophylaxis and use antibiotics from broad spectrum to therapeutic doses like in our case [13,2]. These wounds have special characteristics (muscular tearing, several wound paths, introduction of foreign bodies, discrepancy between the apparent and actual wounds, massive inoculation of germs, and others) that make them singular in terms of their proper examination and treatment. These characteristics differentiate them from other types of penetrating injuries, such as knife and gunshot wounds [14].

## Conclusion

The treatment of wounds caused by antlers of bulls or other gored animals requires an integral treatment, a minor revision of the site of the injury and also of the general condition of the patient. The kinematics of this type of injury can cause very serious damages to both soft and hard tissues with serious sequelae and even death of the patient. It is necessary to inform the population that participates in fairs with animals, as well as those who work with them to prevent these injuries keeps happening.

## References

1. Maheshwari A, Raikwar RS, Siddharth D. Bull Horn Injuries Rural problem in India. *Sch J App Med Sci*. 2015;3(8D):3043-7.
2. Albright JL, Arave CW. *The behaviour of cattle*. New York: CAB International Publishers; 1997.
3. Sheldon KJ, Deboy G, Field WE, Albright JL. Bull-related incidents: Their prevalence and nature. *J Agromedicine*. 2009;14:357-69.
4. Crespo Escudero JL, Arenaz Búa J, Luaces Rey R, García-Rozado A, Rey Biel J, López-Cedrún JL, et al. Maxillofacial injury by bull goring: Literature review and case report. *Rev Esp Cirug Oral and Maxilofac*. 2008;30:5.
5. Comín Novella L, del Val Gil JM, Moreno Muzas C, Oset García M. The bull: the great danger of summer festivals. *Cir Esp*. 2008;83(4):215.
6. Ríos-Pacheco M, Pacheco-Guzmán R, Padrón-Arredondo G. Bull horn wounds. A 1 year experience at the O'Horán General Hospital Mérida, Yucatán, México. *Cir Cir*. 2003;71(1):55-60.
7. Campos Mollo E, Pérez Santonja JJ, Samper-Giménez J. Orbital penetrating wound by a bull horn. *Arch Soc Esp Oftalmol*. 2007;82(10):645-8.
8. Martínez-Ramos D, Miralles-Tena JM, Escrig-Sos J, Traver-Martínez G, Cisneros-Reig I, Salvador-Sanchís JL. Bull horn wounds in Castellon General Hospital. A study of 387 patients. *Cir Esp*. 2006;80(1):16-22.
9. Caglayan K, Celik A, Ozkan OF, Celik AS, Koksall N, Altinli E. Large animal-related injuries in a rural population in Northeastern Turkey. *Indian J Surg*. 2013;75(3):200-3.
10. Hambres O, Giraud C, Gouffrant JM, Debry CA. Detailed examination of injuries to the head and neck caused by bullfighting, and other surgical treatment: The role of the cervico-facial surgeon. *Rev Laryngol Otol Rhinol*. 2003;124(4):221-8.
11. Ugboko VI, Olasoji HO, Ajike SO, Amole AOD, Ogundipe OT. Facial injuries caused by animals in northern Nigeria. *Brit J Oral Max Surg*. 2002;40(5):433-7.
12. Cakabay T, Gokdogan O, Bezgin SÜ, Kocyigit M. Maxillofacial traumas in farmers caused by farm animals, agricultural vehicles, and materials. *J Craniofac Surg*. 2016;27(4):E401-6.
13. Navarro Roldán J, Castell Campesino L, Escrig Sos J. Injuries from a bull horn, experience on 31 cases. *Medical Science* 1990;7:118-24.