



Brachial Artery Transection Following a Simple Open Posterior Elbow Dislocation in an Adult Female; A Case Report and Review of Literature

Christopher Yu Chow*

Department of Vascular Surgery, Ochsner Medical Center, USA

Abstract

Background/Objective: Although brachial artery transection is a rare complication of an acute, simple, posterior elbow dislocation, vascular surgeons must be aware of the injury and its variable presentation and treatment options.

Methods: We report a case of an obese, middle aged female who suffered this complicated injury after falling from her bicycle at a low speed. A review of the literature for similar cases was additionally conducted to highlight key issues regarding its diagnosis, management, and prognosis.

Results: Despite an initially reassuring vascular exam, the patient developed diminished pulses the day after her initial injury. After angiographic confirmation, an open surgical repair was performed. During the surgery, the elbow repeatedly dislocated, requiring intraoperative orthopedic assistance. In all cases reported, reconstruction of the artery led to restoration of the vasculature.

Conclusion: Brachial artery transection may be present in spite of seemingly low mechanism elbow dislocations and reassuring initial physical examinations. Although a rare clinical entity, a high index of suspicion must be maintained by the surgeon when consulted to evaluate upper extremity vascular trauma.

Keywords: Simple elbow dislocation; Open elbow dislocation; Posterior elbow dislocation; Brachial artery transection; Brachial artery injury; Traumatic vascular injury

OPEN ACCESS

*Correspondence:

Christopher Yu Chow, Department of Vascular Surgery, Ochsner Medical Center, New Orleans, USA, E-mail: chris.yu.chow@gmail.com

Received Date: 24 Feb 2021

Accepted Date: 24 Mar 2021

Published Date: 29 Mar 2021

Citation:

Chow CY. Brachial Artery Transection Following a Simple Open Posterior Elbow Dislocation in an Adult Female; A Case Report and Review of Literature. *World J Vasc Surg.* 2021; 4(1): 1029.

Copyright © 2021 Christopher Yu Chow. This is an open access article distributed under the Creative Commons Attribution License, which permits unrestricted use, distribution, and reproduction in any medium, provided the original work is properly cited.

Introduction

A fall onto an outstretched hand, forcing the elbow into hyperextension, often leads to posterior elbow dislocations [1]. Although the associated high energy force can damage nearby neurovascular structures due to its anatomic proximity, posterior elbow dislocations due to this type of blunt trauma rarely result in significant brachial artery injuries [1,2], despite being among the most common traumatic injuries.

Clinically significant vascular injury will typically present with “hard” or “soft” signs [3]. However, due to the plentiful collateral circulation of the upper extremity, these signs may often be absent or may manifest subtly despite significant vascular compromise [4]. These injuries can result in significant morbidity such as limb loss and therefore must not be missed.

We present a case in which a patient with a simple, posterior elbow dislocation suffered a transected brachial artery, with a delay in the diagnosis of the vascular injury. The patient has signed a consent allowing for our report of her case.

Case Presentation

A 40-year-old female masseuse (height: 170 cm, weight: 129 kg) presented to the emergency department after falling onto her outstretched left arm while riding her bicycle at a low speed. She complained of numbness and tingling throughout the dorsal aspect of her hand and elbow pain. No other trauma was sustained.

On initial examination, a six-centimeter transverse laceration to left antecubital fossa with an obvious bony deformity and exposed subcutaneous fat was appreciated. There was reduced sensation to the median nerve distribution; otherwise, the distal limb appeared normal. Motor function was completely intact. There was neither significant bleeding nor hematoma. Radial and ulnar pulses

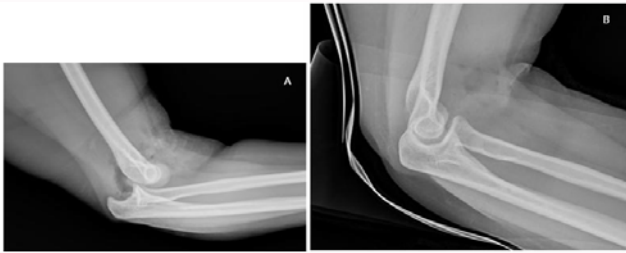


Figure 1A, 1B: X-ray of the posterior elbow dislocation, before and after closed reduction.

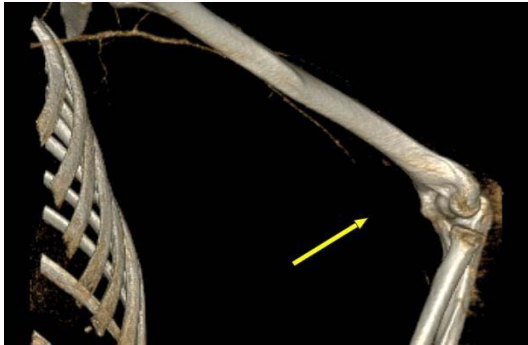

Figure 2: 3D reconstructed CTA of an unopacified, unvisualized, segment of the left brachial artery concerning for transection versus thrombosis.

were strong and equal bilaterally, and she was normotensive.

A left elbow X-ray revealed a posterior dislocation of the elbow without any fracture, which was successfully reduced in the emergency room (Figure 1A and 1B). The patient was observed overnight awaiting definitive orthopedic treatment.

The following morning, the patient was noted to have diminished left radial pulses. Although a Doppler exam revealed an intact left radial, ulnar, palmar arch, and brachial artery signal, a CT angiogram of the left upper extremity revealed a brachial artery transection (Figure 2).

The patient was urgently taken to the operating room. A “lazy-S” incision in the left medial arm was made in an attempt to expose the brachial artery, but the patient’s anatomy led to a challenging exploration. Ultimately, it was revealed that the brachial artery had been transected at its bifurcation, greatly displacing it from the expected course. After debridement, a six-centimeter gap was noted between the two ends.

Throughout the surgery, the arm was grossly unstable and frequently dislocated despite attempts at external support. The orthopedic team was consulted intraoperatively. The elbow was percutaneously pinned at 60 degrees of flexion, achieving a balance of stability, and allowing for adequate exposure for the vascular repair. Simultaneously, the contralateral greater saphenous vein was harvested in a standard fashion.

A Fogarty balloon thromboembolectomy was then performed until no clot returned and excellent inflow and back-bleeding were achieved. Arterial reconstruction was then completed with a reversed venous bypass and an end-to-end anastomosis at the brachial bifurcation. Post-repair intraoperative Doppler exam demonstrated a strong biphasic signal in all arterial distributions. A fasciotomy was not performed, and compartments were monitored closely.

Upon conclusion of the surgery, radial artery pulses were palpable. The patient was placed in a splint and discharged two days after the operation.

Afterwards, the patient’s recovery was excellent. At 1-month follow-up, the neurovascular exam of her left upper extremity was reassuring for a return to baseline. She was treated by the orthopedic team for definitive repair of her elbow dislocation.

Discussion

Because posterior elbow dislocations make up more than 80% of dislocations, brachial artery transections are more associated with posterior dislocations [1,5]. In posterior elbow dislocations, the distal portion of the artery can become trapped between the distal humerus and the bicipital aponeurosis which inserts on the distal humerus and proximal radius [6]. Brachial artery transections also occur more with open elbow dislocations than closed dislocations because of higher mechanism, and similarly, more often with penetrating trauma than blunt trauma [1,2,4,5]. Intuitively, complex dislocations those with associated bone fractures are more likely to be associated with vascular trauma than simple dislocations.

The presence of a distal pulse is not enough to definitively rule out a vascular injury. Perry et al. [7] previously demonstrated that intact pulses distal to the site of the lesion can still be palpated in approximately 10% of patients with vascular injuries [7]. Additionally, even when pulses are absent, the rich collateral flow in the upper limb through the profunda brachii, ulnar, and radial collateral arteries continue to supply the arm, and thus have led to the injury being referred to as the “pink pulseless hand” [8]. Our patient demonstrated a faint but diminished pulse, necessitating the use of CT angiography to completely clarify the extent of injury. Duplex ultrasonography is another useful but sometimes limited tool. Catheter angiography is the gold standard for diagnosis and can be obtained early if suspicion is high [2-4].

There are many approaches to treatment. Open surgery is the mainstay of treatment. Options include direct repair, which often is unachievable due to lack of vessel length after debridement, or an interposition graft, which affords the surgeon versatility but lengthens surgical time. Simple ligation and conservative treatment are viable options given the rich arterial collateral network but puts the patient at higher risk of future complications such as claudication and cold intolerance [2-4,6]. There have also been reports of endovascular repairs transection [9], although these techniques are still being refined and are typically done due to patients being in extremis and unable to tolerate an open operation.

Due to the variability of presentation and management of the injury, a literature search was conducted. The keywords “elbow dislocation brachial artery transection” was searched in PubMed and yielded 14 results, 12 comparable studies and 15 total patients. In four of the 15 patients, diagnosis of brachial artery transection as a consequence of posterior elbow dislocation was not initially recognized, and operative management was deferred. This was because either the initial vascular exam was reassuring, or the vascular exam had improved after closed reduction of the dislocated elbow. Two patients were observed with serial neurovascular checks, whereas the other two were prematurely discharged. In one third of the total patients, the only clinical sign was an absent pulse, and in six of 15 patients, more than one vascular deficit (e.g., coolness, pallor, dampened Doppler signals, delayed capillary refill, etc.) was

present on exam. Motor vehicle trauma was the impetus for injury in four patients, in seven patients, the cause was a recreational activity such as wrestling, rugby, or in-line ice skating. All patients had their brachial artery transection repaired with a saphenous vein graft, in five patients concurrent thromboembolectomy was performed, and fasciotomy was performed in five patients. All surgeries led to successful repairs.

All but one of the reported cases were associated with a closed elbow dislocation. Similar to our patient, Nazli et al. [10] reported the case of a 12-year-old boy that sustained a simple, open elbow dislocation due to a heavy object falling onto his arm [10]. The patient was initially treated with an elbow reduction and discharged afterwards. An acute vascular injury was not initially appreciated. Three days later, the patient sought care for a cold but well colored hand with absent radial pulses. Successful repair occurred in a fashion similar to our case.

Conclusion

In summary, brachial artery transection can be a complication of a simple, open posterior elbow fracture due to blunt trauma. Suspicion for such an injury should be high as clinical signs may not be readily apparent. Angiography will confirm the presence of a transection and rapid operative repair coordinated with the orthopedics team are essential to treating these potentially complicated injuries. Proper management will lead to excellent outcomes.

References

1. Sheehan SE, Dyer GS, Sodickson AD, Patel KI, Khurana B. Traumatic elbow injuries: What the orthopedic surgeon wants to know. *Radiographics*. 2013;33(3):869-88.
2. Sparks SR, DeLaRosa J, Bergan JJ, Hoyt DB, Owens EL. Arterial injury in uncomplicated upper extremity dislocations. *Ann Vasc Surg*. 2000;14(2):110-3.
3. Sidawy AN, Perler BA, editors. *Rutherford's vascular surgery and endovascular therapy*. 9th Ed. Philadelphia, PA: Elsevier; 2019.
4. Endean ED, Veldenz HC, Schwarcz TH, Hyde GL. Recognition of arterial injury in elbow dislocation. *J Vasc Surg*. 1992;16(3):402-6.
5. Boretto JG, Rodriguez Sammartino M, Gallucci G, De Carli P, Ring D. Comparative study of simple and complex open elbow dislocations. *Clin Orthop Relat Res*. 2014;472(7):2037-43.
6. Marcheix B, Chaufour X, Ayel J, Hollington L, Mansat P, Barret A, et al. Transection of the brachial artery after closed posterior elbow dislocation. *J Vasc Surg*. 2005;42(6):1230-2.
7. Perry MO, Thal ER, Shires GT. Management of arterial injuries. *Ann Surg*. 1971;173(3):403-8.
8. Brahmandam P, Plummer M, Modrall JG, Megison SM, Clagett GP, Valentine RJ. Hand ischemia associated with elbow trauma in children. *J Vasc Surg*. 2011;54(3):773-8.
9. Maynar M, Baro M, Qian Z, López-Benitez R, Ragheb D, Llorens R, et al. Endovascular repair of brachial artery transection associated with trauma. *J Trauma*. 2004;56(6):1336-41.
10. Nazli Y, Colak N, Uras I, Komurcu M, Cakir O. Brachial artery transection associated with open elbow dislocation in a 12-year-old: A case report. *Vascular*. 2013;21(1):27-30.