



# Bone Anchored Mucosal Flap for Reconstruction of Floor of Mouth and Gingiva-Pilot Study

Jan Akervall\* and Natalie Gratsch

Department of Otolaryngology, St. Joseph Mercy Hospital, USA

## Abstract

**Objectives:** The defects after resections of T2 and limited T4 tumors of the anterior floor of mouth and gingival are often reconstructed with free forearm flaps or bilateral nasolabial flaps. These techniques are often associated with impaired sensation and unpredictable scar formation both intra orally and at the donor site. Patients may experience symptoms such as dysphagia, dysarthria and donor site cosmetic problems. Therefore, we have developed a reconstructive alternative that allows for the reliable coverage of soft tissue and bone, preservation of local sensation and rapid recovery of oral functions.

**Study design:** This is a prospective study of eight patients, six of which had T2 lesions of the anterior floor of mouth and two had T2 lesions of the gingiva. The defects measured 4 cm to 5 cm by 2.5 cm to 3 cm including partial mandibulectomy with up to nine teeth.

**Method:** A local mucosal flap was raised from the inferior aspect of the tongue. Multiple holes were drilled in the exterior cortex of the mandibular defect. The flap was then pulled forward and anchored to these drill holes by 3-0 sutures. The anterior margin of the defect was also anchored to these drill holes to produce a water tight closure, allowing the lip to be independent of the mucosal flap.

**Results:** The mucosal flap stretched and normalized into position within 2 weeks. After that seven of the eight patients had normal or minimally decreased tongue mobility and normal speech (one patient developed osteoradionecrosis after postoperative radiation). Fully normal sensation in the flap was experienced by six of the patients, with only two noting slight impairment. Swallowing capacity was normal or minimally affected.

**Discussion:** This local bone anchored mucosal tongue flap has the advantage of short operating room time and hospitalization, only one surgeon is required, there is no donor site morbidity and rapid return of oral function.

**Conclusion:** We propose this flap as a reconstructive alternative for defects up to the size of T2 and small T4 lesions of the anterior floor of mouth and gingiva.

**Keywords:** Oral reconstruction; Regional flaps; Floor of mouth cancer; Gingival cancer; Donor site morbidity; Dysphagia; Dysarthria

## Introduction

Reconstruction after resection of carcinomas of the anterior floor of mouth and gingiva in combination with partial mandibulectomy is traditionally accomplished using free micro vascular radial forearm flaps, bilateral regional platysmal flaps or bilateral nasolabial flaps [1-6]. Our experience shows that postoperative healing is often difficult to predict. Scar formation affects tongue mobility impacting chewing and swallowing [6]. The loss of sensation in the reconstructed area further compounds these issues. Consequently, these patients have difficulty moving the food around in the oral cavity, and do not fully sensate when it gets stuck under the tongue. Together with impaired articulation, this becomes a major social issue for the patients. With regards to the donor morbidity, this would include cosmetic and functional issues that can be significant for a patient group that already is marked by the burdens of this disease. Furthermore, operating room costs (time and materials) and the complexities and intensive time required for postoperative care are significant parameters in reconstruction with free flaps [7].

In the present pilot study of eight patients, we introduce a new regional reconstructive procedure for T2 tumors of the floor of mouth and gingiva that does not require a donor site outside the oral

## OPEN ACCESS

### \*Correspondence:

Jan Akervall, Department of Otolaryngology, St Joseph Mercy Hospital, 5333 McAuley Dr #2017, Ypsilanti, MI 48197, USA, Tel: 734-434-3200;

E-mail: akervall@mosaent.com

Received Date: 26 Sep 2019

Accepted Date: 30 Oct 2019

Published Date: 18 Nov 2019

### Citation:

Akervall J, Gratsch N. Bone Anchored Mucosal Flap for Reconstruction of Floor of Mouth and Gingiva-Pilot Study. Am J Otolaryngol Head Neck Surg. 2019; 2(10): 1077.

Copyright © 2019 Jan Akervall. This is an open access article distributed under the Creative Commons Attribution License, which permits unrestricted use, distribution, and reproduction in any medium, provided the original work is properly cited.

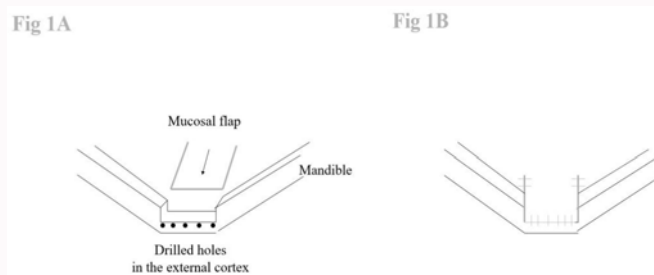


Figure 1: Schematic of the reconstructive procedure.

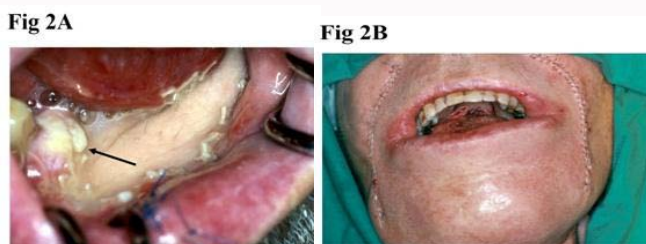

Figure 2: Bilateral nasolabial regional flaps in edentulous patients achieve this functional repair but cause cosmetic damage at the donor sites.

Table 1: Eight patients with squamous cell carcinoma of the oral cavity that underwent primary resection and were reconstructed by bone-anchored mucosal flaps.

Pat.	Sex/Age (Y)	Site	TNM	Defect (cm) (L x W x D)	FU (mo)/cause	Postop XRT (Y/N)
1	F/84	FOM	T2N0M0	5 x 4 x 2	32/NED	Y
2	M/82	FOM	T2N0M0	4 x 3 x 1,5	18/LC-DM	Y
3	M/81	FOM	T2N2CM0	5 x 3,5 x 2	33/NED	Y
4	M/61	Gingiva	T2N0M0	4 x 3 x 2	35/NED	Y
5	M/62	FOM	T2N0M0	5 x 4 x 2	20/NED	Y
6	M/70	FOM	T2N0M0	5 x 3 x 2	18/NED	Y
7	M/65	FOM	T2N1M	4 x 3 x 2	16/NED	Y
8	M/54	Gingiva	T2N0M0	5 x 3 x 2	14/NED	N

F: Female; M: Male; FOM: Floor of Mouth; FU: Follow-up (months) after Surgery; LxWxD: Length x Width x Depth; NED: No Evidence of Disease; LC-DM: Local Control, Distant Metastases (skeletal)

Table 2: Functional outcome in 8 patients that underwent primary resections of anterior floor of mouth and were reconstructed with local bone-anchored mucosal flaps.

Pat.	Tongue Mobility	Speech	Swallowing	Scar formation	Sensation	Comments
1	+++	+++	+++	-	+++	
2	+++	+++	+++	(+)	++	
3	+++	+++	+++	-	+++	
4	++	+++	+++	(+)	++	
5	+++	+	+++	+	+++	OR
6	++	++	++	+	++	Scaring after Postop RT
7	++	++	++	+	+++	
8	+++	+++	+++	(+)	+++	Ranula

+++ Maximal, (+) Minimal, - None, OR: Osteoradionecrosis; RT: Radiotherapy

cavity or a second reconstructive surgical team. After resection with frozen section margin assurance and partial mandibulectomy, along with up to nine teeth, dissection elevates a regional full thickness mucosal flap from the remaining floor of mouth and lateral aspect of the tongue up to the dorsum. We drill holes in the outer table of the remaining mandible and sutures anchor the flap to these holes. Tongue movement stretches this bone-anchored mucosa, nonetheless the mucosa remains sensate. The results from this pilot study show complete resurfacing of the floor of mouth and mandible. There is no impact on speech or swallowing and only minimal loss of sensation in

the floor and on the tongue in two of the eight patients.

### Patients

The study group includes eight patients. Table 1 details these patients for their age, sex, tumor size, surgical procedure and defect produced. All eight patients had Squamous Cell Carcinoma (SCC), seven of which received post-operative radiation therapy to 60 Gy to 62 Gy. The patient with nodal involvement had bilateral functional neck dissections and the patient that did not receive postoperative radiation had a unilateral selective neck dissection, level 1-3. Although

three of them were aged, they were all in excellent general condition.

## Materials and Methods

Figure 1 displays a schematic of the reconstructive procedure. Patients received a wide resection with 1 cm macroscopic margins of the gingiva and floor of the mouth, along with partial mandibulectomy including up to nine teeth and approximately half the height of the mandible (superior to the mentigal nerve canal) (Figure 2).

The 5 mm thick mucosal flap was elevated beginning at the full inner margin of the resection and extended towards the tip of the tongue. Afterward, 3 cm long lateral incisions were made to mobilize the flaps which were as wide as the resections. In case no. 5 and 7 the mucosal flaps were elevated from the lateral aspect of the floor of mouth and tongue, given that the tumor involved the tongue in case no. 5 and as far back as the premolar area in case no. 7 (Figure 3). At the external table of the remaining mandible we placed 3-10 drill holes, depending on the size of the resection, from the outside into the cortex which were just large enough to pass a tapered needle. The flap was then anchored to the drill holes using resorbable 3-0 sutures. In a similar fashion, the 3-0 resorbable sutures anchored the buccal or lip mucosa to the drill holes and secured a watertight closure. When needed, further suturing can secure the flap to the floor of mouth or adjacent teeth, which removes tension and brings the flap down. Wharton's ducts were also resected when needed, and the remaining stumps were left in the field without further reconstruction.

The operating time for this closure technique is about an hour. No patient required a tracheostomy as the flap keeps the tongue forward and compensates for slight swelling. In addition, 100 mg to 200 mg IV hydrocortisone was given intra operatively along with 1.5 g cefuroxim and 1000 mg Flagyl. Cefuroxim infusions were administered in single doses. Patients were admitted to the ICU for the first 24 h and then transferred to regular wards.

For the first six cases alimentionation with a feeding tube carried the patients for two days followed by progressive diet advancement through day six. A full diet began on day seven. However, case no. 8 did not get a feeding tube. He was kept on clear fluids for two days, full liquids by the third day after which, we progressed from soft food to regular diet within another three days.

The patients rated their abilities to chew, swallow, speak and

sensate food on the flaps every third month after full completion of the entire treatment program. The treating surgeon evaluated the patients for possible recurrences and rated the tongue mobility and scar formation (Table 2).

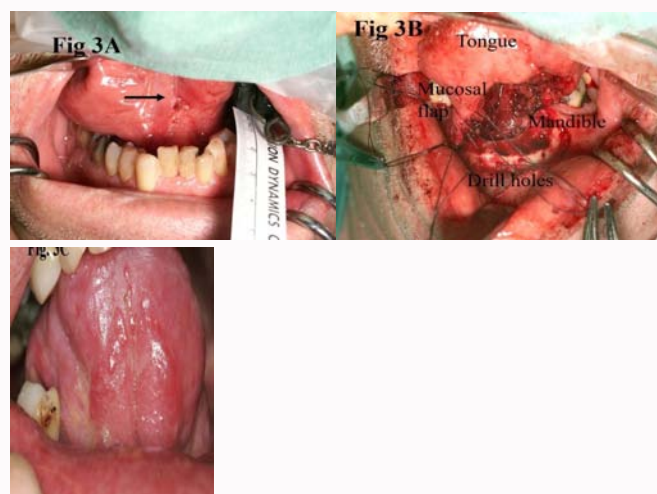## Results

Table 2 details the long term functional results. All eight patients had short hospital stays (3 to 5 days) and no major postoperative complications. At long term follow-up, five of the eight patients had excellent swallowing and speech, with only one who reported minor problems that were not objectively observed (speech and swallow related). One of the remaining two patients developed osteoradionecrosis from postoperative radiation and one was scared down with immobilization of the anterior tongue after radiation. Both these two patients had full function during the interim between surgery and postoperative radiation, but developed the symptoms at the end of radiation therapy. All eight patients had normal (n=5) or slightly decreased sensation in the tongue flap (n=3). Two patients still experience a tingling sensation in the region. All eight can sense the presence of food on the flap so that chewing and clearing the mouth functions properly. A denture device to fill the gap that clicks on to Titanium implants was received by one patient. Figures 4 show the postoperative appearance of the reconstruction.

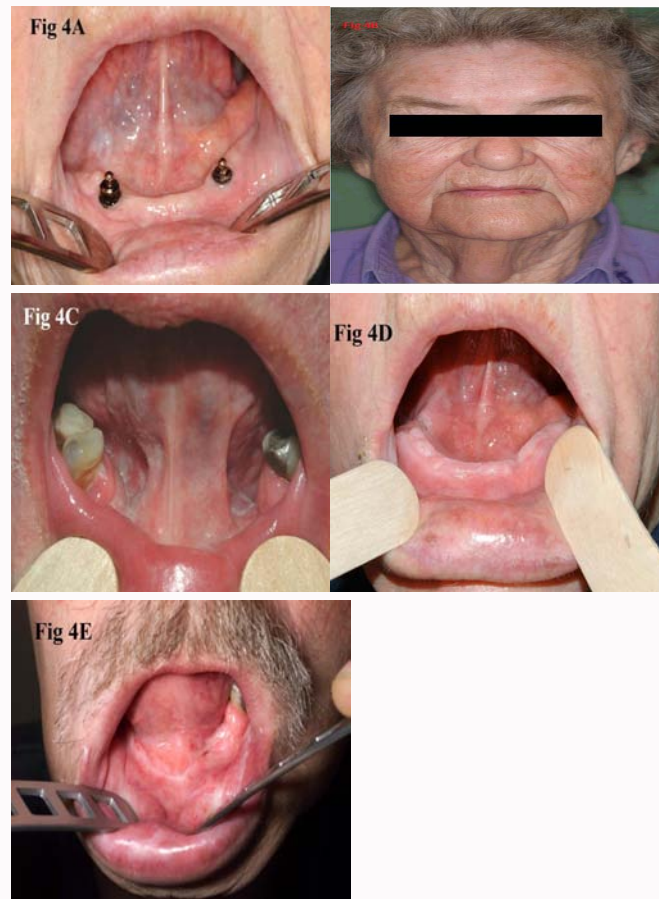
In the immediate postoperative period, the flap bound the tongue down to the area resected. Interiorly the tongue projected towards the lip and inferiorly it extended into the mandibular defect. However, the tongue typically pulled on the flap and stretched it so that by two-three weeks the tongue had returned to an almost normal position and contour. Full tongue function returned with this stretching. Temporary swelling of the submandibular glands was experienced by one patient, which subsided within a week. Another patient developed a Ranula that needed marsupialization to resolve.

## Discussion

Good functional reconstruction of the floor of mouth demands time and challenges one's technical expertise. Bilateral nasolabial regional flaps in edentulous patients achieve this functional repair but cause cosmetic damage at the donor sites (Figure 2). Many institutions use free micro vascular radial forearm flaps. However, this technique requires increased resources and time, produces



**Figure 3:** The mucosal flaps were elevated from the lateral aspect of the floor of mouth and tongue.



**Figure 4:** Postoperative appearance of the reconstruction.

cosmetic issues at the donor site, and endangers the survival of the flap with local immediate postoperative difficulties and later systemic distant complications [8-12]. Radial forearm fascia flaps improve the cosmetic aspects of the donor site but still scar within the mouth and hinder tongue movement [6].

Within the mouth at the site of repair, postoperative problems revolve around the loss of sensation and the stiffening of the tissue implanted. The loss of sensation and stiffness of a scarred region in the floor result in immobilization of the anterior tongue and difficulties to remove food from the area. Nerve grafting using the cutaneous antebrachial nerve to the lingual nerve or the greater auricular does not achieve a sensate region with any reliability. External skin grafted into the floor carries with it the problems of stiffness and dryness. With this, scar formation defies consistent improvement.

We have piloted a new flap technique on eight patients to avoid the aforementioned problems of reconstruction after floor of mouth or gingival resection. A wide local flap based on the ventral surface of the tongue covers the defect securely by anchoring directly to drill holes in the outer table of the partly resected mandible. Using the buccal or lip mucosa anchored through the same holes, we achieve a watertight closure. This firmly fixes the mobilized tissues so that primarily the defect is securely covered. The tonic stretching of the tongue results in gradual elongation of the well-anchored mucosal flap without tearing the closure. This results in rapid closure of the defect, rapid return of function with a region that is smooth, moist and can sensate with contraction. The mucosal flap is about 5 mm thick which gives sufficient protection to the mandible for post-operative

radiation therapy. Only one patient developed osteoradionecrosis.

The reconstructive procedure requires only one surgeon, one hour of time and does not need an outside donor site. The demands of this reconstruction do not inhibit the degree of resection. The return to eating and speaking completes in one week. Some limitation of tongue projection out of the mouth was expressed by two patients. In addition, some minor paresthesia of the tongue flap was noted by two patients as well. No patient had inhibition of movement of food through the mouth for swallowing.

Resection of Warthin’s duct to achieve clear tumor margins did not cause any problems. We did not reimplant the ducts or try to reconstruct them. A ranula of the floor of mouth was experienced by one patient but this resolved within a week after marsupialization. A Ductoplasty does not appear to be necessary.

**Conclusion**

This procedure offers the following advantages over traditional reconstructive alternatives: short OR time, one surgeon, uncomplicated postoperative care, excellent cosmetic outcome, normal chewing, swallowing and speech, normal to slightly impaired tongue mobility and good sensibility in the operated region. It can be recommended as a reconstructive alternative to bilateral nasolabial flaps and free radial forearm flaps after resections of T2 and small T4 tumors of the anterior and lateral floor of mouth and/or gingival, not involving the bone marrow, thus requiring only partial mandibulectomy along with soft tissue resection.

## References

1. Soutar D, Scheker L, Tanner N, McGregor IA. The radial forearm flap: A versatile method for intraoral reconstruction. *Br J Plast Surg.* 1983;36(1):1-8.
2. Soutar D, McGregor I. The radial forearm flap in intraoral reconstruction: The experience of 60 consecutive cases. *Plast Reconstr Surg.* 1986;78(1):1-8.
3. Kawashina T, Harii K, Ono I, Ebihara S, Joshizumi T. Intraoral and oropharyngeal reconstruction using a deepithelialized forearm flap. *Head Neck.* 1989;11(4):358-63.
4. Masser MR. The preexpanded radial free flap. *Plast Reconstr Surg.* 1990;86(2):295-301.
5. Vaughan ED. The radial forearm free flap in orofacial reconstruction. Personal experience in 120 consecutive cases. *J Craniomaxillofac Surg.* 1990;18(1):2-7.
6. Martin IC, Brown AE. Free vascularized fascial flap in oral cavity reconstruction. *Head Neck.* 1994;16(1):45-50.
7. Urken M. Radial Forearm. In: Urken M, editor. *Atlas of regional and free flaps for head and neck reconstruction.* New York: Raven Press; 1995:149-68.
8. Hsieh C, Kuo Y, Yao S, Liang C, Jeng S. Primary closure of radial forearm flap donor defects with a bilobed flap based on the fasciocutaneous perforator of the ulnar artery. *Plast Reconstr Surg.* 2004;113(5):1355-60.
9. Skoner JM, Bascom DA, Cohen JI, Andersen PE, Wax MK. Short-term functional donor site morbidity after radial forearm fasciocutaneous free flap harvest. *Laryngoscope.* 2003;113(12):2091-4.
10. Bardsley A, Soutar D, Elliot D, Batchelor A. Reducing morbidity in the radial forearm flap donor site. *Plast Reconstr Surg.* 1990; 86(2):287-92.
11. Jones BM, O'Brien CJ. Acute ischaemia of the hand resulting from elevation of a radial forearm flap. *Br J Plast Surg.* 1985;38(3):396-7.
12. Hallock G. Complication of the free flap donor site from a community hospital perspective. *J Reconstr Microsurg.* 1991;7(4):331-4.