



## Biphasic Synovial Sarcoma

Luciano Zogbi Dias\*

Federal University of Rio Grande, Brazil

### Clinical Images

A 22-year-old female patient presented right shoulder mass about 3 months ago, manifested by pain and paresthesia throughout the upper limb. During examination, the tumor presented 20 cm in diameter and invaded the glenohumeral joint (Figures 1,2). The patient was submitted to a complete resection of the scapula, proximal portion of the humerus and lateral portion of the clavicle, together with the tumor and the surrounding soft tissues, in block, taking care to preserve the axillary vessels (Figure 3). She presented favorable postoperative evolution, with preservation of the upper limb, sensitivity and movements of the forearm and hand, despite the extensive resection (Figure 4). The diagnosis established was a biphasic synovial sarcoma with a high degree of malignancy and free surgical margins. These sarcomas occur in about 2.75 individuals per 100,000 inhabitants, predominantly between 20 and 50 years old, it is usually aggressive and treatment involves radical resection.

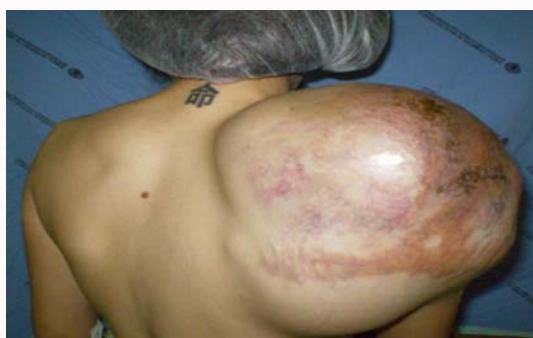

Figure 1:

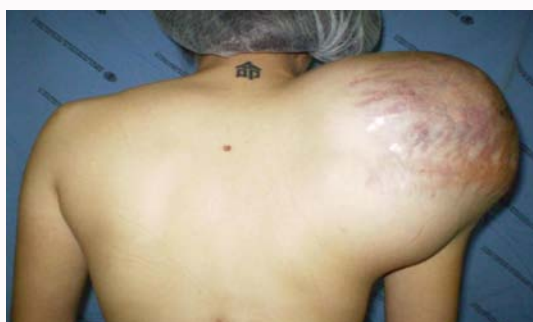

Figure 2:

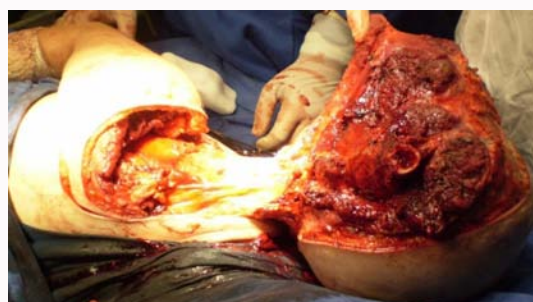


Figure 3:

### OPEN ACCESS

#### \*Correspondence:

Luciano Zogbi Dias, Federal University of Rio Grande, Rio Grande City, Rio Grande do Sul State, Brazil,  
E-mail: zogbi@furg.br

Received Date: 11 Jan 2018

Accepted Date: 29 Jan 2018

Published Date: 09 Feb 2018

#### Citation:

Dias LZ. Biphasic Synovial Sarcoma. *Ann Surg Case Rep.* 2018; 1(1): 1001.

**Copyright** © 2018 Luciano Zogbi Dias. This is an open access article distributed under the Creative Commons Attribution License, which permits unrestricted use, distribution, and reproduction in any medium, provided the original work is properly cited.

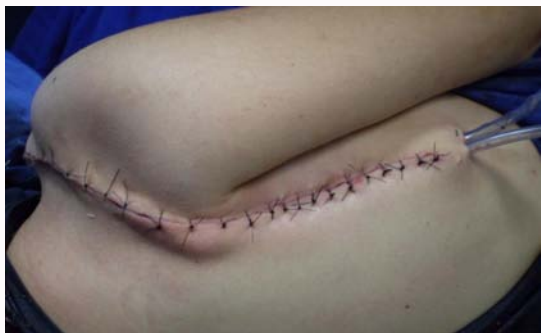

Figure 4: