



# Benign Subcutaneous Emphysema Following Knee Arthroscopy: Report and Review of the Literature

Robert W Ike\*

Department of Internal Medicine/Rheumatology Division, University of Michigan Medical Center, USA

## Abstract

**Objective:** Describe patients developing subcutaneous edema after knee arthroscopy.

**Methods:** New case plus MEDSEARCH of “knee”, “subcutaneous edema” and “arthroscopy”.

**Results:** Of 6 cases, 4 could be traced to mishaps during the arthroscopic procedure and another to a non-healing wound. Edema ranged from chest wall to ankle, and usually appeared several days after arthroscopy. Patients appeared well and did not motivate treatment for gas gangrene. Recovery was complete within 2 days to 3 weeks, with no residual effect on the operated knee.

**Conclusion:** Subcutaneous edema is a rare dramatic complication of knee arthroscopy with a benign outcome.

**Keywords:** Subcutaneous emphysema; Gas gangrene; Arthroscopy; Knee

## Introduction

Detection of air in soft tissues (subcutaneous emphysema) begets concern for infection by gas forming organisms (gas gangrene) [1], disruption of tissue boundaries [2] or both. A recent case presenting with subcutaneous emphysema several days after knee arthroscopy illustrates concerns arising with such a presentation, relationship to facets of the arthroscopic procedure and ultimate benign outcome, reflected in previously reported similar cases, which were found with MEDSERCH using terms “emphysema”, “knee” and “arthroscopy”. REB approval was not sought for the report as all data derived from regular clinical care of the new case and thus did not require approval according to the policies of the University of Michigan IRB.

## OPEN ACCESS

### \*Correspondence:

Robert W Ike, Department of Internal Medicine/Rheumatology Division, University of Michigan Medical Center, USA, Tel: 734-936-5560; Fax: 734-763-1253;

E-mail: rike@umich.edu

Received Date: 10 Aug 2017

Accepted Date: 14 Dec 2017

Published Date: 21 Dec 2017

### Citation:

Ike RW. Benign Subcutaneous Emphysema Following Knee Arthroscopy: Report and Review of the Literature. *Ann Orthop Musculoskelet Disord.* 2017; 1(2): 1008.

**Copyright** © 2017 Robert W Ike. This is an open access article distributed under the Creative Commons Attribution License, which permits unrestricted use, distribution, and reproduction in any medium, provided the original work is properly cited.

## Case Report

A 40-year-old woman presented with L leg swelling that had begun 10 days after an arthroscopic debridement for knee OA. The swollen area felt “crunchy” to her when she passed her hand over the skin. She had otherwise felt well and denied fever, chills, or sweats. Exam found a small knee effusion and subcutaneous crepitus from the upper thigh down to the ankle. Arthrocentesis retrieved air followed by colorless clear fluid. X-ray (Figure 1A-1D) showed air in the joint (arrows) and extensive subcutaneous gas in soft tissues of the thigh, knee and lower extremity. Because she was otherwise well, she was sent home but later went to a local emergency room from which she was admitted out of concern for gas gangrene, and airlifted back to University hospital where MRI (Figure 1E and 1F) demonstrated mild edema and enhancement along scattered fascia planes (arrows) suspicious for early fasciitis. She was placed on empiric antibiotics. Her physical signs did not progress and X-ray 2 days later shown a significant decrease in the subcutaneous emphysema. Swelling and subcutaneous crepitus resolved over the next two weeks. Later conversation with the orthopedist that performed her arthroscopy disclosed that the controlled irrigation pump had run dry during the procedure likely infusing her knee with air.

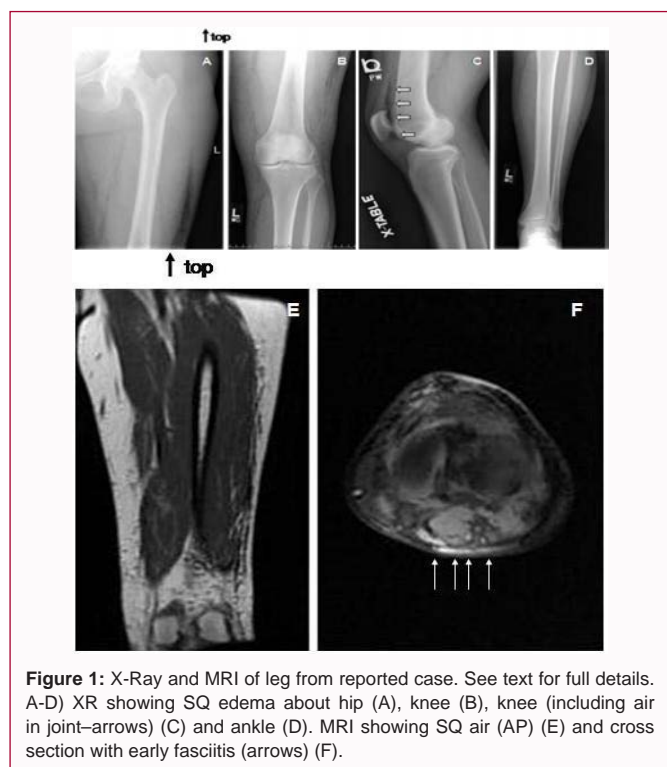
## Discussion

Subcutaneous emphysema is a rarely reported complication of knee arthroscopy, with 5 cases appearing in the English language literature before this one (Table 1). All have followed operative interventions. In 4 cases, components of the arthroscopic procedure could be considered to have introduced air: air driven chondrotome [3], CO<sub>2</sub> insufflation [4], a Mitek vaporizer (radiofrequency driven instrument which produces steam from ablated tissue) [5], and an infusion pump delivering air (this case). In one case, an unhealed portal was judged to be the source of air [6]. Only 2 cases appeared as immediate post operative conversations, with the rest taking from 4 to 10 days to appear.

**Table 1:** Cases of benign subcutaneous emphysema following knee arthroscopy.

Age/sex/knee	Diagnosis/es	Arthroscopy details	Operation(s)	Time to presentation	Extent of emphysema	ABX?	recovery	Reference
28/M/R	chondromalacia	Controlled infusion pump Air-driven chondrotome	Chondroplasty Lateral release	1 day	Thigh, abdominal wall, retroperitoneum, scrotum	no	7 days	3
34/M/L	Torn meniscus	Gravity infusion CO <sub>2</sub> insufflation	Partial meniscectomy	12 hours	Chest wall, abdomen, thigh	no	2 days	4
62/M/L	OA meniscal tear	Gravity infusion	debridement	4 days	Thigh, knee	n.m.	5 days	5
16/M/L	Pathologic fat pad	Gravity infusion Mitek vaporizer (RF) Chondrotome	Fat pad resection	7 days	Thigh, knee	no	3 weeks	6
69/F/R	OA meniscal tear	(infusion not mentioned) unhealed portal	debridement	9 days	Thigh, knee	oral	3 weeks	7
40/F/L	OA	Controlled infusion pump	debridement	10 day	Hip, thigh, knee, ankle	i.v.	2 weeks	This case

OA: Osteoarthritis; RF: Radiofrequency ablation; ABX: Antibiotics; n.m.: not mentioned; i.v.: intravenous



**Figure 1:** X-Ray and MRI of leg from reported case. See text for full details. A-D) XR showing SQ edema about hip (A), knee (B), knee (including air in joint—arrows) (C) and ankle (D). MRI showing SQ air (AP) (E) and cross section with early fasciitis (arrows) (F).

Despite the dramatic appearance of extensive emphysema, ranging from chest wall to ankle, only 2 patients received antibiotics - one for an apparent wound infection [7] and none underwent surgery, perhaps because of the uniform description of the patients appearing otherwise well in all cases. Spontaneous recovery was generally prompt, ranging from 2 days to 3 weeks. In no case was mentioned any adverse effect of the complication on the treated knee.

## Conclusion

Extensive subcutaneous edema of the leg and sometimes adjacent tissues is a rare complication of knee arthroscopy, usually related to mishaps during the operative procedure. The dramatic presentation of subcutaneous crepitus and air in soft tissues on imaging can be delayed over a week after the procedure, but responds well to supportive treatment in the otherwise healthy appearing patient, avoiding aggressive treatment for gas gangrene. Recovery is uniform, with no adverse effects on the operated knee.

## References

1. Thakral R, Debabath UK, Damodaran T, Prasad CVR. High infection and subcutaneous emphysema: an emergency, review of literature and case discussion. *Ir J Med Sci.* 2011;180(2):333-6.
2. Ott DE. Subcutaneous emphysema – beyond the pneumoperitoneum. *JLS.* 2014;18(1):1-7.
3. Henderson CE, Hopson CN. Pneumoscrotum as a complication of arthroscopy. A case report. *J Bone Joint Surg Am.* 1982;64(8):1238-40.
4. Amsalem Y, Lin E, Salai M, Pritsch M, Horoslawski H. Extensive subcutaneous emphysema complicating arthroscopy of knee. *Br J Sports Med.* 1985;19(3):167.
5. Deshmukh NV, Shah MM. Extensive subcutaneous emphysema following arthroscopy: a case report. *Knee Surg Sports Traumatol Arthrosc.* 2002;10(2):119-21.
6. Logan AJ, Roy S, Wilson C. Emphysema of the knee and thigh following excessive use of the Mitek vaporizer during arthroscopy of the knee. *Clin J Sports Med.* 2002;12(3):182-3.
7. Kunkel K. Physical therapy complication of pneumoarthrosis and subcutaneous emphysema following knee arthroscopy. *J Orthop Sports Phys Ther.* 2013;43:A39.