



# Auditory Musical Hallucinations by Megaphone: As Debut of Late-Onset Acute Psychosis

Ariadna E González<sup>1\*</sup>, Laura Llansó<sup>2</sup>, Xavier Urra<sup>2</sup>, Eduard Parellada<sup>3</sup>

<sup>1</sup>Department of Psychiatry, University of Panamá, Panamá

<sup>2</sup>Department of Neurology, University of Barcelona, Spain

<sup>3</sup>Department of Psychiatry, University of Barcelona, Spain

## Abstract

**Introduction:** Musical hallucinations which appear in elderly women may have different causes and few cases described in literature exist.

**Methods:** We present a 73 year-old female, with normal prior behavior and no past psychiatric history that sought medical help accompanied by her husband after experiencing auditory hallucinations. These had been appearing during three months as musical sounds and talking (megaphonia), with high emotional and behavioral impact.

**Results:** Neuroimaging showed chronic vascular lesions and the neuropsychological evaluation was pathological, with altered visioconstructive capacity, executive functions, planning, and new learning.

**Conclusions:** this case highlights the significance of proceeding with an extra complementary clinical examination and the neuropsychological evaluation in elderly patients with verbal-musical hallucinations. Despite not having primary psychiatric history the Late-onset acute psychosis in this patient was induced by multiple vascular lesions. The hallucinatory symptoms of musical type are particular in this patient, being a sign of alert that urged the search for probable causes. In this case the combination of all the clinical exams, clinical tests, the neuro-imaging, the neuropsychological tests and the knowledge obtained from her clinical history lead us to the diagnosis of vascular cognitive impairment.

## OPEN ACCESS

### \*Correspondence:

Ariadna E González, University of Panamá, Service of Psychiatry, National Institute of Mental Health, Panamá, E-mail: ariestgon@gmail.com

Received Date: 14 Mar 2019

Accepted Date: 02 Apr 2019

Published Date: 04 Apr 2019

### Citation:

González AE, Llansó L, Urra X, Parellada E. Auditory Musical Hallucinations by Megaphone: As Debut of Late-Onset Acute Psychosis. *World J Psychiatry Ment Health Res.* 2019; 3(1): 1017.

**Copyright** © 2019 Ariadna E González. This is an open access article distributed under the Creative Commons Attribution License, which permits unrestricted use, distribution, and reproduction in any medium, provided the original work is properly cited.

## Abbreviations

LOAP: Late-Onset Acute Psychosis; VMH: Verbal-Musical Hallucinations; EEG: Electroencephalogram; MRI: Magnetic Resonance Imaging; PET: Positron Emission Tomography; ORL: Otorhinolaryngology; MMSE: Mini Mental State Examination; MOCA: Montreal Cognitive Assessment; DLB: Dementia with Lewy Bodies; REMBD: Rapid Eye Movement Sleep Behaviour Disorder

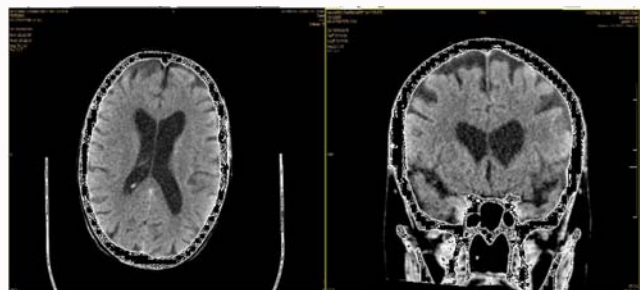
## Introduction

The presentation of late-onset acute psychosis is characterized by delusions, visual hallucinations (30%), auditory hallucinations (10%), paranoid interpretations (errors in perception) and other Schneider symptoms [1]. A verbal-musical hallucination is a more complex perception than tinnitus, having a verbal and/or musical content, without self-consciousness of the stimulus inexistence in the environment (which is defined by hallucinosis). Musical hallucinations which appear in elderly women with deafness or brain disease, but without a psychiatric illness' history, are usually persistent and continuous [2].

According to literature, some triggering factors are often present in verbal-musical hallucinations, for example: People with hearing loss, psychiatric disorders, a paroxistic bioelectric activity, focal brain lesion, thalamus-striatum calcifications from hypoparathyroidism, the reduction of cholinergic neurons that occurs with aging, neurodegenerative disorders, metabolic causes and infections [3].

## Results

We present the case of a 73-year-old female patient, Caucasian, of Spanish origin and left-handed. She is a retired secretary, independent for the basic daily activities. Her medical history of



**Figure 1:** CT scan showing ventricular enlargement and mild frontotemporal atrophy.

hypothyroidism and dyslipidemia is under pharmacologic treatment. No own nor familiar psychiatric history. There is no history of alcohol, nicotine nor drug abuse or some kind of sexual or physical abuse. At this time, she is under treatment with natural products for weight loss and against hair loss. She seeks medical help accompanied by her husband after experiencing verbal and musical hallucinations during 3 months, with high emotional and behavioral impact for both.

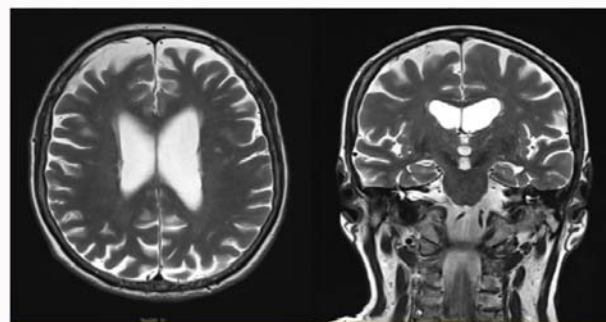
Specifically, she hears a male voice, identifying it as Ignacio's, her husband's ex-boss, talking to her through a megaphone (this is an instrument that amplifies sounds), singing her name and begging to marry her. On one occasion during nighttime, the voice says that he is dying and gives her an address, so she wakes up her husband and asks him to drive her where the voice requests in order to save him.

She described that "the melody through the megaphone was harmonious", she used to hear it in both ears, initially as whispers but then the volume of the voice increased. It contained nice short loving sentences that made her feel flattered. But afterwards the voices turned threatening and she started hearing them more frequently, which made her feel uncomfortable. She experienced alteration in her maintained sleeping pattern. Sometimes she seemed frightened for example in unknown places. She started to neglect some daily household chores. The patient never presented these kinds of hallucinations before. Also, she denies hyposmia, constipation, depression, symptoms compatible with REMBD or extrapyramidal symptoms.

On admission, she appears treatable, cooperative, oriented in person, place and time. She shows poor syntonic contact, acts childish, without alterations in the attention or the speaking, with mnesic deficits and tendency for confabulation. She also displayed hyperthymia and circumstantial speech with paranoid ideas of erotomaniac, mystical and megalomaniac type: "Ignacio wants to be a priest to marry me, and he can only do it because I am a Saint." During her stay at the hospital, she had delirious ideas of prejudice ("Ignacio wants to marry me to get my properties") and paranoid ideas about the neighbors talking about her, as well as getting convinced of being a victim of cyber bullying according to a newspaper article she read. She had no current insight.

Physical and neurological examinations were anodyne except for mild bilateral dysdiadochokinesia. The chest X-ray was normal and an EEG did not reveal any epileptic activity.

Drugs in urine sample were negative. The blood analysis showed hypothyroidism (TSH: 5.447 A/m UIL; T4 1.24 mg/dl), and for that reason we increased the dose of levothyroxine from 75 to 100 mcg/daily. The rest of the parameters were within normal range, including



**Figure 2:** MRI multiple diffuse hyperintense lesions in white matter, mainly in frontobasal and arietal cortex I.

VDRL.

Otorhino examination showed cerumen clogging the audio channel without auditory deficit. The CT scan showed dilated ventricles and mild fronto-temporo-parietal atrophy (Figure 1). MRI showed multiple diffuse hyperintense lesions in white matter, mainly in frontobasal and parietal cortex, and also in the cerebellar hemispheres (Figure 2), suggesting chronic microvascular lesions. A FDG-PET was performed and showed slight frontal bilateral hypometabolism of right predominance (Figure 3). At the time of the hospitalization of the patient the possibility existed to perform the FDG-PET scan before the DAT scan.

Neuropsychological evaluation: Alterations in visioconstructive memory (Figure 4) and executive functions, codification, and short-term memory. Difficulty in learning, lack of self-planning and structuring the execution.

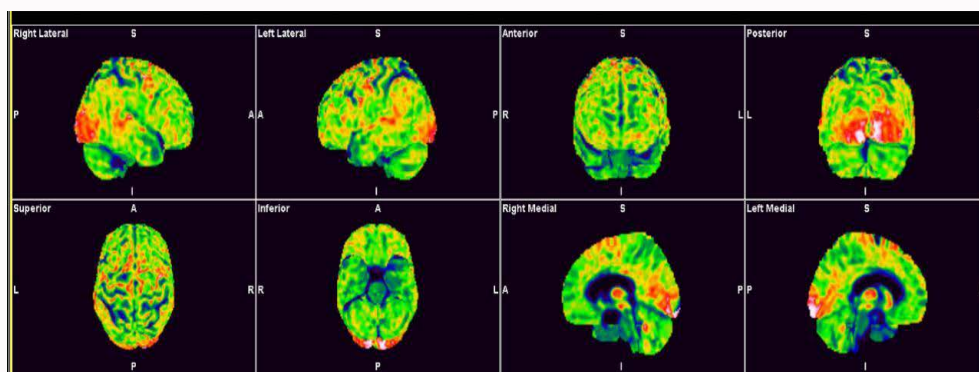
Following tests were performed:

- WAIS (Wechsler Adult Intelligence Scale): 110-119 Direct DIGITS (Dd) 50. Inverse digits (Di) 55
- MMSE (Minimental State Examination): 28/30
- MOCA (Montreal Cognitive Assessment): 23/30
- The Watch test Low capacity and visioconstructive planning
- Figura del Rey (COWAT) (Figure 4) (TFCR) 26, (AVLT-II) 33, (TFCR) copia 26, (AVLT) 35.
- WCST (Wisconsin Card Sorting Test) Perseverance in the errors.
- TMT (Trail Making Test) (TA) 63 (TB) 57

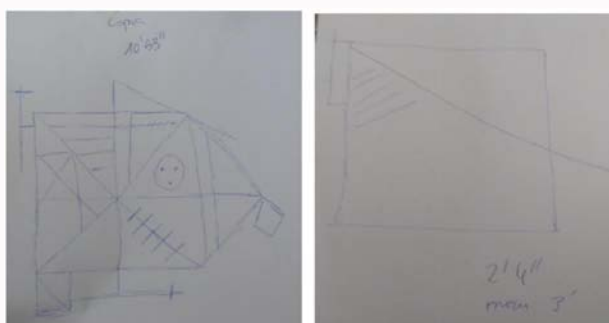
We started oral risperidone 3 mg per day, increasing the dose progressively up to 6 mg (3-0-3), without extrapyramidal side effects and with partial remission of the VMH that decreased to intensity 3/10. After one month of stay and a partial remission of the symptoms she was discharged from the hospital. Upon discharge, certain paranoid ideas persisted regarding the cyber bullying, but there was improvement of the insight, which allowed her to function under supervision.

## Discussion

To make the final diagnostic of this case we based ourselves on the clinical history, the physical exam, the mental exam, blood results, neuro-imaging and neuro-psychological evaluation, and supported by criteria of the manual of DSM-5 and ICD-10 [4,5].



**Figure 3:** Fluorodeoxyglucose-PET Slight frontal bilateral hypometabolism of right predominancy; Axial, Coronal and Sagittal views.



**Figure 4:** Rey Figure in the Neuropsychological evaluation shows clear alteration of the visuoconstructive function.

Since facing a late-onset acute psychosis, we take into account the clinical symptoms and the time of evolution, searching for potential causing and triggering factors.

We initially discard the most probable causes: Otorhinolaryngological (she had no hypoacusia), Drug abuse (we didn't find any evidence of possible trigger in her natural medication), Metabolic causes (such as hypo/hyperthyroidism, the correction of hormone levels didn't improve the psychotic symptoms), Temporary epilepsy (normal EEG), Infections (negative for neurosyphilis and aids), We concluded DLB to be highly unlikely because of the absence of pre-motor symptoms (REMBD, hyposmia, depression, constipation) and no appearance of extrapyramidal motor symptoms after high doses of risperidone [6-8]. Moreover, she had never presented visual hallucinations. The cerebral CT scan and MRI showed frontoparietal atrophy and focal lesions in the CNS compatible with mild microangiopathy.

Therefore, the results of the brain imaging and neuropsychological evaluation suggest a probable cognitive impairment of vascular origin that presented itself with VMH as the initial symptoms [9-11].

We point out that the frontoparietal lesions and cerebellar scars detected could have influenced the clinical presentation, not only as a cause of vascular cognitive impairment, but also as these areas are considered modulating beams in the auditory afferent pathway, concretely on the ascendant reticular activating system that connects the cochlear nucleus with the auditory thalamus [12,13].

We are interested to follow the clinical evolution of this patient.

The patient consents with this clinical paper. She and her family will remain anonymous.

## Conclusions

This case highlights the significance of proceeding with an extra complementary clinical examination and the neuropsychological evaluation in elderly patients with verbal-musical hallucinations. Despite not having primary psychiatric history the Late-onset acute psychosis in this patient was induced by multiple vascular lesions. The hallucinatory symptoms of musical type are particular in this patient, being a sign of alert that urged the search for probable causes. In this case the combination of all the clinical exams, clinical tests, the neuro-imaging, the neuro-psychological tests and the knowledge obtained from her clinical history lead us to the diagnosis of vascular cognitive impairment.

All these symptoms in patients with cognitive problems cause discomfort and tension as caregivers and personal doctors, mainly due to changes in behavior and difficult treatment. Knowing the diagnosis and how to handle it improves the quality of life of the patient and his family.

## References

1. Elias-Villanueva MP, Fernandez-Guardiola M, Ortiz-Martin A, Gallego-Villalta S. [Psicosis de inicio tardío.] *Psicogeriatría*. 2011;3(1):37-9.
2. Berrios GE. Musical hallucinations. A historical and clinical study. *Br J Psychiatry*. 1990;156:188-94.
3. Fischer CE, Qian W, Schweizer TA, Millikin CP, Ismail Z, Smith EE, et al. Lewy bodies, Vascular risk factors, and Subcortical arteriosclerotic leukoencephalopathy, but not alzheimer pathology, are associated with development of psychosis in Alzheimer's disease. *J Alzheimers Dis*. 2016;50(1):283-95.
4. American Psychiatric Association. *Diagnostic and Statistical Manual of Mental Disorders (DSM5)*. 2013.
5. OMS. *International Statistical Classification of Diseases and Related Health Problems (ICD)*. 2016.
6. Wong A, Lau AY, Yang J, Wang Z, Liu W, Lam BY, et al. Neuropsychiatric Symptom Clusters in Stroke and Transient Ischemic Attack by Cognitive Status and Stroke Subtype: Frequency and Relationships with Vascular Lesions, Brain Atrophy and Amyloid. *PloS One*. 2016;11(9):e0162846.
7. Tsunoda N, Hashimoto M, Ishikawa T, Fukuhara R, Yuki S, Tanaka H, et al. Clinical Features of Auditory Hallucinations in Patients With Dementia With Lewy Bodies: A Soundtrack of Visual Hallucinations. *J Clin Psychiatry*. 2018;79(3).
8. Robles Bayón A, Tirapu de Sagrario MG, Gude Sampedro F. [Auditory hallucinations in cognitive neurology.] *Neurología*. 2017;32(6):345-54.
9. Tu MC, Huang WH, Hsu YH, Lo CP, Deng JF, Huang CF. Comparison

- of neuropsychiatric symptoms and diffusion tensor imaging correlates among patients with subcortical ischemic vascular disease and Alzheimer's disease. *BMC Neurol.* 2017;17(1):144.
10. Smith E. Vascular Cognitive Impairment. *Continuum (Minneapolis, Minn.)*. 2016;22(2 Dementia):490-509.
11. McKeith IG, Boeve BF, Dickson DW, Halliday G, Taylor JP, Weintraub D, et al. Diagnosis and management of dementia with Lewy bodies: Fourth consensus report of the DLB Consortium. *Neurology.* 2017;89(1):88-100.
12. Luque R, Sarramea F. Alucinaciones musicales: revisión histórica y conceptual a propósito de de casos. *Psiquiatría biológica.* 2000;7:44-8.
13. Álvarez-Linera Prado J, Jiménez-Huete A. Neuroimaging in dementia. Clinical-radiological correlation. *Radiologia.* 2019;61(1):66-81.