



## Atypical Age Presentation in a Classical Osteosarcoma

Njeze NR<sup>1</sup>, Agu OD<sup>2\*</sup>, Uduma FU<sup>3</sup> and Obikili EN<sup>1</sup>

<sup>1</sup>Department of Radiation Medicine, University of Nigeria Teaching Hospital, Nigeria

<sup>2</sup>Department of Radiology, Enugu State University of Science and Technology, Nigeria

<sup>3</sup>Department of Radiology, University of Uyo, Nigeria

### Abstract

**Background:** Osteosarcoma is the commonest primary malignant bone tumor in children and young adults. The peak incidence occurs in the second decade of life. It is found primarily around the knee and is commoner in males. This case is reported to raise awareness that osteosarcoma can occur at any age.

**Case Description:** A 36-year-old female developed a low grade pain around the left knee joint, which later became severe. Ulceration and swelling followed an attempt by a traditional healer to excise the lesion. Classical radiological features of osteosarcoma were demonstrated and diagnosis was later confirmed on histology.

**Conclusion:** This case shows that, although the incidence of osteosarcoma is highest during the period of maximum bone growth, the tumour is not limited to growing bones.

**Keywords:** Classical; Osteosarcoma; Atypical Age; Tumour

### Introduction

Osteosarcoma or osteogenic sarcoma is a malignant tumour of the bone with abnormal proliferation of osteoblasts [1]. The highest incidence is in the second decade of life, which coincides with the period of maximum bone growth [1]. A second peak incidence is observed in adults after the age of 50 [2]. At this stage, the tumour will involve the axial skeleton and flat bones as a result of malignant transformation from pre-existing conditions like Paget disease, irradiation, osteochondromas and other benign bone processes [2,3]. Hence, diagnosis of osteosarcoma in the third and fourth decade of life requires credible radiological evidence as well as histological confirmation.

### Aim

Raising awareness that osteosarcoma may occur at any age using a case reporting.

### Case Presentation

NE is a 36-year-old female who presented at the National Orthopedic Hospital Enugu, with gross exuberant painful outgrowth and associated necrotic areas around the left knee and distal thigh. Prior to the outgrowth she developed a low grade pain at the site, which later became severe. Ulceration and swelling followed an attempt by a traditional healer to excise the lesion.

On examination, the patient had an exuberant ulcer and fluctuant tender swelling of the distal third of the left thigh and knee. She was markedly pale and emaciated. The blood pressure and pulse were within normal limits. She was admitted and stabilized while laboratory and radiological investigations were being done. The laboratory investigations carried out were full blood count which showed PCV of 23% and WBC of 21,600 mm<sup>3</sup>. The erythrocyte sedimentation rate was 150 mm/1<sup>st</sup> Hr and the viral screenings (HIV, HBV and HCV) were negative. A clinical diagnosis of osteomyelitis was made, with osteosarcoma as a differential.

The radiological investigations included an abdominopelvic ultrasound scan which was normal, posteroanterior chest radiograph (Figure 1) which showed nodular opacities at the right lower and left middle lung zones (arrows). The plain radiograph of the left knee showed a huge dense mass around the knee with both bone and soft tissue involvement. The mass shows densely sclerotic areas of lucency, multi lamination and destruction of the cortices with spiculated and sunburst periosteal reactions, indicating an aggressive process. The soft tissue extension appears as cloudlike areas of

### OPEN ACCESS

#### \*Correspondence:

Agu OD, Department Of Radiology,  
Enugu State University of Science  
and Technology, Teaching Hospital,  
Parklane Enugu, Nigeria,  
E-mail: donagu2014@gmail.com

Received Date: 15 Jul 2019

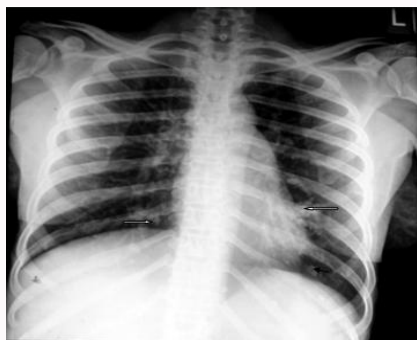Accepted Date: 11 Sep 2019

Published Date: 18 Sep 2019

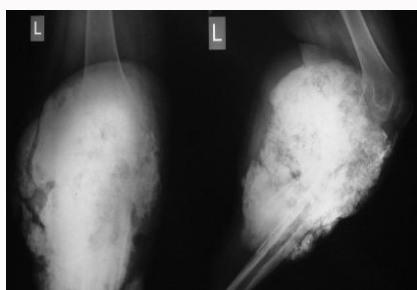
#### Citation:

Njeze NR, Agu OD, Uduma FU, Obikili  
EN. Atypical Age Presentation in a  
Classical Osteosarcoma. *Radiother  
Oncol Int.* 2019; 1(1): 1003.

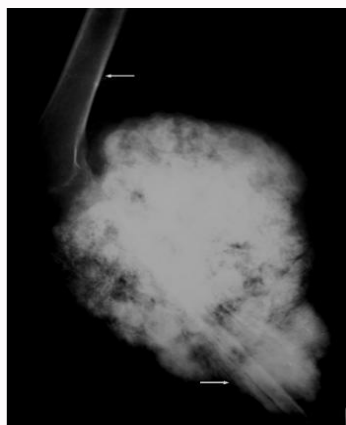
Copyright © 2019 Agu OD. This is an  
open access article distributed under  
the Creative Commons Attribution  
License, which permits unrestricted  
use, distribution, and reproduction in  
any medium, provided the original work  
is properly cited.



**Figure 1:** Posteroanterior plain radiograph showing nodular opacities (metastases) bilaterally at the lower lung zones (arrows).



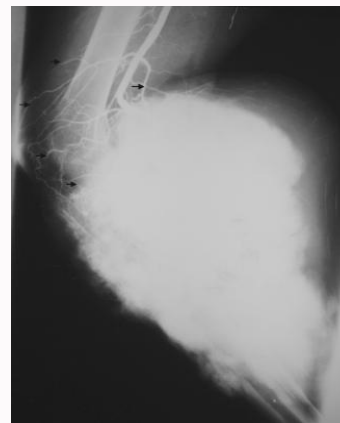
**Figure 2:** Plain radiograph of the left knee demonstrating huge dense mass around the knee with bone and soft tissue involvement. The mass shows densely sclerotic areas of lucency, multilamination and destruction of the cortices with spiculated and sunburst periosteal reactions, indicating an aggressive process. The soft tissue extension appears as cloudlike areas of sclerosis enveloping the knee joint, giving a 'bundle-of-cotton wool' appearance.



**Figure 3:** Plain radiograph of distal femur and proximal tibia radiograph showing profusely calcified osseous mass with soft tissue extension. Linear and sunray periosteal new bone were also observed (arrows).

sclerosis enveloping the knee joint, giving a 'bundle-of-cotton wool' appearance (Figure 2,3). A left femoral arteriography (Figure 4) demonstrated a huge hypervascular mass.

Excision biopsy of a 5 cm bony wedge with muscle elements was confirmed to be osteosarcoma on histology. A definitive diagnosis of osteosarcoma with pulmonary metastasis was made. The patient was stabilized with antibiotics, analgesics, hematinics and intravenous fluids. She also had multiple courses of blood transfusion. The patient later had a left above-knee amputation and was placed on courses of



**Figure 4:** Left femoral arteriography showing marked hypervascularity of the large dense mass (arrows).

chemotherapy. Her post-operative condition was satisfactory. She improved markedly and had since been discharged home and advised to be coming for regular check up and rehabilitation.

In summary, a case of primary osteosarcoma at a most unlikely age of 36 years is reported. Osteosarcoma is usually prevalent during the second decade of life, which coincides with the period of maximal bone growth [3].

## Discussion

Osteosarcoma is known to occur in the age range of 15-29 years [1]. This coincides with the period of maximum bone growth. Another peak is in the elderly where it is secondary to benign bone lesions [3,4]. Interestingly, the age our patient presented falls outside of these two age peaks. This non-consonant age presentation drew our attention to this documentation.

There are some noteworthy features of our index patient. Most important is the late presentation. The presenting complaints in osteosarcoma as in the index case include pain in the affected limb, swelling, or a noticeable mass in the arm or leg [5]. Tenderness, venous engorgement, restriction of movement and pyrexia simulating osteomyelitis are other clinical findings [1,4]. A small proportion of patients present with pathological fracture, a feature that is associated with a worse prognosis [5]. Our indexed patient displayed almost all of the above features aside from pathological fracture. This late presentation which seems to be common in our clime for obvious reasons is among factors underlying the choice of management. This involves above knee amputation and chemotherapy as witnessed by our patient. The late presentation also opens up mimics for soft tissue swelling in the limbs like cellulitis, osteomyelitis, trauma and benign bone tumors [1,4]. This now drew attention to diagnostic modalities available locally to establish the diagnosis. In the absence of functioning CT and MRI, we utilized plain radiography and angiography. Angiography can be used to establish the extent of tumour if surgical treatment and prosthetic replacement are being considered [6-8]. The hypervascularity shown on conventional angiography usually suggest an aggressive tumour as seen in the patient presented. The aggressiveness of this tumour was further shown in this patient from the plain radiographic features of adjacent soft tissue invasion and mineralization. These entire features led credence to the late patient presentation and the consequent management. Since the prognostic factors in osteosarcoma depend on the stage at which treatment is

commenced and initial response to therapy, late hospital presentation results in high morbidity, amputation (as in the index) and most times mortality [4,9,10].

## Conclusion

A case of primary osteosarcoma at a most unlikely age of 36 years is reported to raise awareness that osteosarcoma may occur at any age.

## References

1. Adeniran JJ, Samuel EU, Dike OC, Olayinka SO, Ayokunle O, Nnodu OE, et al. Bone malignancies in orthopaedic hospital igbobi lagos, Nigeria. Niger Postgrad Med J. 2014;21(1):66-7.
2. Katchy KC, Ziad F, Alexander S, Gad H, Abdel Mota'al M. Malignant bone tumors in Kuwait: A 10 -year clinicopathological study. Int Orthop. 2005;29(6):406-11.
3. Cristina W, Adriana AH, Janete DA, Luiz Antonio GC. Imprint cytology of osteosarcoma of the jaw: a case report. J Med Case Reports. 2009;3:9327.
4. Geoff H. Osteosarcoma. Available at: [emedicine>specialties>radiology](#); Updated: 2008. 2015.
5. Perry N, Chauhan A. Radiological casebook Butterworth & Co Kent England. 1988;6:42.
6. Charles TM, Harris G. Osteosarcoma. 2015.
7. Eyesan SU, Obalum DC, Nnodu OE, Abdulkareem FB, Ladejobi AO. Challenges in the diagnosis and management of musculoskeletal tumours in Nigeria. Int Orthop. 2009;33(1):211-3.
8. Mark C, Iain W. Tumours and Tumour-like Conditions of Bone. In: ed. Sutton D; Textbook of Radiology And Imaging 7<sup>th</sup> Edition. 2002;(39):1261-8.
9. Katchy AU, Nwankwo OE, Chukwu CO, Osisioma EC. Osteosarcoma seen at the National Orthopaedic Hospital, Enugu - A retrospective review of 20 cases. Latin American and Caribbean Centre on Health Sciences Information. 2015.
10. Biruk LW, Daniel A, Bayush EN, Mihiret WT. Osteosarcoma of limb bones: a clinical, radiological and histopathological diagnostic agreement at Black Lion Teaching Hospital, Ethiopia. Malawi Med J. 2009;21(2):62-5.