



Ascending-to-Supraceliac Abdominal Aortic Bypass for Complex Coarctation, Recoarctation and Aortic Arch Obstruction in Adults: A 20-Year Postoperative Appraisal

Lakshmi Kumari Sankhyan¹, Ujjwal Kumar Chowdhury^{1*}, Niwin George¹, Suruchi Hasija², Priya Jagia³ and Danishwar Meena¹

¹Departments of Cardiothoracic and Vascular Surgery, All India Institute of Medical Sciences, India

²Department of Cardiac Anaesthesia, All India Institute of Medical Sciences, India

³Department of Cardiac Radiology, All India Institute of Medical Sciences, India

Abstract

Background: Use of the supraceliac segment of abdominal aorta for ascending aorta-to-abdominal aorta bypass has been poorly documented for coarctation of aorta and interrupted aortic arch presenting in adults as an alternative to decrease the high complication rate associated with anatomic repair.

Patients and Methods: Between January 1998 and September 2018, 16 consecutive patients underwent ascending aorta-to-abdominal aorta bypass in the supraceliac bare area for adult coarctation of aorta and interrupted aortic arch. Age ranged from 18 to 60 years. Indications were coarctation of aorta (n=10), aortic arch interruption (n=3), long segment coarctation of aorta (n=1) and recurrent coarctation of aorta not amenable to endovascular intervention (n=2).

Results: There was no early or late death. There was no spinal cord ischemia, phrenic or left recurrent laryngeal nerve damage, cerebral or coronary steal, chylothorax or massive bleeding. Three patients had paradoxical hypertension, managed conservatively. At a mean follow-up of 10.6 (SD±6.8) years, all patients are in NYHA functional class I and had statistically significant reduction of gradient across the coarctation (p<0.001). Magnetic resonance angiography (n=14) revealed wide, unrestricted anastomoses with no kinking, distortion or anastomotic aneurysms.

Conclusion: On the basis of these results, ascending aorta-to-abdominal aorta bypass in the supraceliac bare area appears to be a versatile technique for relief of coarctation of aorta and interrupted aortic arch presenting in adulthood and eliminates the operative complications associated with anatomical repair. We believe that the absence of mortality and morbidity resulted from careful operative technique and a repair that is well protected deep within the mediastinal space. Long-term evaluation will be mandatory to assess the possible occurrence of specific complications encountered with prosthetic materials.

Keywords: Adult coarctation of aorta; Interrupted aortic arch; Ascending aorta-to-abdominal aorta bypass; Paradoxical hypertension; Complex coarctation of aorta

Introduction

Among the variety of surgical options available for coarctation of the aorta, resection and/or replacement of the diseased aortic segment and restoration of the natural aortic pathway without any residual obstruction is the ideal option [1]. However, such a direct approach may be difficult to perform in those presenting late with diminished elasticity and/or calcification of the vessels, extensive collateral formation at different anatomic levels, unusual anatomic features or previous operations [1-6].

Today, the refinements in extracorporeal circulation and the perfection of synthetic vascular prostheses enable the surgeon to perform even extensive aortic replacement, obviating the need for the ingenious bypass procedures [1-18]. The increasing challenge of having to deal with even the most difficult aortic pathology, however, has led to resurrection of these old techniques.

We present here-in our experience with 16 consecutive patients in whom ascending aorta-to-

OPEN ACCESS

*Correspondence:

Ujjwal Kumar Chowdhury, Department of Cardiothoracic and Vascular Surgery, All India Institute of Medical Sciences, New Delhi-110029, India, Tel: 91-11-26584835; Fax: 91-11-26588663; E-mail: ujjwalchow@rediffmail.com

Received Date: 28 Sep 2018

Accepted Date: 22 Oct 2018

Published Date: 29 Oct 2018

Citation:

Sankhyan LK, Chowdhury UK, George N, Hasija S, Jagia P, Meena D. Ascending-to-Supraceliac Abdominal Aortic Bypass for Complex Coarctation, Recoarctation and Aortic Arch Obstruction in Adults: A 20-Year Postoperative Appraisal. *Ann Short Reports*. 2018; 1: 1024.

Copyright © 2018 Ujjwal Kumar Chowdhury. This is an open access article distributed under the Creative Commons Attribution License, which permits unrestricted use, distribution, and reproduction in any medium, provided the original work is properly cited.

supraceliac abdominal aorta bypass was used for a variety of reasons. The indications, techniques, concerns and results are discussed.

Patients and Methods

This study conforms to the principles outlined in the declaration of Helsinki. Patients were enrolled for this study following institutional ethics committee approval and informed written consent. Medical records were reviewed to obtain demographic characteristics, associated medical conditions, details of operations, results of the echocardiographic examination, cardiac catheterization and magnetic resonance imaging.

Between January 1998 and September 2018, 16 patients with primary coarctation of aorta (n=10), recurrent coarctation of aorta (n=2), aortic arch interruption (n=3) and long segment coarctation (n=1) underwent ascending aorta-to-abdominal aorta (supraceliac) anastomosis using a vascular graft through a median sternotomy and upper median laparotomy.

There were 14 (87.5%) male and 2 (12.5%) female patients with a mean age of 29.8±14 years (range, 18 to 60 years). The commonest symptom at presentation was shortness of breath on exertion in 11 patients, claudication in 9 patients, precordial pain and palpitations in 8 patients and syncope on exertion in 2 patients. All patients had upper-limb hypertension with systolic blood pressure in the right arm ranging from 150 to 250 mmHg (mean, 158.0±20.2 mmHg) and from 70 to 90 mmHg (mean, 79.2±4.5 mmHg) in the lower limb.

One patient had history of hypertensive encephalopathy, 3 (18.7%) patients had congestive cardiac failure and 2 (12.5%) had recurrent coarctation of aorta. Both patients with recurrent coarctation of aorta had undergone resection, end-to-end anastomosis and on lay subclavian flap aortoplasty at 3 months and 4 months of age respectively. Subsequently, they had unsuccessful balloon dilatation. All patients underwent preoperative evaluation by routine chest radiography, 2-dimensional echocardiography and angiocardiography.

Chest roentgenograms showed definitive notching of the ribs in 10 patients and echocardiograms revealed left ventricular hypertrophy in 16 patients. All patients underwent preoperative angiography to demonstrate the anatomy of the coarctation of aorta and to outline the collateral circulation (Figure 1). The aortic systolic gradient across the coarctation of aorta ranged from 80-160 mmHg, with a mean systolic gradient for all patients of 79 mmHg. Associated cardiovascular anomalies included bicuspid aortic valves in 2 (12.5%) patients.

Selection criteria for ventral aorta repair

Thirteen patients underwent ascending aorta-to-ventral aorta bypass as a primary surgical procedure for the late presenters of coarctation of aorta and interrupted aortic arch. Bypass grafting was indicated in the presence of at least one of the following criteria: (i) coarctation of aorta (n=10) or interruption of the aortic arch (n=3) presenting in adults, (ii) recurrent coarctation of aorta (n=2), (iii) long segment coarctation of aorta (n=1), (iv) anatomic presentation as stated above with uncontrolled systemic hypertension (systolic blood pressure more than 140 mmHg) despite therapy with antihypertensive medications (n=16), (v) presence of systemic hypertension as stated above, left ventricular hypertrophy or exercise related hypertension, (vi) residual significant obstruction related to either operated site or to a segment of unoperated hypoplastic arch, (vii) a peak-to-peak

coarctation gradient of at least 20mmHg; however, the presence of low gradient does not preclude the need for intervention secondary to the presence of collaterals. In this setting, a diameter of less than half the aortic diameter at the level of the diaphragm favors intervention, (viii) extensive collateral circulation (n=16), and (ix) "complex" coarctation- a term used in the published literature to describe coarctation of aorta that is associated with other cardiac lesions or is technically challenging to repair. Complex coarctation of aorta include arch stenosis, aortic calcification, long-segment coarctation of aorta, or recurrent coarctation of aorta not amenable to endovascular interventions and/or associated with anastomotic aneurysms [19,20].

All patients (n=16) had three criteria in varying combinations (uncontrolled systemic hypertension, extensive collateral circulatory and calcification of the aortic wall). In 3 patients, bypass grafting was performed as a reoperation after an end-to-end anastomosis.

Surgical Technique (Figure 2A-2D)

Patients underwent a standard median sternotomy and upper median laparotomy. No cardiopulmonary bypass was used on any patient. The supraceliac abdominal aorta was dissected by mobilizing the stomach, dividing the coronate ligament of the left lobe of the liver and mobilizing the right lobe of the liver from the diaphragm. The left crus of the diaphragm were divided in between stay sutures, ensuring not to injure the nearby esophagus. The position of the aorta is to the left side of the esophagus which is identified by the transesophageal echocardiographic probe or a nasogastric tube. Once a satisfactory segment of the supraceliac abdominal aorta was exposed, the aorta was encircled both proximally and distally for safety.

An adequate area of the proximal abdominal aorta was chosen for the distal anastomosis, and a side-biting Satinsky vascular clamp was applied after heparinisation at a dose of 100 units/kg (Figure 2A). The length of the jaws of the clamp should be much longer than the width of the selected graft. The graft used for ascending aorta-ventral aorta bypass were bovine-collagen-impregnated polyester-fiber grafts (Medox™, Woven Hemashield®, Meadox-Boston Scientific Corporation; Oakland, New Jersey) in 5 patients and gelatin impregnated crimped, woven vascular prosthesis (Vascutek Ltd, aTerumo Company, Newmains Avenue, Inchinnan, Renfrewshire, PA4 9RR Scotland) in 11 patients. The graft ranged in size from 16mm-18mm in all patients.

The distal anastomosis was constructed in an end-to-side fashion using a continuous 4-0 polypropylene suture buttressed Teflon pledgets with a goal to obtain a perfect hemostasis and maintain femoral artery pressure of at least 40 mmHg to ensure adequate distal perfusion (Figure 2B). The abdominal aorta is fragile at times and care must be taken to avoid excessive traction of the suture through the delicate aortic tissue. This area is difficult to access once the proximal anastomosis is completed. After ensuring meticulous hemostasis, the divided crus of the diaphragm was re-approximated around the graft-aortic anastomosis with a few tacking sutures to isolate the anastomosis from the esophageal wall. The graft was de-aired and an aortic cross-clamp was applied on the graft away from the distal anastomosis.

An appropriate sized fenestration was created by making a cruciate incision on the diaphragmatic pericardium just anterior to the caval passage (Figure 2C). The graft was tunneled through the fenestration made in the diaphragm and was carried anterior to the inferior vena cava and right pulmonary veins for the proximal

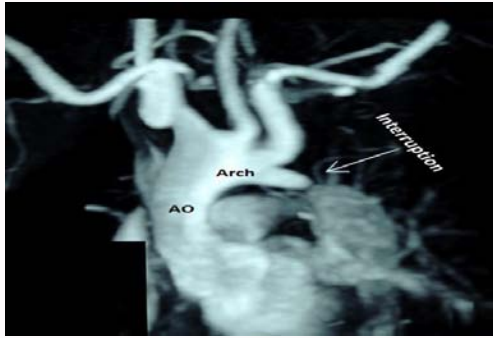


Figure 1: Preoperative magnetic resonance angiogram showing complete interruption of the aortic arch (arrow), dilated aortic arch, ascending aorta (AO) and diffuse narrowing of the upper third of the descending thoracic aorta.

anastomosis along the lateral border of the free wall of the right atrium. We prefer positioning the proximal anastomosis on the far distal portion of the lateral aspect of the ascending aorta as possible, as this will leave the aorta uncluttered for future redo-surgery and the graft length was kept sufficiently redundant for future growth. Finally, a right pleuro-pericardial flap was tacked anterior to the graft to protect it during any potential subsequent sternal re-entry. The proximal anastomosis is performed in the same manner as the distal anastomosis using a partial occluding clamp and a continuous 4-0 polypropylene suture (Johnson & Johnson Pvt. Ltd. Ethicon, LLC, San Lorenzo, USA) (Figure 2D). Mean operation time was 180 ± 35 (120-230) min and ICU stay 1.4 ± 0.6 (1-2) days.

Results

Early results

There was no operative death. None of the patients required reoperation for bleeding. These patients were extubated on the first postoperative day. There was no spinal cord ischemia, phrenic or left recurrent laryngeal nerve damage, cerebral steal or chylothorax. Aortic gradients were obtained in all patients between the right radial artery pressure and left femoral artery pressure. Immediately after surgery, gradients across the aortic coarctation decreased between 10 and 18 mmHg (mean, 12.6 ± 4.0 mmHg).

Within next 24 hours this gradient reduced by another 2-4 mmHg. In all patients, the preoperatively observed chest wall collateral pulsations disappeared, and upper and lower extremity pulses were equal. The upper body systolic pressure decreased from 158.0 ± 20.2 to 126.4 ± 8.2 mmHg at discharge from hospital and 122.0 ± 6.2 at follow-up examination ($p < 0.001$).

Paradoxical hypertension occurred in 3 patients within 36 hours after operation, managed conservatively using antihypertensive medications and ACE inhibitors. Two had normalization of blood pressure within 2 months, and two remains mildly hypertensive, controlled on medications. No abdominal vasculitis was observed. All patients were routinely commenced on β -blockers and oral angiotensin-converting enzyme inhibitors on day 1 postoperatively (0.5-1.0 mg/kg; every 8 hours), prior to weaning from nitroglycerine and sodium nitroprusside. The average stay in the ICU was 2 days (range 1-5 days). The average postoperative stay in hospital was 15.8 ± 6.0 days (range, 10 to 20 days).

Late results

There was no late death. All survivors were periodically evaluated

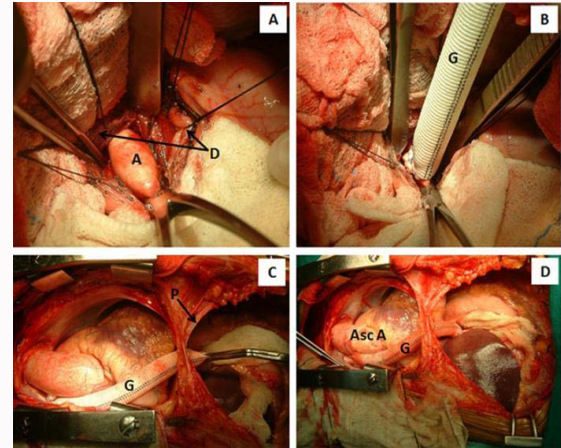


Figure 2: Surgical photographs showing step-by-step bypass graft interposition between the aortic arch and supraceliac abdominal aorta.

A. After dividing the left crus of the diaphragm (D), the supraceliac segment of the abdominal aorta (A) is dissected, isolated, taped and side clamped using a Satinsky side biting vascular clamp.

B. An 18mm woven Dacron graft (G) is anastomosed end-to-side to the abdominal aorta buttressed using Teflon felted sutures thus achieving perfect hemostasis.

C. An aortic cross-clamp is applied over the distal 1/3rd of the prosthetic graft (G), thus restoring unhindered blood flow to the distal abdominal aorta and its vessels. The Dacron graft has been brought within the pericardial cavity by making a cruciate incision in the diaphragmatic pericardium (P) above the caval orifice.

D. The ascending aorta is side clamped at the distal most portion and the proximal graft ascending-aorta anastomosis is performed. Ut most attention has been paid to ascertain the graft length avoiding kinking, distortion or traction on either anastomosis. The intrapericardial portion of the graft is gently positioned anterior to the inferior vena cava and posterolateral surface of the right atrium.

every 6 months by institutional cardiologists and surgeons. Their records were reviewed for all pertinent pre-and postoperative information including echocardiogram, Doppler echocardiogram and magnetic resonance imaging.

They have been followed-up for periods ranging from 12 months to 20 years (mean 10.6 ± 6.8 years). All patients are in New York Heart Association functional class I at their last follow-up visit. Two-dimensional and Doppler echocardiography at the time of discharge did not reveal any pericardial effusion or gradient across the anastomoses in any patients.

The seven normotensive patients who underwent exercise testing had normal blood pressure responses and no increase in aortic gradient. None of the patients had clinical or echographic signs of a restrictive graft. Doppler interrogation of the lower limb arterial system at a mean follow-up of 10.6 ± 6.8 years showed unobstructed flow pattern. MR angiography was performed in 14 patients after 6 months to 11 years. All patients revealed smooth, non-turbulent, pulsatile flow with wide, unrestricted proximal and distal anastomoses with no kinking, distortion or flattening of the bypass graft. There were no anastomotic aneurysms or dissection (Figure 3). Antihypertensive medication was stopped in all but three patients, who were recently operated on.

Discussion

Although coarctation of the descending thoracic aorta generally presents in childhood, a significant percentage of patients do present later in life with primary or recurrent coarctation of aorta

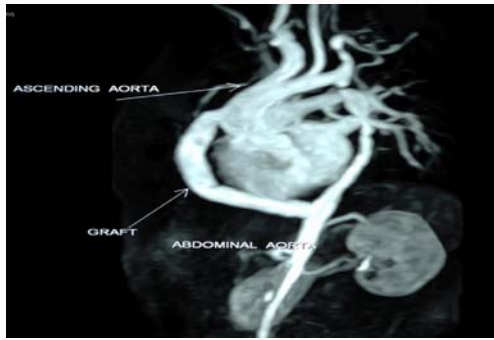

Figure 3: Postoperative magnetic resonance angiogram showing the bypass graft between ascending aorta and proximal abdominal aorta with wide unrestricted proximal and distal anastomoses with no kinking, distortion, flattening of the bypass graft.

[1-7]. Liberthson and colleagues noted that 10.3% (24/234) patients with coarctation of aorta presents after the age of 40.⁷ The rates of recurrent coarctation of aorta repaired in early infancy ranged from 5% to 10% [20,21]. Recurrent coarctation is still a controversial subject, beginning with the proper definition to the best strategy of management. Published literature defines recurrent coarctation of the aorta using different criterions. Some require a blood pressure gradient of more than 20 to 30 mmHg with an imaging modality showing at least 50% narrowing in the descending aorta [1,2]. In the current study, patients who underwent reoperation for recurrent coarctation of aorta had preoperative cross-sectional imaging confirming the recurrence.

Interrupted aortic arch occurs with an incidence of 3 per million live births and 90% of affected neonates die of intractable congestive cardiac failure at a median age of 4 days [22,23]. Published literature documents only 13 cases of isolated interrupted aortic arch surviving to adulthood. Survival into adulthood depends upon the development of substantial collateral circulation [22-26]. These collateral vessels are subject to atherosclerosis, atrophy, aneurysmal dilatation and spontaneous rupture [22-26].

Despite 50-years of experience, surgical repair of coarctation of aorta remains a technical challenge in the subset of older patients with atypical anatomic forms of coarctation of aorta: coarctation of aorta presenting in adolescents and adulthood, long segment coarctation of aorta, aortic wall calcifications, extensive or minimal collateral circulation, and multiple previous operations [1-18]. These patients are exposed to major operative risks with use of various surgical anatomic techniques involving direct exposure of the diseased aorta: end-to-end anastomosis, subclavian flap aortoplasty, subclavian displacement, prosthetic patch aortoplasty, or prosthetic interposition grafting. Specific risks are linked to vessel friability, calcification, dissection in the presence of collaterals, adhesions and/or to the spinal cord ischemia associated with complete aortic cross-clamping [27]. Severe lung disease, large collaterals and lung dysfunction from thoracotomy all present additional technical challenges.

Moreover, late mortality is increased by the presence of hypertension and myocardial hypertrophy, common in these patients [3,28]. Consequently, some investigators have questioned the benefit of surgical intervention in patients older than 40 years [27].

Surgical intervention in adult patients or reoperations resulted in mortality rates of 5% to 10% [27-29]. Graft patching of the restricted

area through a thoracotomy is favored by some investigators but requires extensive dissection posing a risk of intra-operative haemorrhage and injury to the left recurrent laryngeal, phrenic nerves and chylothorax, if cardiopulmonary bypass is required [29]. Graft patching of the arch through a sternotomy requires extensive dissection, circulatory arrest, or a strategy of regional perfusion and poses risk to the left recurrent laryngeal nerve. Paraplegia remains the most feared complication of operation for coarctation of aorta. The possibility of spinal complications after coarctation of aorta repair is 0.5% [12]. Older age is associated with an increased incidence of paraplegia and can reach 5% for patients older than 11 years [2,7,12,30-33]. In an attempt to decrease or eliminate these dreaded complications, anatomic repair of late presenters with coarctation of aorta/interrupted aortic arch, that are related to direct dissection and aortic cross-clamping, several technical modifications have been advanced [1-18].

In an attempt to decrease or eliminate these dreaded complications while performing anatomic repair of the late presenters with coarctation of aorta and/or interrupted aortic arch which are directly related to surgical dissection and aortic cross-clamping, extra-anatomic bypass grafting using a number of different techniques have been employed [1-18].

“...the artery should be taken up at some distance from the diseased part.” An account of Mr. Hunter’s method, communicated in a letter to Dr. Simmons by Mr. Everard Home, Surgeon [34].

Published literature documents the following extra-anatomic bypass techniques for late presenters of aortic coarctation and interrupted aortic arch:

(i) The “very long” aortic graft i.e., a bypass graft extending from the aortic arch to the infrarenal aorta was described by Shumacker in 1959 and from the aortic arch to the common femoral arteries by Robicsek F in 1967 [35,36]. This technique is relatively easy to perform, is well tolerated by most patients and replaced more complicated and higher risk “conventional” operations [11,36].

(ii) Left posterolateral thoracotomy and Dacron graft interposition between the ascending aorta and descending thoracic aorta, parallel to the native aorta without approaching the stenosed aorta (the bucket-handle graft) [9]. This technique derives from the original Clagett operation [8]. Though used mostly in children it may be impossible or risky to obtain an access to the aortic arch via conventional left posterolateral thoracotomy in adults.

(iii) Left posterolateral thoracotomy and left subclavian artery-to-descending thoracic aorta bypass was popularized by Blalock and Park [10]. The pre-requisite for alleviating pre-and post-coarctation gradient is a large subclavian artery, the diameter of which should be close to that of distal thoracic aorta at the level of diaphragm [10].

(iv) A double incision approach has been espoused by some investigators in which ascending aorta-to-descending thoracic aorta anastomosis was performed through left posterolateral thoracotomy and median sternotomy [12,13]. These authors used a separate left thoracotomy for distal aortic anastomosis in 4 patients with recurrent coarctation of aorta followed by a sternotomy for the proximal anastomosis to the ascending aorta. After the distal anastomosis, the graft was routed anterior to the hilum of the left lung. Thoracotomy was closed. After rotating the patient by 45°, median sternotomy and ascending aorta-graft anastomosis was performed on the left lateral

aspect of the ascending aorta.

(v) U-shaped bilateral thoracotomy, graft anastomosis to descending thoracic aorta, tunneled through the pericardium and anastomosed to the right anterolateral surface of the ascending aorta.

(vi) Ascending aorta-to-descending thoracic aorta bypass entirely through a sternotomy incision under cardiopulmonary bypass by avoiding total aortic cross-clamping [14]. These authors brought the distal graft posterior to the left of the heart and anastomosed to the descending thoracic aorta through the left pleural space [14].

(vii) An alternative posterior pericardial approach of extra-anatomic bypass grafting from the ascending aorta to the descending thoracic aorta for aortic arch problems through a right thoracotomy has been described by Arakelyan and associates [37]. Although this approach was not used in our series, it has the advantage of avoiding a redo left thoracotomy, good access to the proximal and distal aorta and ease of performance without utilizing cardiopulmonary bypass.

(viii) Ascending aorta-to-infrarenal abdominal aorta bypass through a combined median sternotomy and laparotomy incision. This technique has been applied in a variety of clinical situations namely, adult coarctation of aorta with left fibrothorax (post tubercular), aortic arch interruption in adults requiring concomitant aortic root replacement [11,15,16]. This approach has been advanced to minimize the morbidity of two or more simultaneous incisions. The disadvantage is the requirement of a very long graft and an additional laparotomy incision.

(ix) A variation of ascending aorta-to-abdominal aorta bypass was described by Cooley and associates in 9 patients. This technique has not been adopted widely [6,17,18,38].

We focused on ascending aorta-to-supraceliac bare area bypass and obtained excellent results without any mortality or spinal cord ischemia, as reported by other investigators [9,13]. We prefer this midline median sternotomy approach because it is simple and safe, as full control of the aorta is easily established. This approach causes fewer respiratory complications, avoids bleeding complications within the chest wall and local site of coarctation of aorta. The other advantages of choosing the supraceliac bare area as the site of choice of distal anastomosis are the following:

- i. This segment of the abdominal aorta is of adequate length to accommodate the graft and uncommonly gets involved in the atherosclerotic disease process;
- ii. Use of this site offers shortest route for course of the graft;
- iii. It minimizes the threat of intestinal complications from erosion or obstruction of adjacent organs, a potential problem when using a longer graft that traverses the peritoneal cavity;
- iv. This technique allows for a shorter abdominal incision and less manipulation of the bowel, resulting in less postoperative ileus; and
- v. The aorta at this site is relatively free of tributaries, lessening the potential of spinal cord devascularisation injuries commonly associated with management of recurrent coarctation of thoracic aorta [17,18].

There were no graft-related complications at a mean follow-up of 12 months 20 years. We did not encounter any pseudo aneurysms, patient-graft mismatch, dissection, infection, graft or anastomotic

narrowing, graft hemorrhage or aorta-to-esophageal fistula. We always interpose the divided crus of the diaphragm around the graft-abdominal aortic anastomosis with a few-tacking sutures to isolate the anastomosis from the overlying gastrointestinal system.

Graft impermeability depends on the porosity and quality of graft healing. Shiya and colleagues postulated that poor tissue growth in the mediastinum and the initial graft expansion observed in woven vascular Dacron graft may contribute to transgraft hemorrhage [39].

In order to prevent transgraft hemorrhage, a third-generation Dacron graft is being developed. It is comprised of a triple layer of standard woven Dacron fused to a polytetrafluoroethylene outer layer by a self-sealing elastomeric membrane, making this graft highly impermeable. Preliminary results are encouraging [40].

Paraplegia is one of the most feared complications after aortic operations and has been reported in patients after reoarctation repair [12]. Clinical and experimental studies have shown that distal aortic pressure more than 70 mmHg preserves spinal blood flow and therefore measurement of distal aortic pressure is indicated in conjunction with the use of somato sensory evoked potentials [30,31]. The use of bypass grafts for adult coarctation of aorta, reoarctation and aortic arch obstruction eliminates the risk of spinal damage associated with anatomic repair in the presence of inadequate collateral circulation and small pressure gradient coarctation of aorta. In the current study, we did not document paraplegia on any patient, which points to the safety of ascending to ventral aorta bypass in the reoperation settings. In fact, a decrease in the risk of spinal cord injury might be expected with this approach because of the location of the distal anastomosis which is made in the supraceliac abdominal aorta. Similar results have been reported in other studies in which this technique has been used [18,32,33].

What should be the size of the bypass graft for interposition between the ascending aorta and ventral aorta?

Published literature including our observations do not provide any conclusive answer. A larger sized graft with disproportionate diversion of blood from the cerebral and cardiac circulation would cause cerebral and coronary stealing phenomenon. Although, there is no current consensus on the size selection, it would appear prudent to size the supraceliac segment of the abdominal aorta with a graft sized and select the graft which will match the abdominal aorta at the level of the diaphragm. In our study group, all patients had graft sizes ranging between 16mm to 18mm. Postoperatively, all patients had systolic pressure gradient across the coarctation of aorta between 10 and 18 mmHg.

Jasper A and associates studied the normal abdominal aortic diameter in Indian population using computed tomography. The reported mean diameter of the descending aorta at the level of the diaphragm was 19.0±2.3 cm in male and 17.1±2.3 cm in female [41]. Similar results have been reported by other investigators with comparable body size [42,43].

Our second concern is the changes in hemodynamics of the thoracic vascular bed after placement of ascending aorta to descending aorta bypass. While preoperatively, because of the gradient across the coarctation, the hypertrophied left ventricle has adapted to high perfusion pressures, a sudden diversion of flow away from the proximal ascending aorta resulting in "normalization" of blood pressure may be inadequate to maintain sufficient myocardial perfusion in hypertrophied left ventricle. With this strategy of

maintenance of postoperative gradient between 10-15 mmHg across the proximal and distal coarctation, there have been no untoward cardiac or cerebral complications secondary to stealing in our series.

Published literature documents older age at repair as a predictor for persistent late systemic hypertension [44-46]. In the current study, all patients had uncontrolled hypertension in the preoperative period. There was significant improvement of blood pressure after the operation and during the follow-up period ($p < 0.001$). The mean systolic blood pressure decreased from 158.0 ± 20.2 mmHg preoperatively to 114 ± 18 mmHg postoperatively, and this improvement persisted during the follow-up period ($p < 0.001$).

There was also a reduction the mean number of anti-hypertensive medications [1.9 ± 1.6 preoperatively to 1.1 ± 0.5 postoperatively ($p = 0.02$)]; however, this difference was not significant at long-term follow-up ($p = 0.09$) which may reflect the older age of the patients at the time of re-intervention.

Published literature documents few concerns of long-term outcome of bypass grafting for late presenters and complex coarctation of aorta. The drawbacks of the prosthetic material include prosthetic thrombosis, infection and false aneurysm formation. These risks have not been stratified by types of bypass grafting (interposition grafting or patch graft aortoplasty), expect for a higher rate of false aneurysm formation with patch graft aortoplasty. Follow-up was longer than 9 years in 9 of our patients. These findings are in agreement with the study of other investigators who reported good results with a follow-up of 3 months to 11 years [13,18,32,47-50].

Our present approach through sternotomy and upper median laparotomy minimizes dissection in the presence of a diseased, friable/calcific aorta, and severe adhesions/fibrosis in the mediastinum, a condition that may lead to uncontrolled operative bleeding, injury to the phrenic and left recurrent laryngeal nerves and chylothorax. Concerns about spinal cord ischemia and renal perfusion, are very much minimized with this technique.

However, we tend to reserve this ascending aorta-to-supraceliac bare area abdominal aortic bypass for adults with complex or recurrent coarctation and are reluctant to use this approach in pediatric patients. The concern is that with ongoing somatic growth, tension will increase on the graft and may be a factor in development of pseudoaneurysm or patient-graft mismatch.

Conclusions

We conclude that ventral aortic repair without cardiopulmonary bypass through a midline posterior pericardial approach in adult coarctation / aortic arch interruption is an expedient, safe and effective technique in adults with coarctation of aorta, interrupted aortic arch, recurrent or complex coarctation of aorta. It avoids extensive network of collateral vessels on the chest wall and at the local site and avoids injury to left phrenic nerve and spinal artery. Knowledge of this approach should contribute to the armamentarium of the vascular surgeon faced with such complex congenital anomalies.

References

1. Warnes CA, Williams RG, Bashore TM, Child JS, Connolly HM, Dearani JA, et al. American College of Cardiology/American Heart Association 2008 guidelines for the management of adults with congenital heart disease. *Circulation*. 2008;118(23):e714-833.
2. Serfontein SJ, Kron IL. Complications of coarctation repair. *Semin Thorac Cardiovasc Surg Pediatr Card Surg Annu*. 2002;5:206-11.

3. Ostermiller WE, Somerndike JM, Hunter JA, et al. Coarctation of the aorta in adult patients. *J Thorac Cardiovasc Surg*. 1971;61(1):125-30.
4. DeLeon MM, DeLeon SY, Quinones JA, Roughneen PT, Magliato KE, Vitullo DA, et al. Management of arch hypoplasia after successful coarctation repair. *Ann Thorac Surg*. 1997;63(4):975-80.
5. Grinda JM, Mace L, Dervanian P, Folliguet TA, Neveux JY. Bypass graft for complex forms of isthmic aortic coarctation in adults. *Ann Thorac Surg*. 1995;60(5):1299-302.
6. Heinemann MK, Ziemer G, Wahlers T, Kohler A, Borst HG. Extraanatomic thoracic aortic bypass grafts: indications, techniques, and results. *Eur J Cardio-thoracic Surg*. 1997;11(1):169-75.
7. Liberthson RR, Pennington DG, Jacob ML, Daggett WM. Coarctation of the aorta: review of 234 patients and clarification of management problems. *Am J Cardiol*. 1979;43(4):835-40.
8. Clagett OT, Jampolis RW. Coarctation of the aorta. *AMA Arch Surg*. 1951;63(3):337-48.
9. Weldon CS, Hartmann AF, Steinhoff NG, Morrissey JD. A simple, safe, and rapid technique for the management of recurrent coarctation of the aorta. *Ann Thorac Surg*. 1973;15(5):510-9.
10. Blalock A, Park EA. Surgical treatment of experimental coarctation (atresia) of the aorta. *Ann Surg*. 1944;119(3):445-56.
11. Robicsek F. "Very long" aortic grafts. *Eur J Cardiothorac Surg*. 1992;6(10):536-41.
12. Brewer LA, Fosburg RG, Mulder GA, Verska JJ. Spinal cord complications following surgery for coarctation of the aorta: a study of 66 cases. *J Thorac Cardiovasc Surg*. 1972;64(3):368-81.
13. Edie RN, Janani J, Attai LA, Malm JR, Robinson G. Bypass grafts for recurrent or complex coarctations of the aorta. *Ann Thorac Surg*. 1975;20(5):558-66.
14. Vijayanagar R, Natarajan P, Eckstein PF, Bognolo DA, Toole JC. Aortic valvular insufficiency and postductal aortic coarctation in the adult: combined surgical management through medial sternotomy: a new surgical approach. *J Thorac Cardiovasc Surg*. 1980;79(2):266-8.
15. Siderys H, Graffs R, Hallbrook H, Kasbecker V. A technique for management of inaccessible coarctation of the aorta. *J Thorac Cardiovasc Surg*. 1974;67(4):568-70.
16. Gelfand ET, Callaghan JC, Sterns LP. Extended aortic bypass. *J Thorac Cardiovasc Surg*. 1980;79(3):381-7.
17. Cooley DA, Norman JC. *Techniques in Cardiac Surgery*. Houston, Texas Medical Press. 1975;17-25.
18. Wukasch DC, Cooley DA, Sandiford FM, Nappi G, Reul GJ. Ascending aorta abdominal aorta bypass: indications, technique, and report of 12 patients. *Ann Thorac Surg*. 1977;23(5):442-8.
19. Connolly HM, Schaff HV, Izhar U, Dearani JA, Warnes CA, Orszulak TA. Posterior pericardial ascending-descending aortic bypass: an alternative surgical approach for complex coarctation of the aorta. *Circulation*. 2001;104(Suppl):I133-7.
20. Said SM, Dearani JA, Burkhart HM, Schaff HV. Extraanatomic bypass graft for recurrent aortic arch obstruction. *Oper Techn Thorac Cardiovasc Surg*. 2012;17(4):261-70.
21. Sweeney MS, Walker WE, Duncan JM, Hallman GL, Livesay JJ, Cooley DA. Reoperation for aortic coarctation: techniques, results, and indications for various approaches. *Ann Thorac Surg*. 1985;40(1):46-9.
22. Levy Praschker BG, Mordant P, Barreda E, Gandjbakhch I, Pavie A. Long-term results of ascending aorta-abdominal aorta extra-anatomic bypass for re-coarctation in adults with 27-year follow-up. *Eur J Cardiothorac Surg*. 2008;34(4):805-9.

23. Collins-Nakai RL, Dick M, Parisi-Buckley L, Fyler DC, Castaneda AR. Interrupted aortic arch in infancy. *J Pediatr.* 1976;88(6):959-62.
24. Messner G, Reul GJ, Flamm SD, Gregoric ID, Opfermann UT. Interrupted aortic arch in an adult: single-stage extra-anatomic repair. *Tex Heart Inst J.* 2002;29(2):118-21.
25. Krishna CS, Bhan A, Sharma S, Kiran U, Venugopal P. Interruption of aortic arch in adults. *Tex Heart Inst J.* 2005;32(2):147-50.
26. Kauff MK, Bloch J, Baltaxe HA. Complete interruption of the aortic arch in adults. *Radiology.* 1973;106(1):53-7.
27. Braimbridge MV, Yen A. Coarctation in the elderly. *Circulation.* 1965;31:209-18.
28. Mathew P, Moodie D, Blechman G, Gill C. Long-term follow-up of aortic coarctation in infants, children and adults. *Cardiol Young.* 1993;3(1):20-6.
29. Sakopoulos AG, Hahn TL, Turrentine M, Brown JW. Recurrent aortic coarctation: is surgical repair still the gold standard? *J Thorac Cardiovasc Surg.* 1998;116(4):560-5.
30. Laschinger JC, Cunningham JN, Nathan IM, Knopp EA, Cooper MM, Spencer FC. Experimental and clinical assessment of the adequacy of partial bypass in maintenance of spinal cord blood flow during operation on the thoracic aorta. *Ann Thorac Surg.* 1983;36(4):417-26.
31. Coles JG, Wilson GJ, Sima AF, Petr Klement, Gordon Tait A. Intraoperative detection of spinal cord ischemia using somatosensory cortical evoked potentials during thoracic aortic occlusion. *Ann Thorac Surg.* 1982;34(3):299-306.
32. Jacob T, Cobanoglu A, Starr A. Late results of ascending aorta-descending aorta bypass grafts for recurrent coarctation of aorta. *J Thorac Cardiovasc Surg.* 1988;95(5):782-7.
33. Karolczak MA, McKay R, Arnold R. Right-sided intrathoracic bypass graft for complex or recurrent coarctation of the aorta. *Eur J Cardiothorac Surg.* 1989;3(3):278-81.
34. Home E. An account of Mr. Hunter's method of performing the operation for popliteal aneurysm. *Lond Med J.* 1786;7(pt 4):391-406.
35. Shumacker HB, King H. Surgical management of rapidly expanding intrathoracic pulsating hematomas. *Surg Gynecol Obstet.* 1959;109(2):155-64.
36. Robicsek F. "Very long" aortic grafts. *European Journal of Cardio-Thoracic Surgery.* 1992;6(10):536-41.
37. Arakelyan V, Spiridonov A, Bockeria L. Ascending-to-descending aortic bypass via right thoracotomy for complex (re-) coarctation and hypoplastic aortic arch. *Eur J Cardiothorac Surg.* 2005;27(5):815-20.
38. Nakamichi T, Katogi T, Ueda T, Aeiba R, Yasudo M, Cho Y, et al. Extra-anatomic bypass from the ascending aorta to the supraceliac abdominal aorta-surgical option applied to reoperation for aortic coarctation or interruption. *Nihon Kyobu Geka Gakkai Zasshi.* 1997;45(10):1690-5.
39. Shiiya N, Kunihara T, Matsuzaki K, Sugiki T. Spontaneous perigraft hematoma suggesting transgraft hemorrhage seven years after thoracic aortic replacement with a Dacron graft. *Eur J Cardiothorac Surg.* 2006;30(2):402-4.
40. De Paulis R, Scaffa R, Maselli D, Salica A, Bellisario A, Weltert L. A third generation of ascending aorta Dacron graft: preliminary experience. *Ann Thorac Surg.* 2008;85(1):305-9.
41. Jasper A, Harshe G, Keshava SN, Kulkarni G, Stephen E, Agarwal S. Evaluation of normal abdominal aortic diameters in the Indian population using computed tomography. *J Postgrad Med.* 2014;60(1):57-60.
42. Davis A, Holloway C, Lewandowski AJ, Ntusi N, Nethononda RM, Pitcher A, et al. Diameters of the normal thoracic aorta measured by cardiovascular magnetic resonance imaging; correlation with gender, body surface area and body mass index. *J Cardiovas Magn Reson.* 2013;15(Suppl 1):E77.
43. Sariosmanoglu N, Ugurlu B, Karacelik M, Tuzun E, Yorulmaz I, Manisali M, et al. A multicenter study of abdominal aorta diameters in a Turkish population. *J Int Med Res.* 2002;30(1):1-8.
44. Toro-Salazar OH, Steinberger J, Thomas W, Rocchini AP, Carpenter B, Moller JH. Long-term follow-up of patients after coarctation of the aorta repair. *Am J Cardiol.* 2002;89(5):541-7.
45. Clarkson PM, Nicholson MR, Barratt-Boyes BG, Neutze JM, Whitlock RM. Results after repair of coarctation of the aorta beyond infancy. *Am J Cardiol.* 1983;51(9):1481-8.
46. Hager A, Kanz S, Kaemmerer H, Schreiber C, Hess J. Coarctation Long-term Assessment (COALA): significance of arterial hypertension in a cohort of 404 patients up to 27 years after surgical repair of isolated coarctation of the aorta, even in the absence of restenosis and prosthetic material. *J Thorac Cardiovasc Surg.* 2007;134(3):738-45.
47. Walter EMD, delMaria Javier MF, Hetzer R. Extra-anatomical bypass in complex and recurrent aortic coarctation and hypoplastic arch. *Interact Cardiovasc Thorac Surg.* 2017;25(3):400-6.
48. Brink J, Lee MGY, Konstantinov IE, Cheung MMH, Goh TH, Bennett M, et al. Complications of Extra-Anatomic Aortic Bypass for Complex Coarctation and Aortic Arch Hypoplasia. *Ann Thorac Surg.* 2013;95(2):676-81.
49. Dodge-Khatami A, Backer CL, Mavroudis C. Risk factors for reoperation and results of reoperation: a 40-year review. *J Card Surg.* 2000;15(6):369-77.
50. Said SM, Dearani JA, Burkhart HM, Schaff HV. Extraanatomic bypass graft for recurrent aortic arch obstruction. *Operative Techniques in Thoracic and Cardiovascular Surgery.* 2012;17(4):261-70.