



Angiofibroma Arising from the Nasal Septum

Dale H Rice*

Department of Otolaryngology-Head and Neck Surgery, Keck School of Medicine, University of Southern California, USA

Clinical Image

A 49 year old Caucasian man presented with a history of 4 to 5 months of progressive right nasal congestion and more recently some slight epistaxis. He was post op two weeks for a partial colectomy for colon cancer. He does have allergies but does not get sinus infections per se. His head and neck examination was normal except for a deviated septum convex to the right. In addition, there was a mass in the right nostril which looked more like an inverted papilloma than a polyp. A CT scan showed a right nasal mass near the head of the inferior turbinate.

He was subsequently taken to the operating room where the mass was found to be attached to the septum. It was completely excised with clear margins without difficulty. The final pathology report proved to be an angiofibroma.

In follow up, the area healed nicely with no evidence of residual or recurrent disease. Of note, he continues to get chemotherapy for his sigmoid colon carcinoma. Juvenile angiofibromas generally occur nearly exclusively in adolescent males, usually presenting either with recurrent epistaxis and or nasal obstruction [1]. As the tumor enlarges other symptoms may develop such as eustachian tube dysfunction, proptosis, diplopia, and cheek swelling.

Nasal examination at this time will usually reveal a unilateral nasopharyngeal mass.

The tumor is extremely vascular on imaging either by CT or MRI. Because of this, it is often treated with embolization preoperatively. Typically now the tumor is removed endoscopically unless it has spread to an area that cannot be reached by that method. The tumor appears to arise from the pterygoid plates and studies have shown that drilling them down at the end of the procedure markedly reduces the recurrence rate [2]. Juvenile angiofibroma have been reported in other age groups but at least 90% are in adolescent males. To our knowledge this is the first reported case of an angiofibroma arising from the nasal septum in an adult male.

OPEN ACCESS

*Correspondence:

Dale H Rice, Department of Otolaryngology-Head and Neck Surgery, Keck School of Medicine, University of Southern California, USA,
E-mail: Dale.Rice@med.usc.edu

Received Date: 15 Dec 2018

Accepted Date: 04 Jan 2019

Published Date: 07 Jan 2019

Citation:

Rice DH. Angiofibroma Arising from the Nasal Septum. *Ann Clin Otolaryngol.* 2019; 4(1): 1034.

Copyright © 2019 Dale H Rice. This is an open access article distributed under the Creative Commons Attribution License, which permits unrestricted use, distribution, and reproduction in any medium, provided the original work is properly cited.

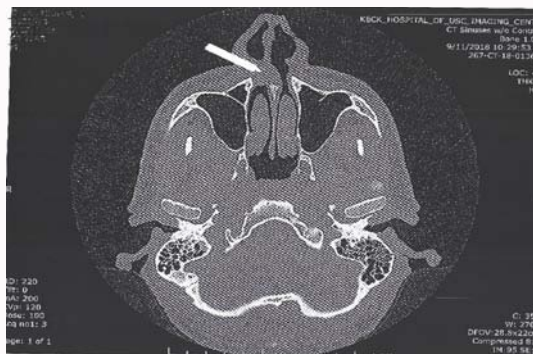


Figure 1: CT scan showing right nasal mass near the head of the inferior turbinate.

References

1. Lopez F, Triantafyllou A, Snyderman CH, Hunt JL, Suárez C, Lund VJ, et al. Nasal juvenile angiofibroma: Current perspectives with emphasis on management. *Head Neck.* 2017;39(5):1033-45.
2. Huang Y, Liu Z, Wang J, Sun X, Yang L, Wang D. Surgical management of juvenile nasopharyngeal angiofibroma. *Laryngoscope.* 2014;124(8):1942-46.