American Journal of Otolaryngology and Head and Neck Surgery

Research Article
Published: 15 Jul, 2021

Anatomic Patterns of the Facial Nerve in Parotidectomized Patients

Pacheco-Ojeda Luis[1], Moncayo-Young Victoria[2], Merlo-Cifuentes Felipe[3], Del Salto-Aguagallo María[4] and Zabala-Parreño Andres[2,3,4,5]*

[1]Department of Head and Neck Surgery, Hospital Metropolitano, Ecuador

[2]Pontificia Universidad Católica, Ecuador

[3]Hospital de Especialidades Carlos Andrade Marín, Ecuador

[4]Hospital Eugenio Espejo, Ecuador

[5]Clinical Microbiology and Molecular Epidemiology MCEP

Abstract

Introduction: The main challenge of parotid surgery is dissection and preservation of the facial nerve. Many studies about its surgical anatomy, based on cadaver dissections, have been reported, but less frequently on patients undergoing parotid surgery.

Objective: The current study aimed to study the diagrammed facial nerves and three morphological parameters.

Methods: The clinical records of patients who underwent parotid surgery at a third level hospital in Quito, Ecuador were reviewed. The facial nerve was diagrammed after dissection, a picture taken, and anatomic measurements registered.

Results: The most common anatomic branching types were I and III, and IA and IB, according to Davis' and Katz's classifications, respectively. Mean value of the angle between the anterior border of the mastoid process and the trunk of the facial nerve was 64º. Mean value of the length of the trunk of the facial nerve was 17 mm, and mean value of the distance between the stylomastoid foramen and the tip of the mastoid process, was 18 mm.

Conclusion: Two surgical landmarks to identify the facial nerve during parotidectomy, not previously described, were analyzed. Firs table, the angle between the anterior border of the mastoid process and the trunk of the facial nerve which may be an important guide for dissection but may vary anatomically or according to the position of an adjacent tumor. Secondly, the distance from the tip of the mastoid process to the stylomastoid foramen which is extremely important for identification on the trunk at the beginning of the surgical procedure.

Keywords: Parotid gland; Facial nerve; Anatomy

OPEN ACCESS

Correspondence:
Pacheco-Ojeda Luis, Department of Head and Neck Surgery, Hospital Metropolitano, Sarmiento de Gamboa Oe 538, 170510, Quito, Ecuador, E-mail: luispacheco.o@hotmail.com

Received Date: *22 Jun 2021*
Accepted Date*: 12 Jul 2021*
Published Date*: 15 Jul 2021*

Citation:
Luis P-O, Victoria M-Y, Felipe M-C, Salto-Aguagallo María D, Parreño Andres Z. Anatomic Patterns of the Facial Nerve in Parotidectomized Patients. Am J Otolaryngol Head Neck Surg. 2021; 4(6): 1143.

Introduction

The main challenge of parotid surgery is dissection and preservation of the facial nerve. Therefore, the knowledge of the anatomy of this nerve is of great importance. A great number of studies on the surgical anatomy of the intra and extraparotid facial nerve dissected on cadavers have been reported [1-4]. However, these types of study on patients who have undergone parotid surgery have been somewhat less frequent [5].

Anatomic branching of the facial was described in the classical studies of Davis and Katz [1,5]. Branching patterns according to Davis description were as follows: Type I, no anastomosis between branches of the facial nerve; type II, anastomotic connection between branches of the temporofacial division; type III, a single anastomosis between the temporofacial and cervicofacial divisions; type IV, a combination of type II and type III; type V, two anastomotic rami passed from the cervicofacial division to interwine with the branches of the temporofacial division; and type VI, plexiform arrangement (Figure 1). In a study of parotid dissection patients, Katz divided facial nerve configurations into five main types: straight branching pattern (type I); a loop involving the zygomatic division (type II); a loop involving the buccal division (type III); a complex pattern with multiple interconnections (type IV); and two main trunks, one major and one minor (type V) (Figure 2).

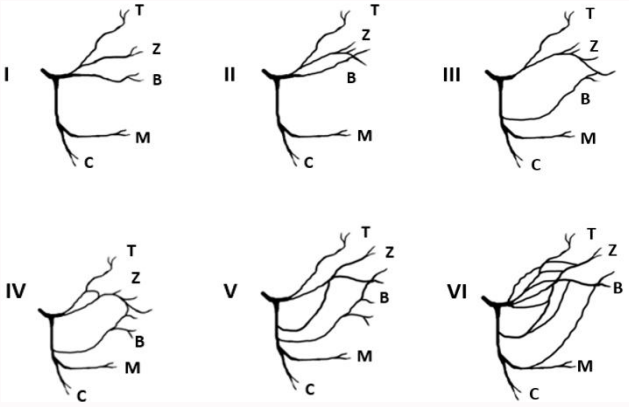

Figure 1: Davis' classification.
T: Temporal branch; Z: Zygomatic branch; B: Buccal branch; M: Mandibular branch; C: Cervical branch

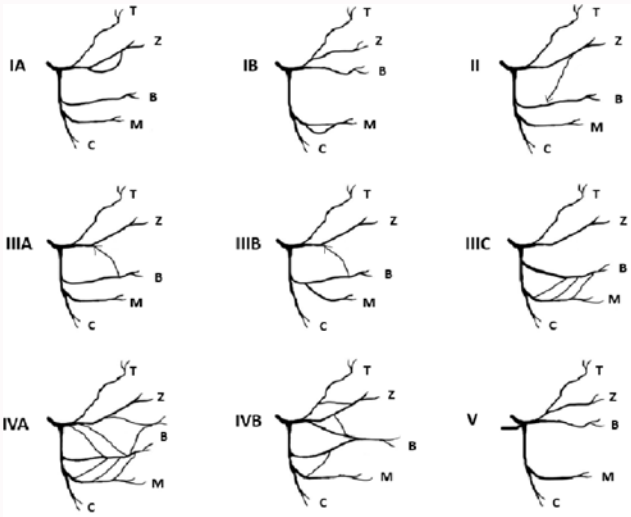

Figure 2: Katz's classification.
T: Temporal branch; Z: Zygomatic branch; B: Buccal branch; M: Mandibular branch; C: Cervical branch

On the other hand, several surgical landmarks to identify the facial nerve during parotidectomy have been described, including the tympanomastoid suture line, the tragal pointer, the posterior belly of the digastric muscle, the styloid process, and the retrograde dissection [6]. The current study aimed to review the facial nerve branching pattern and some dissection useful parameters of the facial nerve morphology in a selected group of patients submitted to parotid surgery.

Material and Methods

The clinical records of 440 patients who underwent parotid surgery by a single surgeon at the third level public hospital, Social Security Hospital, and some private hospitals in Quito, Ecuador, South America, from 1980 to 2020, were reviewed. A Hospital Board permission was obtained. All these patients underwent a superficial, total, or extended parotidectomy (Figure 3) performed as previously described [6]. All of them signed an informed consent before surgery. Mean age of patients of 49 years ± 19.4; 236 were males and 204 females; and 234 were operated for benign lesions and 136 for malignancies.

Figure 3: Type III Davis and II Katz anatomic distribution of the facial nerve after superficial parotidectomy.

The facial nerve was diagrammed after dissection, a picture taken, and additional anatomic elements were measured with a mm-scale ruler and a protractor, at the end of the surgical procedure. Then, data was registered in the clinical records. This study was started prospectively in 1988.

The clinical information of the patients was organized in a database, for subsequent tabulation and analysis using descriptive statistics to determine the percentage frequencies to achieve a distribution of the study variables. They were represented in frequency tables, with the aim of doing a contrast of observed frequencies with those expected.

Results

The extratemporal facial nerve branching pattern was diagrammed in 348 parotidectomies. Anatomic branching of the facial nerve was classified according to Davis' and Katz's descriptions. The most common type found in Davis' classification was type I (57%), followed by type III (19%) and II (18%) (Table 1). In Katz's

Table 1: Anatomic type distribution of facial nerve branching according to Davis' classification [1].

Author(s)	Number of cases	Type (%)					
		I	II	III	IV	V	VI
Davis et al. [1]	350	13	20	28	24	9	6
Bernstein et al. [2]	35	9	9	25	19	22	16
Myint et al. [3]	79	11	16	34	19	7	13
Weerapant et al. [4]	100	1	10	20	18	29	21
The present study	348	57	18	19	3.5	2	0.3

Table 2: Anatomic type distribution of facial nerve branching according to Katz's classification [5].

Author(s)	Number of cases	Type (%)								
		IA	IB	II	IIIA	IIIB	IIIC	IVA	IVB	V
Katz et al. [5]	100	18	6	14	25	13	6	10	4	3
The present study	348	59	13	8	8	1	2	5	4	0

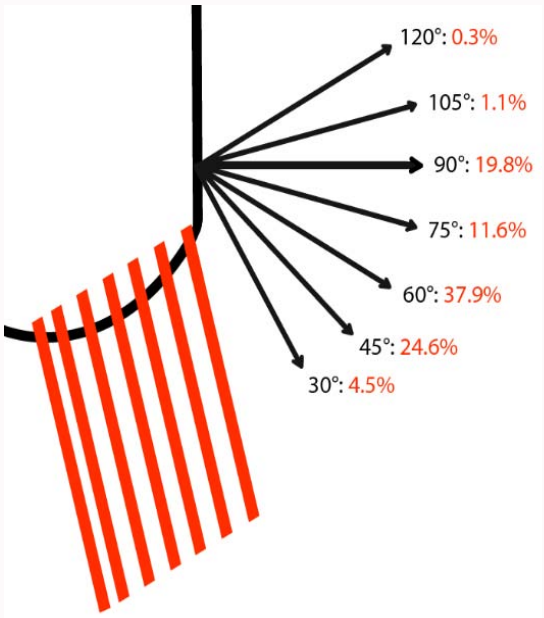

Figure 4: Values of the angle between the anterior borders of the mastoid process and the upper part of sternocleidomastoid muscle, and the trunk of the facial nerve.

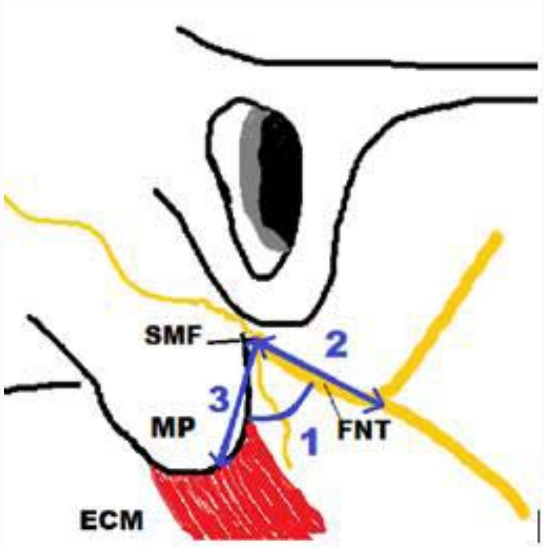

Figure 5: Anatomic parameters: 1. Angle between the anterior borders of the mastoid process and the upper part of sternocleidomastoid muscle and the trunk of the facial nerve, 2. Length of the trunk of the facial nerve, 3. Distance between the stylomastoid foramen and the tip of the mastoid process.
SMF: Stylomastoid Foramen; MP: Mastoid Process; FNT: Facial Nerve Trunk; SCM: Sternocleidomastoiid Muscle

classification, type IA as the most frequent (59%), followed by IB (13%) and IIIA (8.1%) (Table 2).

The following anatomic parameters were also registered:

1. The angle between the anterior borders of the mastoid process and the upper part of the Sternocleidomastoid Muscle (SCM) and the Facial Nerve Trunk (FNT) was measured in 354 patients. The mean value was 64° ± 18.2, ranging from 30° to 120° (Figure 4). The most common value was 60° (Figure 4).

2. The length of the trunk of the facial nerve between the stylomastoid foramen and its division in temporofacial and cervicofacial branches was measured in 301 patients. Mean value 17 mm ± 4.54, ranging from 8 mm to 40 mm (Figure 5).

3. The distance between the stylomastoid foramen and the tip of the mastoid process was also measured in 301 patients. The mean value was 18 mm ± 4.08, ranging from 8 mm to 32 mm (Figure 5).

Discussion

The approach to the facial nerve is vitally important during surgical procedures of the parotid gland for benign or malignant lesions. This applies also to facial plastic surgery, surgery of vascular lesions, and trauma [7-9]. The main concern of the surgeon is the identification and preservation of the facial nerve as well as an adequate parotidectomy including the complete removal of the tumor and the surrounding salivary tissue. Benign tumors are managed with superficial parotidectomy if located in the superficial lobe, or total parotidectomy if located in the deep lobe taking care to preserve the facial nerve. Malignant tumors are treated with total parotidectomy with preservation of the facial nerve if it is not involved with tumor. Otherwise, it must be sacrificed, and a reconstruction attempted. Neck dissection is indicated if clinical lymph nodes are present according to National Comprehensive Cancer Network (NCCN) guidelines. Tumors with adverse features are treated with adjuvant radiation therapy and occasionally with systemic therapy. Parotidectomy can also be performed in case of intraparotid or periparotid metastatic lymph node from another tissue or organ primary, and for chronic sialoadenitis or sialolithiasis.

Regarding the classic surgical landmarks, the tympanomastoid suture line lies between the mastoid and tympanic segments of the temporal bone and is approximately 6 mm to 8 mm lateral to the stylomastoid foramen. The main trunk of the nerve can be found midway between the cartilaginous tragal pointer of the external auditory canal and the posterior belly of the digastric muscle. The nerve is usually located inferior and medial to the tragal pointer [6].

Borle proposed an anatomic triangle to reliably identify the Facial Nerve Trunk (FNT). Description of the lines of this triangle was as following: The first starts at the tip of the mastoid process, running along the superior border of the posterior belly of the digastric muscle; a second line along the posterior border of the ramus of the mandible; and a third line, from the tip of the mastoid process, (angle b) running anteriorly, till it joins the second line. The mean distance of FNT from angle b was found to be 12.18 mm [10].

Other landmarks and anatomic descriptions of the different branches of the facial nerve have been reported due to the particular

attention given when operating in specific regions of the face and, consequently, to minimize damage to them [8].

For the temporal branch, Pitanguy and Ramos described a line starting from a point 0.5 cm below the tragus that extended in the direction of the brow, passing 1.5 cm above the lateral extremity of the eyebrow [11].

We era pant described three landmarks: The vertical distance from the mandibular angle to the marginal mandibular branch, the horizontal distance from the lateral palpebral line to the otobasion superius, and the distance from the lateral palpebral line to the apex of the parotid gland [4].

Sanderson described the average distance, 3.21 cm, from the apex of the tragus to the point where the frontotemporal branch of the facial nerve crosses the inferior border of the zygomatic arch [12].

Furnas also described the vagino-mastoid to guide the exposition of the FNT and the upper and outermost aspect of the eyebrow and the point where a projection of the hairline crosses the zygoma, as a landmark for the temporal branch [13].

Tayebi Meybodi et al. [14] proposed the digastric branch of the facial nerve as a landmark to localize the extratemporal portion of the facial nerve [14].

As Marginal Mandibular Nerve (MMN) injuries have been reported in many head and neck procedures (parotidectomy, excision of the submandibular gland, neck dissection, etc.) several reference points have been described to avoid these lesions. Among them: The gonion, the posterior border of the antegonial notch, the superior arc of the antegonial notch, the anterior border of the antegonial notch, and the facial artery. Only its relationship with the anterior facial vein seems to be constant. This nerve almost always runs superficially [15]. A modern and remarkably interesting method for studying anatomy, Anatomage (Anatomage, Inc., San Jose, CA), was used to study the course of the MMN in the area where it crosses the facial vessels [16].

The current study describes practical and handy landmarks, observed through a long period of surgical practice, to safely identify and dissect the facial nerve. These are the angle between the anterior borders of the mastoid process and of the sternomastoid muscle and the trunk of the facial nerve, the length of the trunk of the facial nerve between the stylomastoid foramen and its division in temporofacial and cervicofacial branches, and the distance between the stylomastoid foramen and the tip of the mastoid process.

The identification of the facial nerve is the most important step at the beginning of the surgical procedure. Once the tail of the parotid gland has been elevated off the SCM until the posterior belly of the digastric muscle and then separated from the cartilage of the tragus and the external auditory canal, great care must be taken to identify the nerve. The main concern is to know how deep the surgeon should dissect to find it. The distance from the tip of the mastoid process to the stylomastoid foramen through which the nerve emerges may vary a lot. So, we measured this distance in our patients. The mean value was 18 mm but it ranged from 8 mm to 32 mm. Sometimes, identifying the nerve takes time and palpation of the styloid process can help.

The length of the trunk of the facial nerve may also vary anatomically. In our patients, the mean value was 17 ± 4.54 mm, ranging from 8 mm to 40 mm. This finding is similar to the report of Salame who found a length of 16.44 ± 3.2 mm in a study in 46 cadavers. The trunk must be dissected as far as the pes anserinus, the structure marking the separation of the cervicofacial (lower) and temporofacial (upper) divisions. These main branches and the smaller distal rami are then followed carefully to map their relation to the tumor and of dissecting free of it.

The angle between the anterior border of the mastoid process and the trunk of the facial nerve may be a guide to the direction of the dissection of the trunk of the nerve. The mean value was 60°, ranging from 30° to 120°. The most common value was 60° (38%). This angle may vary anatomically but, most importantly, according to the position of an adjacent tumor that can deviate the FNT upward or downward. We have not found another report of this anatomic presentation in the literature.

It is well known for the variability of facial nerve branching patterns. For anatomic branching pattern description, we used the classifications of Davis and Katz. We have not found new classifications in the literature. Davis classified the facial nerve configuration in six types based on 350 cadaveric dissections. On the other hand, Katz classified the patterns in 5 main types and 9 subtypes based on surgical dissections of 100 patients undergoing parotidectomy. In cadavers, dissections could extend further to the boundaries of the parotid gland. On the other hand, a surgeon must dissect very carefully the facial nerve to remove, adequately and completely, salivary tissue according to the type of parotidectomy, superficial or total, and the type tumor, benign or malignant.

In Davis' classification, a type was assigned according to the presence and number of anastomotic rami between branches of the temporofacial division, or between the main temporofacial and the cervicofacial divisions. In Katz's classification, types and subtypes were assigned according to the aforementioned anastomosis and, additionally, to the origin of the secondary divisions. In any case, the surgeon must dissect and try to preserve even the anastomotic rami. In our experience, the occasional sacrifice of very tiny anastomotic rami has not resulted in an apparent partial deficit of mobility of the face.

Kehrer reappraised the zygomaticobuccal branch system concerning anastomoses and crossings that could be relevant for facial reanimation surgery [17].

Roostaeian described the safe planes of dissection during surgical undermining to minimize the risk of facial nerve injury during rhytidectomy [7]. An interesting point in this report is the attention to the cervical branch; one of the most commonly injured branches, because of its relatively superficial nature and intimate attachment to the platysma. It can pucker the lower lip. Fortunately, the complete return of function has been reported in nearly all cases of injury of this branch.

Distribution of FN branching pattern comparing to Davis types was very variable in several series (Table 1). In our study, type I classification was the most common (57%) and type VI the least frequent. Type III was more common in Davis', Bernstein's, and Myint's series but type IV was the most frequent in Weerapant's report.

In Katz's original description, 44% of patients had a type III pattern, 24% had an unbranched pattern (type I), and 3% of the patients had two main trunks (type V). We did not find any patient

with the latter type and most of our patients had an unbranched pattern (Table 2).

Adidharma used an *in vivo* Facial Nerve Mapping (FNM) during Vascular Anomaly (VAN) surgeries involving the Facial Nerve (FN) in 67 patients and simplified the facial nerve patterns into two groups: Type 1A included FN patterns with 2 anastomoses (anatomical types I to III) and type 2A contained FN patterns with ≥ 2 anastomoses (anatomical types IV to VI). Additionally, he classified the nerve relationship with mass as through, adherent or separate and the surgical approach as direct, anterograde, or retrograde [9].

Magnetic resonance Diffusion Weighted Imaging (DWI) was conducted on 2 parotid-healthy cadaveric patients, tracking the extracranial course of the facial nerve to provide a reliable facial nerve map [18]. Correlations between imaged tracts and the anatomic course of the extracranial facial nerve were identified to an accuracy of 1 mm. According to the authors, this visualization could have diagnostic implications in differentiating benign from malignant tumors and, crucially, neural involvement.

Conclusion

Anatomical landmarks can be important to visualize and identify the facial nerve during head and neck surgery. We have included additional measurements that have offered a better understanding of the facial nerve anatomy during parotidectomy.

The branching patterns of the facial nerve seem to be highly variable as in previous studies and ours. The main and secondary divisions must be properly identified to avoid injuries during parotid surgery.

References

1. Davis RA, Anson BJ, Budinger JM, Kurth LR. Surgical anatomy of the facial nerve and parotid gland based upon a study of 350 cervicofacial halves. Surg Gynecol Obstet. 1956;102(4):385-412.
2. Bernstein L, Nelson RH. Surgical anatomy of the extraparotid distribution of the facial nerve. Arch Otolaryngol. 1984;110(3):177-83.
3. Myint K, Azian AL, Khairul FA. The clinical significance of the branching pattern of the facial nerve in Malaysian subjects. Med J Malaysia. 1992;47(2):114-21.
4. Weerapant E, Bunaprasert T, Chokrungvaranont P, Chentanez V. Anatomy of the facial nerve branching patterns, the marginal mandibular branch and its extraparotid ramification in relation to the lateral palpebral line. Asian Biomed. 2010;4(4):603-8.
5. Katz AD, Catalano P. The clinical significance of the various anastomotic branches of the facial nerve. Arch Otolaryngol Head Neck Surg. 1987;113(9):959-62.
6. Langerman A, Netterville J. Parotidectomy. Medscape Updated. 2019.
7. Roostaeian J, Rohrich RJ, Stuzin JM. Anatomical considerations to prevent facial nerve injury. Plast Reconstr Surg. 2015;135(5):1318-27.
8. Myckatyn TM, Mackinnon SE. A review of facial nerve anatomy. Semin Plast Surg. 2004;18(1):5-11.
9. Adidharma L, Bly RA, Theeuwen HA, Holdefer RN, Slimp J, Kinney GA, et al. Facial nerve branching patterns vary with vascular anomalies. Laryngoscope. 2020;130(11):2708-13.
10. Borle RM, Hadhav A, Bohla N, Hingnikar P, Gaitwad P. Borle's triangle: A reliable anatomical landmark for ease of identification of facial nerve trunk during parotidectomy. J Oral Biol Craniofac Res. 2019;9(1):33-6.
11. Pitanguy I, Silveira Ramos AM. The frontal branch of the facial nerve: The importance of its variations in face lifting. Plast Reconstr Surg. 1966;38(4):352-6.
12. Sanderson KG, Conti A, Colussi M, Connolly C. A simple clinical application for locating the frontotemporal branch of the facial nerve using the zygomatic arch and the tragus. Am Soc Aesthetic Plast Surg. Aesthet Surg J. 2020;40(5):NP223-7.
13. Furnas DW. Landmarks for the trunk and the temporofacial division of the facial nerve. Br J Surg. 1965;52(9):694-6.
14. Tayebi Meybodi A, Borba Moreira L, Lawton MT, Preul MC. Anatomical assessment of the digastric branch of the facial nerve as a landmark to localize the extratemporal facial nerve trunk. Surg Radiol Anat. 2019;41(6):657-62.
15. Marcuzzo AV, Šuran-Brunelli AN, Dal Cin E, Rigo S, Piccinato A, Boscolo Nata F, et al. Surgical anatomy of the marginal mandibular nerve: A systematic review and meta-analysis. Clin Anat. 2019.
16. Stranzias P, Botou A, Manoli A, Skandalakis PN, Filipou D. Variation of marginal mandibular nerve in a caucasian male cadaver: A study using the anatomage table. Cureus. 2019;11(11):e6168.
17. Kehrer A, Engelmann S, Ruewe M, Geis S, Taeger C, Kehrer M, et al. Anatomical study of the zygomatic and buccal branches of the facial nerve: Application to facial reanimation procedures. Clin Anat. 2019;32(4):480-8.
18. Kininy W El, Roddy D, Davy S, Roman E, O'Keefe V, O'Hanlon E, et al. Magnetic resonance diffusion weighted imaging using constrained spherical deconvolution-based tractography of the extracranial course of the facial nerve. Oral Surg Oral Med Oral Pathol Oral Radiol. 2020;130(2):e44-56.