



An Unusual Presentation of Lemierre's Syndrome: Case Report and Review of the Literature

Chan JKC, Mamun Rashid*, Karagama YG and Bhalla RK

Department of Otolaryngology, Bedford Hospital, UK

Abstract

Objective: We report a rare case of septic arthritis with subsequent diagnosis of Lemierre's syndrome.

Methods: Case report and review of literature concerning the presentation and management of Lemierre's syndrome.

Case Report: A 17-year-old boy presented with shoulder and chest pain proceeded with a three week history of sore throat. CT demonstrated septic arthritis of his right shoulder, a right 3 cm × 6 cm parapharyngeal abscess extending from the base of skull to the thoracic inlet, complicated by right internal jugular vein and subclavian vein thrombosis and multiple lung emboli. Blood culture isolated *Fusobacterium necrophorum*.

Conclusion: There is universal recognition in the literature of the association between presentation of sore throat and Lemierre's syndrome. This case illustrates that a seemingly disparate diagnosis of septic arthritis can also be a consequence of this life-threatening disease. We also highlight the importance of multidisciplinary management and the therapeutic challenges that can face the otolaryngologist.

Keywords: Lemierre's syndrome; Septic arthritis; *Fusobacterium*

Introduction

Of all head and neck infections, Lemierre's syndrome is a life threatening infection of the parapharyngeal space which usually presents as a simple sore throat. It was first described by Andre Lemierre [1] in 1936 following the publication in The Lancet of his case series of 20 patients as an acute anaerobic septicemia which follows an oropharyngeal infection complicated by Internal Jugular Vein (IJV) thrombosis and distant metastasis especially to the lungs. The usual causative organism of this condition is *Fusobacterium necrophorum*, an anaerobic bacterium. The mainstay of treatment is high dose antibiotics for 2 weeks to 6 weeks. We report a case of a 17 year old male who had a rare presentation of septic arthritis as part of Lemierre's syndrome and how prompt management can lead to a satisfactory outcome.

Case Presentation

A 17-year-old previously healthy Caucasian male presented with a three day history of right shoulder and pleuritic chest pain. These symptoms were preceded by a three week history of sore throat. There were no risk factors for venous thromboembolism, no sexual history and the patient had no history of recurrent sore throats. Clinical examination revealed decreased air entry at the left lung base, a tender right shoulder, a right knee effusion and a swollen right calf. Although afebrile at presentation, the White Cell Count (WCC) was raised at $12.8 \times 10^9/l$ with a marked neutrophilia, C-Reactive Protein (CRP) was 286 mg/l and D-dimer was significantly elevated at 7560 ug/l. Liver function tests were mildly deranged with a Bilirubin of 26 $\mu\text{mol/l}$, albumin of 18.5 g/l and Alanine Transaminase (ALT) of 155 IU/L. Paul Bunnell test was negative. A chest X-ray confirmed left lower lobe pneumonia. Initial treatment was commenced for pneumonia, Deep Vein Thrombosis (DVT), reactive arthritis, and possible pulmonary embolism. The patient was commenced on intravenous (iv) broad-spectrum antibiotics and a therapeutic Subcutaneous (SC) dose of Enoxaparin. However, an early Duplex ultrasound of the right leg excluded a DVT, and Enoxaparin was stopped.

The following day, the shoulder pain steadily deteriorated. The patient also complained of dysphagia and odynophagia, and developed swinging pyrexia. Oropharyngeal examination revealed an inflamed and medially displaced right tonsil and a posterolateral pharyngeal wall swelling

OPEN ACCESS

*Correspondence:

Mamun Rashid, Department of Otolaryngology, Bedford Hospital, UK, E-mail: mamunrashid@doctors.org.uk

Received Date: 10 Apr 2020

Accepted Date: 04 May 2020

Published Date: 06 May 2020

Citation:

Chan JKC, Rashid M, Karagama YG, Bhalla RK. An Unusual Presentation of Lemierre's Syndrome: Case Report and Review of the Literature. Am J Otolaryngol Head Neck Surg. 2020; 3(3): 1093.

Copyright © 2020 Mamun Rashid. This is an open access article distributed under the Creative Commons Attribution License, which permits unrestricted use, distribution, and reproduction in any medium, provided the original work is properly cited.

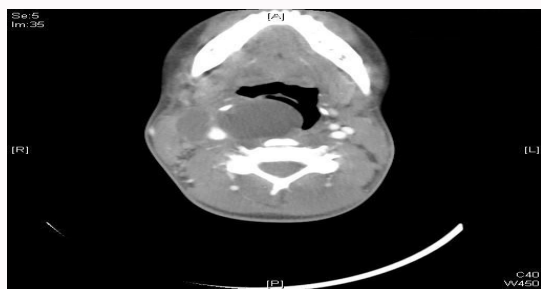


Figure 1: CT neck- Right parapharyngeal abscess.

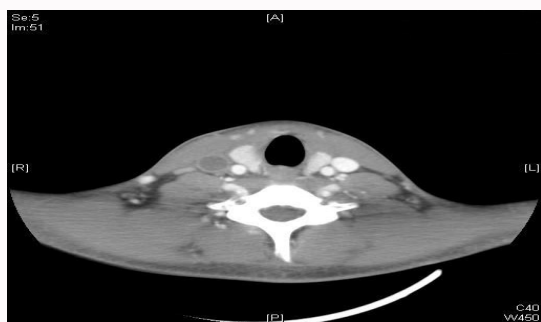


Figure 2: CT neck- Right internal jugular vein thrombosis.

confirmed by fiberoptic nasopharyngoscopy. An urgent CT neck with contrast demonstrated a right 3 cm × 6 cm parapharyngeal abscess (Figure 1) extending from the base of skull to the thoracic inlet, complicated by a left basal pneumonia and right internal jugular (Figure 2) and subclavian vein thrombosis, both of which were later confirmed by Duplex ultrasound scan. An urgent incision and drainage of the right parapharyngeal abscess was performed *via* an external neck incision, at which time 15 ml's of frank pus was drained. A drain was left in-situ postoperatively. A blood culture taken on admission isolated *Fusobacterium necrophorum*. Oral Clindamycin 900 mg tds and Metronidazole 500 mg tds were commenced.

Over the next three days, the right shoulder became more painful and tender, warranting an arthroscopic washout of the glenohumeral joint. Intraoperatively, the joint was found to be inflamed with necrotic tissue, which was excised. Intravenous Gentamicin 240 mg od was added to the antibiotic regime, whilst monitoring the patient's renal function. Culture of aspirated joint fluid at the time of surgery failed to isolate any growth. This may, however, have been due to the ongoing antibiotic therapy. Histology of excised necrotic joint tissue showed only inflammatory cells.

Over the next two days, the patient's pulmonary function continued to deteriorate, with decreased air entry and stony dull percussion notes at the bases of the thoracic cavity. An urgent CT pulmonary angiogram (Figure 3) demonstrated multiple bilateral cavitating nodules in the lungs suggestive of septic emboli from the thrombosed IJV, right lower lobe consolidation with compression atelectasis, bilateral pleural effusions, and hepatosplenomegaly. A repeat CT neck revealed recollection of the parapharyngeal abscess. The CRP and WCC also increased to 297 mg/l and $15.3 \times 10^9/l$ respectively. A drain was therefore re-sited and minimal pus was evacuated. On the advice of the microbiologist, iv Tazocin 4.5 g tds was added to Clindamycin and Metronidazole. Gentamicin and broad spectrum antibiotics were stopped and a chest drain was

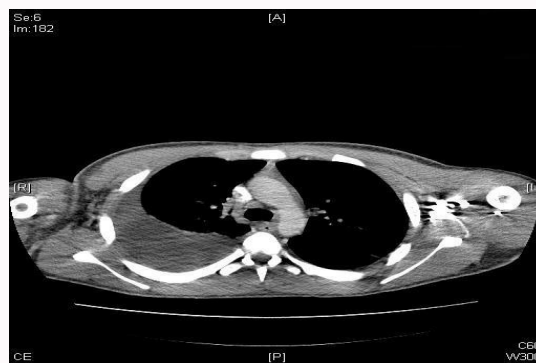

Figure 3: CTPA- Bilateral pleural effusion and cavitating nodules.

inserted. Pleural aspirate demonstrated inflammatory cells only.

It was proposed that the patient might have benefitted from a therapeutic ligation of the right IJV. However in consideration of improving blood parameters together with the limits of the thrombosis being at the jugular foramen superiorly and the thoracic inlet inferiorly, it was decided jointly by the responsible otolaryngologists, vascular surgeons, physicians and hematologists that a conservative approach with prolonged enoxaparin and antibiotics was most appropriate at this stage.

Over the course of next few days, his clinical condition dramatically improved and did not warrant any further intervention. He was later discharged home on long term warfarin.

Discussion

Lemierre's syndrome is characterized by a triad of (i) history of oral anginal illness in the preceding 4 weeks or compatible clinical findings, (ii) evidence of metastatic lesions in lungs or other remote site, and (iii) evidence of IJV thrombophlebitis or isolation of *Fusobacterium necrophorum* or species from blood cultures or a normally sterile site [2]. The condition is rare, with a reported incidence in southwest England of 0.9 cases per million populations per year between 1994 and 1999 [2]. The incidence in males is twice as high as in females and ages affected range from 2 months to 78 years (median 22 years) [3]. The mortality associated with Lemierre's syndrome is 6.4% to 17% [2].

Fusobacterium necrophorum subspecies *Funduliforme* is the usual pathologic agent. Although *F. necrophorum* is the most commonly described pathogen in patients with Lemierre's syndrome, cultured in 81.7% of cases [4], a wide array of other pathogens, including *x.* and *Streptococcus sp.* may also be present.

The disease usually progresses in several sequential stages. The first stage is the primary infection, which is usually pharyngitis in 87.1% of cases [4]. Other primary infections include tonsillitis, mastoiditis, and odontogenic infection [5]. The next stage involves local invasion of the lateral pharyngeal space, and IJV septic thrombophlebitis via tonsillar veins, seen in 71.5% of cases [4]. Infection of the parapharyngeal space may affect the carotid sheath and its contents, and also the lower cranial nerves IX-XII [6]. Neurologic complications can occur as a result of cavernous sinus thrombosis complicating brain abscess [5].

IJV thrombosis acts as a nidus of infection that may spread hematogenously and result in septicemia and septic embolisation, which occur most commonly in the lungs (79.8% of cases) [6]. Pleural complications may include effusions and empyema [6]. Infectious

complications outside the lung include septic arthritis (11%) (One of the main presenting complaints in our case), and osteomyelitis (3%) [2]. The liver may also be adversely affected- jaundice is reported in 11% to 49% of cases [7].

The features of septic pulmonary emboli that can be confirmed on CT with contrast medium include peripheral lesions that show peripheral enhancement with central areas of reduced attenuation, wedge-shaped lesions abutting the pleura, air bronchograms within nodules, and extension into the pleural space [8,9]. CT also has the ability to show distended veins with enhancement of the walls, intramural filling defects, and swelling of adjacent soft tissues [8,10]. Duplex ultrasound scanning has been advocated for imaging jugular venous thrombosis because it is rapid to employ, low cost, non-invasive, can be performed at the patient bedside, and is able to confirm an absence of venous flow [2].

High-dose iv antibiotics for 2 weeks to 6 weeks form the mainstay of treatment. *F. necrophorum* is normally sensitive to Benzylpenicillin which is commonly used in conjunction with other anti-anaerobic antibiotics, such as Metronidazole, Clindamycin, and Chloramphenicol [11]. It is advisable that any metastatic purulent collections associated with *F. necrophorum* septicemia, such as pulmonary, hepatic, splenic, septic arthritis and deep neck collections, are drained in our case a drain was re-sited until all the pus was evacuated [12]. There are no randomized controlled trials that examine the benefits of anticoagulation following IJV thrombosis [13]. Anticoagulation can be initiated when septic emboli persist despite antibiotic therapy or, when there is evidence of retrograde thrombosis propagating to the cavernous sinus [12,14]. However, due consideration should be given when initiating therapy as Lemierre's syndrome itself may have induced thrombocytopenia [13]. Surgical ligation of the IJV is rarely performed nowadays, being reserved for patients with uncontrolled sepsis and repeated septic emboli despite adequate medical therapy- in our case the internal jugular vein thrombosis extended into the thoracic inlet and was therefore too caudal to be tied off [12,14].

The case presented clearly illustrates the rapid progression of this very severe infective process and promotes the profile of this rare, but life-threatening condition within our specialist community. It is essential that these cases are managed by a multidisciplinary team that includes the otolaryngologist, microbiologist, hematologist, respiratory physician, and other surgical specialties.

Acknowledgement

We would like to thank Mr. Milton Pena, Consultant Orthopedic Surgeon and Dr. Howard Sacho, Consultant Microbiologist for their expertise in the management of this case.

References

1. Lemierre A. On certain septicaemias due to anaerobic organisms. *Lancet*. 1936;227(5874):701-3.
2. Riordan T. Human Infection with *Fusobacterium necrophorum* (Necrobacillosis), with a Focus on Lemierre's Syndrome. *Clin Microbiol Rev*. 2007;20(4):622-59.
3. Karkos PD, Asrani S, Karkos CD, Leong SC, Theochari EG, Alexopoulou TD, et al. Lemierre's syndrome: A systematic review. *Laryngoscope*. 2009;119(8):1552-9.
4. Chirinos JA, Lichtstein, DM, Garcia J, Tamariz LJ. The evolution of lemierre syndrome: Report of 2 cases and review of the literature. *Medicine (Baltimore)*. 2002;81(6):458-65.
5. Jankowich M, El-Sameed YA, Abu-Hijleh M. A 21-year-old man with fever and sore throat rapidly progressive to hemoptysis and respiratory failure. Diagnosis: Lemierre syndrome with *Fusobacterium necrophorum* sepsis. *Chest*. 2007;132(5):1706-9.
6. Screaton NJ, Ravenel JG, Lehner PJ, Heitzman ER, Flower CD. Lemierre syndrome: Forgotten but not extinct--report of four cases. *Radiology*. 1999;213(2):369-74.
7. Lu MD, Vasavada Z, Tanner C. Lemierre syndrome following Oropharyngeal infection: A case series. *J Am Board Fam Med*. 2009;22(1):79-83.
8. Ajulo P, Qayyum A, Brewis C, Innes A. Lemierre's syndrome: The link between a simple sore throat, sore neck and pleuritic chest pain. *Ann R Coll Surg Engl*. 2005;87(4):303-5.
9. Kuhlman JE, Fishman EK, Teigen C. Pulmonary septic emboli: Diagnosis with CT. *Radiology*. 1990;174(1):211-3.
10. Hong P, MacCormick J, Lamothe A, Corsten M. Lemierre syndrome: Presentation of three cases. *J Otolaryngol*. 2005;34(5):352-8.
11. Clarke MG, Kennedy NJ, Kennedy K. Serious consequences of a sore throat. *Ann R Coll Surg Engl*. 2003;85(4):242-4.
12. Lustig LR, Cusick BC, Cheung SW, Lee KC. Lemierre's syndrome: Two cases of postanginal sepsis. *Otolaryngol Head Neck Surg*. 1995;112(6):762-72.
13. Brown LM, Wallwork B. Lemierre's- the sinister sore throat. *J Laryngol Otol*. 2007;121(7):692-4.
14. Hope A, Bleach N, Ghiacy S. Lemierre's syndrome as a consequence of acute supraglottitis. *J Laryngol Otol*. 2002;116(3):216-8.