American Journal of Otolaryngology and Head and Neck Surgery

Research Article
Published: 29 Jul, 2021

An Algorithm for Facial Asymmetry Correction in Adult TMJ Ankylosis Patients - A Clinical Study

Abhay Datarkar, Subodh Purohit, Amit Bhawalkar, Surendra Dawre and Arwa Pardiwala*

Department of Oral and Maxillofacial Surgery, Government Dental College & Hospital, Government Medical College Campus, India

Abstract

Purpose: To evaluate the sequential treatment of patients with temporomandibular joint ankylosis and secondary deformities by distraction osteogenesis and subsequent arthroplasty or orthognathic surgery.

Method: This is a Prospective Institutional based clinical study in which 15 patients with age ranging from 18 to 28 years (mean = 22.1 years) diagnosed with unilateral temporomandibular joint ankylosis were included. All the 15 patients were first treated with distraction osteogenesis followed by interpositional arthroplasty of TMJ. Out of these 15 patients, 11 underwent facial correction Orthognathic surgery. Patients were evaluated for difference in airway after completion of treatment using-cephalometric analysis, Increase in maximum interincisal opening, Difference in weight of patient and a questioner based subjective evaluation of improvement in facial esthetics, symptoms of sleep apnea and betterment in quality of life of patient.

Results: Sequence of early Distraction osteogenesis, followed by Interpositional Arthroplasty and final facial correction using corrective facial surgery is useful in treatment of adult temporomandibular joint ankyloses. Improvement was seen in maximum interincisal opening, stable occlusion and reduction in sleep apnea as well as increase in upper airway space was noticed. Patients were kept under a long follow-up, ranging from 6 to 50 months with an average of 24.3 months. Relapse was noticed in 1 patient.

Conclusion: This study reveals that distraction osteogenesis followed by arthroplasty and corrective orthognathic surgery when required can provide good results in temporomandibular joint ankylosis patients with good facial features, stable occlusion, adequate mouth opening and reduction in obstructive sleep apnea syndrome.

Keywords: Distraction; TMJ ankylosis; Sleep apnea; Orthognathic Surgery

OPEN ACCESS

****Correspondence:***
Subodh Purohit, Department of Oral and Maxillofacial Surgery, Government Dental College & Hospital, Government Medical College Campus, Medical Square, Nagpur, Maharashtra, India, Tel: 7798843544;
E-mail: afmcgmc@gmail.com

Received Date: *13 Jul 2021*
Accepted Date*: 26 Jul 2021*
Published Date*: 29 Jul 2021*

Citation:
Datarkar A, Purohit S, Bhawalkar A, Dawre S, Pardiwala A. An Algorithm for Facial Asymmetry Correction in Adult TMJ Ankylosis Patients - A Clinical Study. Am J Otolaryngol Head Neck Surg. 2021; 4(7): 1147.

Introduction

Temporomandibular Joint (TMJ) ankylosis is basically the fusion of the mandibular condyle to the glenoid fossa and surrounding structures, ultimately leading to hypomobility and failure to function of temporomandibular joint, creating a very distressing condition for victim and depriving the subject from basic masticatory and speech abilities [1]. This adhesion may be due to presence of hard or soft tissue and can be further classified as complete or incomplete and anatomically as intracapsular or extracapsular. Bony ankylosis is usually confined to the intracapsular condyle, glenoid fossa and articular eminence area. However, extracapsular bone formation may be severely extensive spreading beyond the capsule to include the coronoid process, the zygomatic arch, the lateral pterygoid plate, the external auditory canal and the skull base.

Ankylosis may manifest congenitally, in young children or adolescents. Temporomandibular joint ankylosis presenting in growth phase may lead to various deformities in the patient's jaw like asymmetric growth of mandible, small sized mandible and posterior positioning of mandible that may reduce pharyngeal airway space causing obstructive sleep apnea syndrome.

Trauma, local or systemic infection, iatrogenic factors including previous temporomandibular joint surgery and irradiation, burns, and genetic factors may all contribute to this disease [2].

Aim of management of Temporomandibular joint ankylosis is focused on releasing the ankylotic mass and achieving adequate mouth opening, correction of facial asymmetry and aesthetics, securing a stable occlusion and a patent posterior airway. Most treatment protocols

are designed mainly to treat the ankylosis, and the management of obstructive sleep apnea syndrome is often secondary. The surgical procedures undertaken to treat temporomandibular joint ankylosis includes TMJ arthroplasty, joint reconstruction, and orthognathic surgery. Recently distraction osteogenesis is being brought into use for the treatment of TMJ ankylosis [3]. Distraction osteogenesis was first given by Gavril Ilizarov in 1950s for limb lengthening. This allows lengthening of the bone and surrounding soft tissues based on controlled fracture and tractional force applied by the distractor. The standard bone grafts are unpredictable and unsatisfactory results such as reankylosis, growth disturbance, facial asymmetry and donor site morbidity are also common. Mandibular advancement greater than 7 mm becomes more unstable with traditional osteotomies [4]. Hence, Distraction osteogenesis of the small mandible can replace traditional techniques like allografts and autografts. Major question in this field is about the sequencing of these techniques in the treatment of Temporomandibular Joint ankylosis.

Hence, the aim of this study is to evaluate sequencing of distraction osteogenesis and gap arthroplasty in treatment of Temporomandibular Joint ankylosis and to find out need of corrective orthognathic surgery in such triad patients.

Materials and Methods

Study population

Fifteen patients (9 male and 6 females) with range of age starting from 18 to 28 years with a mean age of 22.12 years were enrolled in the study. Among these patients, 10 patients had left TMJ ankylosis and 5 patients had right TMJ ankylosis.

Etiology of these 15 patients included ENT Infection for 37.5% (n=5), Trauma for 50% (n=7) and Congenital for 12.5% (n=3).

Patients' medical history along with physical examination and required radiographic investigations were done including CT scan, OPG and lateral cephalogram to confirm the final diagnosis and to determine the extent and severity of the disease.

Written Informed Consent was obtained from all the patients.

Surgical method

Placement of distractor: Vector for the distraction was calculated and distractor was pre-adapted onto stereolithographic model. Surgical approach used for distractor placement was submandibular approach with an aim to preserve the marginal mandibular nerve and to reduce post-operative aesthetic complications. After exposure of mandibular site, distractor was placed, checked for adaptation and makings were done. Osteotomy cuts were given using round bur and straight fissure bur followed by separation of osteotomy site using Smith's Spreader. Distractor was fixed using 4 monocortical screws with an oblique position with respect to the inferior border of mandible and activated before closure to check any bony resistance. Exit port of the device was kept extra-orally (Figure 1). After a latency period of 7 days, distractor was activated with rate of 1 mm/day divided in two intervals of two 180° turns daily. As the desired results were obtained, a period of 3 to 6 months was kept as a consolidation period.

Release of ankylotic mass-after 6 months of distractor placement: A modified Al-Kayat-Bramley approach was taken, the temporomandibular Joint was exposed and the sub-ankylotic release of mass was done. Ipsilateral coronoidectomy followed by contralateral coronoidectomy if maximum interincisal opening was less than 30 mm was done. Interpositioning was done using temporal is muscle-fascia flap or abdominal fat pad along with distractor removal.

Facial correction surgery for secondary defects-after 1 year follow-up of arthroplasty: To achieve the primary aim of stable occlusion and better facial profile, few patients required corrective facial surgery which included orthomorphic and orthognathic surgery.

Evaluation of outcome

Treatment outcome was evaluated using three criteria

I. Maximum Inter-incisal Opening-assessed by measuring the distance between the incisal edges of the upper and lower central incisor. The distance was measured in millimeters during pre-op, intra-op and on follow up mouth opening. Less than 25 mm of maximum inter-incisal Opening on recall was considered as relapse.

II. Facial Appearance and improvement in social life of patient was evaluated based on a questioner for patient and their relative.

III. Respiratory function was evaluated

A. Objectively-preoperative and postoperative comparative cephalometric analysis which consisted Mcnamara analysis [5].

B. Subjectively-post operative questioner based evaluation of patient and patient relative.

Questioner

Each option was given a score from 1 being minimal and 4 being maximum and total score from each patient was calculated and graded using following scale.

Grading System (Total Score-20)

1. Unsatisfied- 5
2. Moderately satisfied- 6-10
3. Very Satisfied- 11-15
4. Extremely Satisfied- 16-20

Question for Patient

How will you grade change in your facial appearance after completion of treatment?

1. Poor-{1}
2. Average-{2}
3. Good-{3}
4. Very Good-{4}

Do you feel any change in your social life after the treatment?

1. No change at all-{1}
2. Increase in confidence-{2}
3. Increased social contacts and visits to social gatherings-{3}
4. Option 2 and 3 both-{4}

Do you still have episodes of apnea while sleeping and feel drowse during day time?

1. Episodes of apnea daily and day time drowsiness-{1}
2. Occasional episodes of apnea and day time drowsiness-{2}
3. Day time drowsiness-{3}
4. No sleep apnea or Day time Drowsiness at all-{4}

Question for Patient's relative

How is the change in facial appearance and quality of life of your patient after completion of treatment?

1. Poor-{1}
2. Average-{2}
3. Good-{3}
4. Very Good-{4}

How is the frequency of episodes of sleep apnea and snoring after treatment?

1. Multiple episodes of sleep apnea daily with snoring-{1}
2. Single episode of sleep apnea daily with Snoring-{2}
3. No episode of sleep apnea but Snoring is present-{3}
4. No episode of Sleep apnea and No Snoring-{4}

Statistical analysis

Data was analyzed for statistical significance using Epiinfo Software with resultant P value of 0.01 ($P<0.05$ is considered to be significant).

Results

All patients underwent distraction osteogenesis first followed by release of ankylotic mass. Eleven patients required third stage orthognathic surgery to improve facial features and occlusal stability among which one underwent sub-ramal osteotomy, 1 underwent unilateral sagittal split osteotomy and 9 underwent genioplasty.

Average preoperative mouth opening was 4.13 mm (Ranged from 0 mm to 14 mm) that improved significantly in all patients after arthroplasty. Average intraoperative Maximum Mouth Opening was 43.67 mm (ranging from 40 to 50 mm) and Maximum Mouth Opening during three-year follow up was 36 mm (ranging from 28 mm to 42 mm). Thus, the interincisal distance increased significantly after arthroplasty and remained stable when measured at 3 years follow up visit.

Ten patients had Obstructive sleep apnea. For patients with complaints of sleep apnea, there was significant relief in symptoms of snoring and obstructive sleep apnea episodes plus there was an appreciable increase in airway on lateral cephalogram (Figure 2). With average preoperative upper airway space was 5.4 mm and lower airway space was 5.5 mm which increased to 10.4 mm and 10.27 mm respectively after completion of third stage surgery.

Figure 1: Position of distractor (Surgical site).

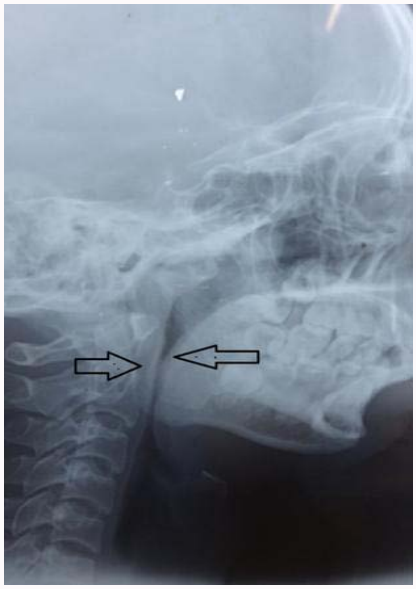

Figure 2: Cephalogram showing decreased airway space before treatment.

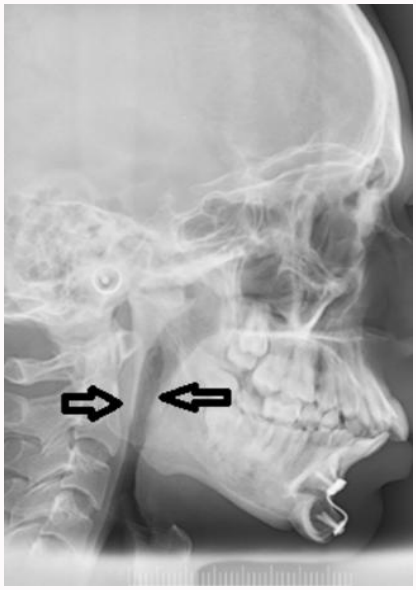

Figure 3: Cephalogram of same patient showing an increase in airway space after completion of third stage surgery.

On subjective evaluation of patients based on the questioner mentioned previously in the methodology 10 patients were very satisfied and 5 patients were extremely satisfied.

Discussion

TMJ having a complex anatomy with vital structure at medial side acts as a mystery box on table to the surgeon. The mean distance from the outer aspect of the zygomatic arch to the middle meningeal

Table 1: Characteristics of study patients.

Case	Age (years)/Gender	Affected Side	Etiology	Preop MIO (mm)	Intraop MIO (mm)	3 year Follow Up MIO (mm)	Preop Upper Airway Space Analysis (mm)	Preop Lower Airway Space Analysis (mm)	Postop Upper Airway Space Analysis (mm)	Postop Lower Airway Space Analysis (mm)
1	19/F	Right	Trauma	4	50	42	5	6	9	10
2	25/M	Left	Trauma	3	40	32	6	5	11	9
3	22/M	Left	Congenital	13	45	40	4	7	8	11
4	22F	Right	Infection	3	45	36	5	4	9	8
5	21/F	Left	Trauma	5	40	32	7	5	12	9
6	22/M	Left	Trauma	14	45	38	5	5	10	10
7	18/M	Left	Infection	0	45	40	4	5	9	12
8	28/F	Left	Infection	0	50	28	5	4	13	9
9	17/F	Right	Trauma	2	42	30	5	6	9	13
10	25/M	Right	Trauma	0	48	26	8	7	14	12
11	26/M	Right	Trauma	0	50	28	4	4	9	10
12	28/M	Left	Infection	0	44	31	5	5	10	10
13	22/F	Left	Congenital	0	47	34	5	6	11	12
14	16/M	Left	Congenital	0	42	40	6	7	11	9
15	18/M	Left	Infection	0	41	42	7	6	12	10

M: Male; F: Female; MIO: Maximum Interincisal Opening; mm: Millimeter

Table 2: Statistical analysis of changes in maximum inter-incisal opening and airway analysis.

	Maximum Inter-Incisal Opening			Airway analysis			
	Pre-operative	Intra-operative	Follow-up	Preop Upper Airway Space Analysis	Preop Lower Airway Space Analysis	Postop Upper Airway Space Analysis	Postop Lower Airway Space Analysis
Mean	2.9 mm	44.9 mm	34.6 mm	5.4 mm	5.5 mm	10.4 mm	10.27 mm
Standard Deviation	4.7 mm	3.51 mm	5.5 mm	1.14 mm	1.02 mm	1.67 mm	1.39 mm
Minimum	0 mm	50 mm	42 mm	4 mm	4 mm	8 mm	8 mm
Maximum	14 mm	40 mm	26 mm	8 mm	7 mm	14 mm	13 mm

artery is 31 mm (SD ± 4.9 mm; range, 21 mm to 43 mm). The antero-posterior distance from the artery to the height of glenoid fossa was 2.4 mm (SD ± 2.9 mm; range, - 2 mm to 8 mm) [6]. Proximity of these structures makes any intervention in temporomandibular area critical.

In recent years, neocondyle distraction has added a new dimension to the management of TMJ ankylosis [7]. Total joint replacement using temporomandibular joint prosthesis along with dermal fat pad covering is an upcoming option in treatment of temporomandibular joint disorders [8]. Although there are various treatment modalities available, sequence of treatment procedures still remains a dilemma.

One of the protocols is distraction osteogenesis can be done simultaneously with gap arthroplasty in patients with temporomandibular ankylosis, for the correction of the mandible deformity [9]. This is being suggested by some surgeons with a point of view of reducing number of surgeries, financial load and better mental status of patient. But obvious disadvantage of 1-stage surgery is that it reduces control over correction of occlusion and makes the orthodontic treatment more difficult. In addition, unlike the case in young children, it is difficult to use maxillary and mandibular growth potential [10]. Plus another surgery may be required to remove distractors.

Protocol that has been followed commonly in past and has been proven effective with some due risk is initial arthroplasty followed by distraction that is release then distract method. This technique makes intraoral distractor placement easier due to increased mouth opening and improves nutrition as a result of better masticatory efficiency of patient hence uplifting the standard of health of patient for further procedures. But risk of postoperative edema, reduced airway space and requirement of emergency tracheostomy may occur with this protocol [11].

Another school of thought suggested by various surgical centers as well as supported by our very own surgical team is distraction osteogenesis first followed by arthroplasty with a point of view of restoring length and location of mandible and then use of arthroplasty to increase mouth opening [12].

Advantages of this protocol are prior increase in airway space thus making further procedures safer, preventing postoperative apnea and drop in blood saturation levels. But this protocol may increase the risk of postoperative anterior open bite. Development of anterior open bite can be prevented by a through surgical planning at the time of distractor placement where decrease in length of ramus at the time of arthroplasty should be prejudged and ramal height should be increased accordingly using distraction during first stage of treatment

Mandible has a very complex 3 dimensional form and to create a controlled neoformed bone with favourable morphologic features

preoperative planning, geometric analysis and anticipation of long term results is of utmost importance. Vertical vector placement led to a posterior open bite and vector horizontal to lower border of mandible lead to obliteration of gonial angle and loss of overjet. In this study we support oblique vector in which new bone formed due to distraction maintained original form and there was preservation of gonial angle [12]. We calculate Vector to highest precision using following formula.

In this study, various particular measures were undertaken to gain satisfactory results in treatment of facial asymmetry due to TMJ ankylosis that included.

Patient underwent distraction osteogenesis with an oblique vector hence increasing the posterior airway along with controlled expansion of mandible preserving the gonial angle.

1. Patient underwent aggressive resection of ankylotic mass and unilateral or bilateral coronoidectomy (Kaban's Protocol) to achieve significant intra-op mouth-opening [13].

2. Interpositioning of temporalis muscle flap or abdominal fat pad to prevent re-ankylosis [14,15].

3. Patients were trained to undergo aggressive postoperative physiotherapy from 3 days after TMJ arthroplasty which included active as well as functional exercises.

4. Patients with unstable occlusion or with unsatisfactory facial features underwent third stage orthognathic surgery to improve the above mentioned features.

Conclusion

We can conclude from this study that facial asymmetry secondary to TMJ ankyloses is a challenging disease to treat and hence formulation of evidence based protocol is need of the hour. Distraction done prior to arthroplasty improves functional outcome and reduces post-operative complications of arthroplasty. Orthognathic surgery can be a useful aid in correcting post-operative asymmetry and achieving a more stable occlusion.

References

1. Su-Gwan K. Treatment of temporomandibular joint ankylosis with temporalis muscle and fascia flap. Int J Oral Maxillofac Surg. 2001;30(3):189-93.
2. Zhang W, Yang X, Zhang Y, Zhao T, Jia J, Chang S, et al. The sequential treatment of temporomandibular joint ankylosis with secondary deformities by distraction osteogenesis and arthroplasty or TMJ reconstruction. Int J Oral Maxillofac Surg. 2018;47(8):1052-9.
3. Katsnelson A, Markiewicz MR, Keith DA, Dodson TB. Operative management of temporomandibular joint ankylosis: A systematic review and meta-analysis. J Oral Maxillofac Surg. 2012;70(3):531-6.
4. Gupta GM, Gupta P, Sharma A, Patel N, Singh A. Evaluation of functional and esthetic outcome after correction of mandibular hypoplasia secondary to temporomandibular ankylosis treated by distraction osteogenesis. J Maxillofac Oral Surg. 2014;13(2):152-8.
5. Mcnamara JA. A method of cephalomettic evaluation. Am J Orthod. 1984;86(6):449-69.
6. Talebzadeh N, Rosenstein TP, Pogrel MA. Anatomy of the structures medial to the temporomandibular joint-Oral Surgery, Oral Medicine, Oral Pathology and Oral Radiology. 1999.
7. Sharma R, Manikandhan R, Sneha P, Parameswaran A, Kumar JN, Sailer HF. Neocondyle distraction osteogenesis in the management of temporomandibular joint ankylosis: Report of five cases with review of literature. Indian J Dent Res. 2017; 28(3):269-74.
8. Wolford LM, Morales-Ryan CA, Morales PG, Cassano DS. Autologous fat grafts placed around temporomandibular joint total joint prostheses to prevent heterotopic bone formation. Proc Bayl Univ Med Cent. 2008;21(3):248-54.
9. Rao K, Kumar S, Kumar V, Singh AK, Bhatnagar SK. The role of simultaneous gap arthroplasty and distraction osteogenesis in the management of temporomandibular joint ankylosis with mandibular deformity in children. J Craniomaxillofac Surg. 2004;32(1):38-42.
10. Zhu S, Li J, Luo E, Feng G, Ma Y, Hu J. Two-Stage treatment protocol for management of temporomandibular joint ankylosis with secondary deformities in adults: our institution's experience. J Oral Maxillofac Surg. 2011;69(12):e565-72.
11. Li J, Zhu S, Wang T, Luo E, Xiao L, Hu J. Staged treatment of temporomandibular joint ankylosis with micrognathia using mandibular osteodistraction and advancement genioplasty. J Oral Maxillofac Surg. 2012;70(12):2884-92.
12. Grayson B, McCormick S, Santiago PE, McCarthy J. Vector of device placement and trajectory of mandibular distraction. J Craniofac Surg. 1997;8(6):473-80.
13. Kaban LB, Bouchard C, Troulis MJ. A protocol for management of temporomandibular joint ankylosis in children. J Oral Maxillofac Surg. 2009;67(9):1966-78.
14. Pogrel MA, Kaban LB. The role of a temporalis fascia and muscle flap in temporomandibular joint surgery. J Oral Maxillofac Surg. 1990;48(1):14-9.
15. Dimitroulis G. The interpositional dermis-fat graft in the management of temporomandibular joint ankylosis. Int J Oral Maxillofac Surg. 2004;33(8):755-60.