



# Accelerated Acute Antibody–Mediated Kidney Rejection by Anti-HLA-DP Antibody Detected in Biopsy Eluate: A Case Report

Marilena Gregorini<sup>1</sup>, Massimo Cardillo<sup>2</sup>, Eleonora Francesca Pattonieri<sup>1</sup>, Angela Nocco<sup>3</sup>, Annalisa Innocente<sup>3</sup>, Carmelo Libetta<sup>1</sup>, Vincenzo Sepe<sup>1</sup>, Anna Lia Asti<sup>1\*</sup>, Maria Antonietta Grignano<sup>1</sup> and Teresa Rampino<sup>1</sup>

<sup>1</sup>Department of Internal Medicine and Therapeutics and Unit of Nephrology, Dialysis and Transplantation, Fondazione IRCCS Policlinico San Matteo, University of Pavia, Italy

<sup>2</sup>Italian National Transplantation Center, Italian National Institute of Health, Italy

<sup>3</sup>Transplant Immunology Laboratory, UOC Coordinamento Trapianti IRCCS Ospedale Maggiore Policlinico, Italy

## Abstract

We report a case of accelerated humoral rejection in a woman who received a second renal transplant after desensitization. Pre-transplant T-lymphocyte complement -dependent-cytotoxicity cross-match was negative. A primary graft non-function occurred. The graft biopsy showed humoral rejection. Luminex test performed on kidney biopsy eluate, showed donor specific anti HLA-DP antibodies without other humoral activity. HLA-DP antibody typing is often not hindering for organ allocation, because it is believed that donor HLA-DP sensitization does not preclude the transplantation. This report demonstrates that anti-DP DSA can be associated with graft failure, their absence in serum recipient at the time of acute kidney injury must not induce in mistake. Donor HLA-DP typing in sensitized patients should always be considered with attention before allocation organs. Luminex test applied to eluate of graft biopsy can be considered a new method to identify the antibodies responsible of a rejection.

## OPEN ACCESS

### \*Correspondence:

Anna Lia Asti, Department of Internal Medicine and Therapeutics and Unit of Nephrology, Dialysis and Transplantation, Fondazione IRCCS Policlinico San Matteo, viale Golgi 19, 27100 Pavia, University of Pavia, Italy,  
Tel: 3333962590;  
E-mail: annalia.asti@unipv.it

Received Date: 01 Feb 2022

Accepted Date: 03 Mar 2022

Published Date: 24 Mar 2022

### Citation:

Gregorini M, Cardillo M, Pattonieri EF, Nocco A, Innocente A, Libetta C, et al. Accelerated Acute Antibody–Mediated Kidney Rejection by Anti-HLA-DP Antibody Detected in Biopsy Eluate: A Case Report. *Ann Transplant Res.* 2022; 3(1): 1016.

**Copyright** © 2022 Anna Lia Asti. This is an open access article distributed under the Creative Commons Attribution License, which permits unrestricted use, distribution, and reproduction in any medium, provided the original work is properly cited.

## Background

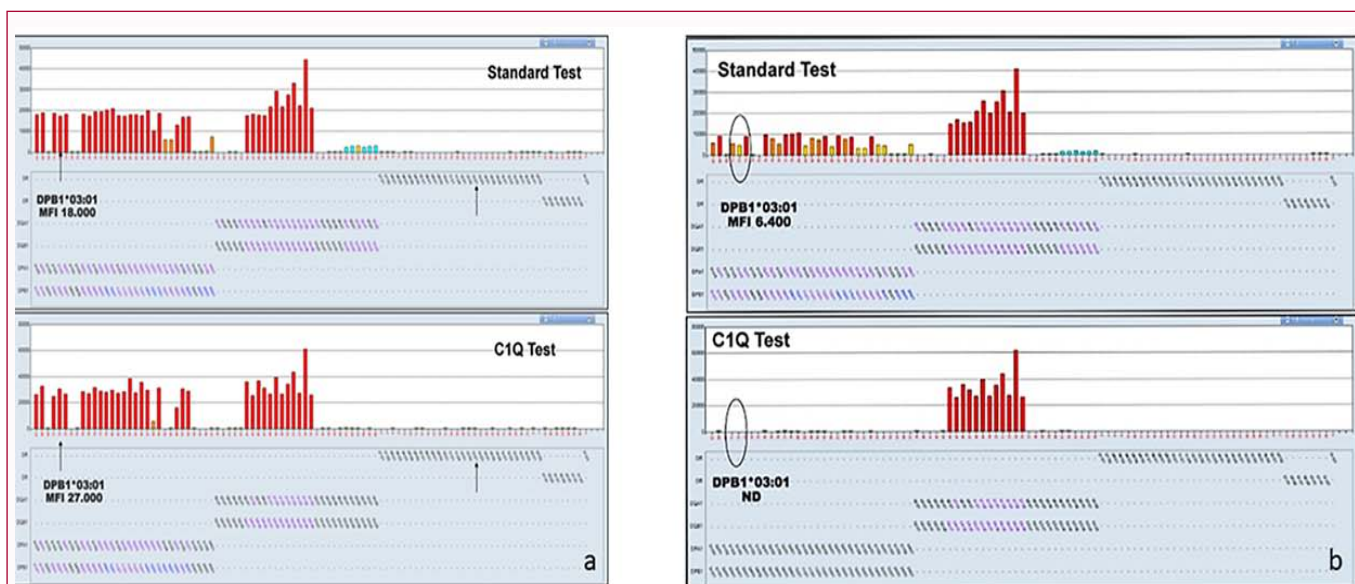
Pre-formed Donor-Specific Anti-HLA antibodies (DSAs) play a major role in renal transplants as they are associated with humoral rejection and graft failure [1]. HLA-DP antigen is minimally expressed on renal endothelium and its immunogenicity seems to be of limited relevance [2-4].

This is perhaps the reason why the presence of HLA-DP is not considered to be relevant in the matching algorithms of many kidney allocation systems [5-7]. Nevertheless, some authors underscored the negative impact of pre-formed and de novo anti-DP antibodies in the outcome of a transplant [8].

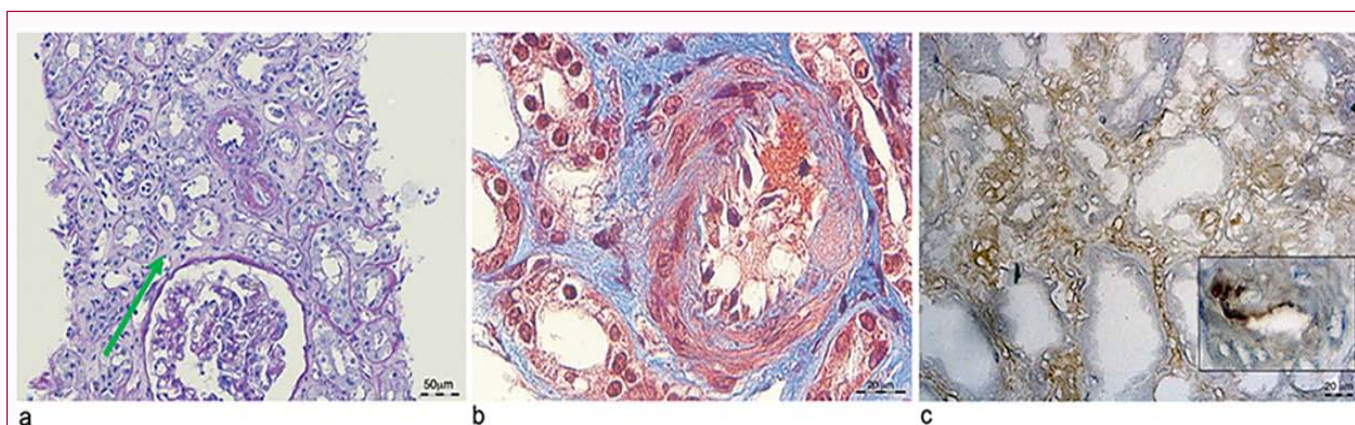
We report a case of Primary Non-Function (PNF) due to a humoral acute rejection caused by anti-HLA-DP antibodies in a kidney re-transplanted patient. This evidence is given by the anti HLA–DP identification on the graft biopsy eluate and strengthens the case in favor of the careful consideration of HLA-DP match in kidney allocation algorithm.

## Case Presentation

A 45 year-old Caucasian woman with end-stage renal disease due to unknown cause started regular dialysis treatment in 2002. In 2004 she received a kidney from a deceased donor, and in 2007 she spontaneously interrupted the immunosuppressive therapy to facilitate recovery from a severe viral infection. It was followed graft failure due to acute rejection. She was underwent regular dialysis. In 2008 she was included into the waiting list for re-transplant. Her blood group was A Rh pos, and HLA typing was A\*24, \*30; B\*18, \*38; DR\*07, \*11. Preformed antibodies were screened every 3 months with the Luminex and the Complement-Dependent-Cytotoxicity (CDC) techniques. In October 2015 she was given high priority on the waiting list because of lack of vascular access. At that time she had a high cPRA (70%) and she underwent a desensitization treatment with Rituximab (375 mg/mq), 12 plasmapheresis sessions and low-dose Ig Immunoglobulins (IV Ig) (400 mg/Kg) for five days. One month after the desensitization she received a graft with three mismatches: A32, B41, and DR13. Pre-transplant CDC cross-match against donor T-lymphocyte was negative, and



**Figure 1:** Panel a: Retrospective screening of donor-specific Anti-Human Leukocyte Antigen (HLA) antibodies (DSAs) performed on recipient serum before kidney transplantation. Standard and C1Q Luminex test showed anti HLA DP1\*03:01 DSAs (MFI 18000) in the serum collected preoperatively. Panel b: Change in anti HLA-DP DSAs levels after transplantation at the time of graft biopsy. Standard and C1Q Luminex test showed anti HLA DP1\*03:01 DSAs were absent in the recipient's serum.



**Figure 2:** Representative renal sections of graft biopsy show tubular necrosis, endotheliitis with intramural fibrinoid necrosis (arrow). Panel a: Periodic Acid Schiff (PAS) staining. Panel b: Masson Trichrome staining Panel C: C4d staining.

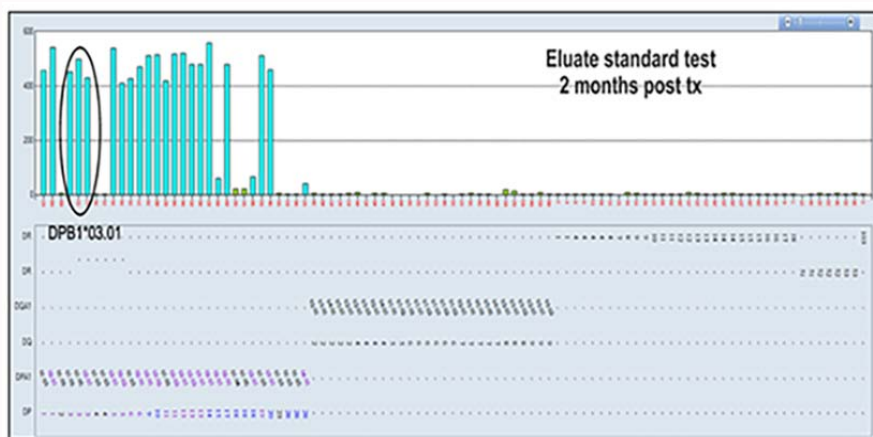
the one against B-lymphocyte was not performed because of the false positivity known to be associated with the Rituximab treatment. The induction immunosuppressive therapy with Thymoglobuline, (ATG 3.5 mg/Kg), was followed by Tacrolimus, Mofetil Mycophenolate and steroid regimen. PNF occurred, but graft biopsy was performed only 12 days after transplantation because of prolonged bleeding-time. It showed a C4d-positive acute active Antibody-Mediated Rejection (AMR) according to 2013 Banff classification. The patient was treated with plasmapheresis (6 sessions), followed by 3 pulses of methylprednisolone (total-dose 3 g), IVIG 400 mg/Kg for five days and finally 8 photo apheresis sessions as a rescue treatment. Post-transplant antibody surveillance, performed with standard and C1Q Luminex test resulted always negative for anti-DSAs, included anti-DP antibodies detection. A retrospective analysis of antibody screening on recipient serum collected soon after the desensitization showed anti HLA-DP \*03:01 DSA (MFI=18.187, standard test) (MFI=27.398, C1Q test) (Figure 1). Previous antibody screening performed in June 2010 did not detect anti DSA anti DP, but only anti HLA B32 (MFI 5000) and anti HLA B41 (MFI 8800) DSAs that

were not detected further.

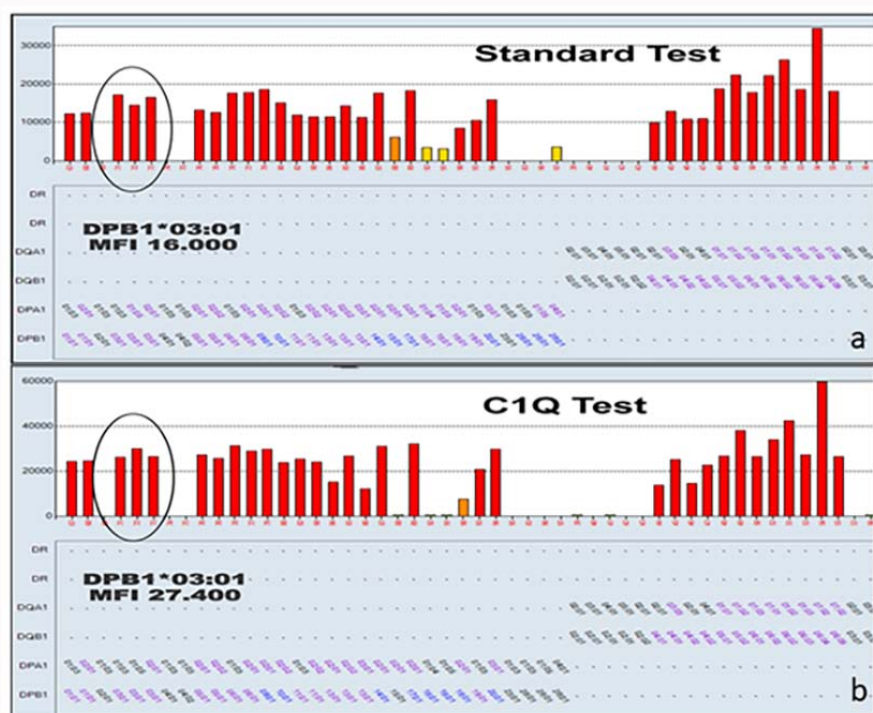
Since anti-rejection treatment failed, 2 months after transplantation a new renal biopsy was performed to evaluate whether humoral rejection was due to anti HLA-DP antibodies. Kidney biopsy showed glomerular and peritubular capillary thrombosis resulting in severe tubular necrosis and endotheliitis with intramural fibrinoid necrosis (Figure 2). CD20 and plasma cells were absent in peripheral blood and renal biopsy. The eluate of renal section was processed for standard and C1Q Luminex test. The standard Luminex assay showed the presence of anti-DP\*03:01 antibodies (Figure 3).

To avoid excessive risk in patient with many antibiotic allergies and not vaccinated for capsulated bacteria, and considered the severity of graft damage, likely irreversible, Bortezomib and Eculizumab weren't administered.

Since PNF persisted the graft was removed 8 months after the transplant, and interestingly that serum anti-HLA-DP antibody levels were again detectable (Figure 4).



**Figure 3:** Anti HLA-DP DSAs levels detected by standard Luminex test on eluate of renal section. Anti HLA DP1\*03:018 DSAs were present on graft two months after transplantation.



**Figure 4:** Anti HLA-DP DSAs serum levels after graft removal. Standard (panel a) and C1Q (panel b) Luminex test showed the anti HLA DP1\*03:01 DSAs re-appearance in the patient serum.

### Discussion

Several factors, both immunological and non-immunological, are known to influence graft outcome, but although new therapies as well as the advancements in mesenchymal stem cell, growth factor therapies and drug monitoring have improved it [9-13], a correct and careful organ allocation remains the most important step to prevent graft failure.

The studies of HLA antibodies in organ transplant have mainly focused on alloantibodies directed against HLA -A, -B, -DR, and DQ molecules, less on HLA-DP as it has been considered to be less immunogenic than other HLA molecules. Therefore the role of donor specific HLA-DP antibodies in solid organ has remained unclear. The prevalence of anti HLA-DP antibodies detected after kidney

transplantation varies from 9.5% to 77% [14-16]. Most of anti DP antibodies are detected with other anti HLA class II DR and or DQ specificities and the presence of isolated anti HLA-DP antibodies is a rare event [3]. It has been reported that HLA-DP mismatch does not affect the outcome of the first kidney transplant while it seems to have a negative impact on re-transplant's outcomes [8]. However the presence of HLA-DP antibodies is not considered to be a high risk factor for early AMR. Indeed (i) the low expression of HLA-DP antigens in endothelium, (ii) the low HLA-DP antigens immunogenicity, (iii) the good graft outcome reported in patients with anti HLA-DP antibodies, (iv) the lack of cytotoxicity of many HLA-DP antibodies detectable by the antigen-binding test seem to support this consideration [2,17].

We reported a case of accelerated AMR due to pre-formed C1q

fixing anti HLA-DP DSAs despite of a negative cross match and in order to identify DSAs responsible of the rejection we performed Luminex test on eluate of a renal section. To the best of our knowledge this is the first report that shows the usefulness of Luminex test performed on graft biopsy eluate to identify the antibodies causing humoral rejection. Our findings are consistent with the cytotoxic activity of anti-DP antibodies and the decrease of anti HLA DP DSAs serum levels after transplantation is explained by their absorption to the renal tissue, in fact their serum title increased after the graft removal.

In conclusion this report shows that HLA-DP DSAs constitute a significant risk for antibody mediated rejection, therefore we recommend HLA DP typing before transplantation, mainly in candidates for the second transplantation. The presence of HLA-DP DSAs with high MFI is not always correlated with positive cross match result. Further studies are warranted to characterize the clinical significance of negative cross match with high MFI HLA-DP DSAs.

In addition our experience indicates a new and easy use of Luminex test to identify the antibodies responsible of rejection.

## References

- Süsal C, Opelz G. Kidney graft failure and presensitization against HLA class I and class II antigens. *Transplantation*. 2002;73(8):1269-73.
- Pfeiffer K, Vögeler U, Albrecht KH, Eigler FW, Buchholz B, Grosse-Wilde H. HLA-DP antibodies in patients awaiting renal transplantation. *Transpl Int*. 1995;8(3):180-4.
- Simmons DP, Kafetzis ML, Wood I, Macaskill PC, Milford EL, Guleria I. Antibodies against HLA-DP recognize broadly expressed epitopes. *Hum Immunol*. 2016;77(12):1128-39.
- Duquesnoy RJ, Awadalla Y, Lomago J, Jelinek L, Howe J, Zern D, et al. Retransplant candidates have donor-specific antibodies that react with structurally defined HLA-DR,DQ,DP epitopes. *Transpl Immunol*. 2008;18(4):352-60.
- Middleton D, Mytilineos D, Savage D, Ferrara GB, Angelini G, Ameroso A, et al. Matching for HLA-DPB1 alleles in zero mismatched HLA-A, -B and -DR renal transplants. *Transpl Proc*. 1992;24:2439-40.
- Mytilineos J, Deufel A, Opelz G. Clinical relevance of HLA-DPB locus matching for cadaver kidney retransplants: A report of the collaborative transplant study. *Transplantation*. 1997;63(9):1351-4.
- Tinckam KJ, Liwski R, Pochinco D, Mousseau M, Grattan A, Nickerson P, et al. cPRA increases with DQA, DPA, and DPB unacceptable antigens in the Canadian cPRA calculator. *Am J Transplant*. 2015;15(12):3194-201.
- Mierzejewska B, Schroder PM, Baum CE, Blair A, Smith C, Duquesnoy RJ, et al. Early acute antibody-mediated rejection of a negative flow cross match 3<sup>rd</sup> kidney transplant with exclusive disparity at HLA-DP. *Hum Immunol*. 2014;75(8):703-8.
- Gregorini M, Maccario R, Avanzini MA, Corradetti V, Moretta A, Libetta C, et al. Antineutropil cytoplasmic antibody-associated renal vasculitis treated with autologous mesenchymal stromal cells: evaluation of the contribution of immune-mediated mechanism. *Mayo Clin Proc*. 2013;88(10):1174-9.
- Bedino G, Esposito P, Bosio F, Corradetti V, Valsania T, Rocca C, et al. The role of therapeutic drug monitoring in the treatment of cytomegalovirus disease in kidney transplantation. *Int Urol Nephrol*. 2013;45(6):1809-13.
- Rampino T, Gregorini M, Guidetti C, Broggin M, Marchini S, Bonomi R, et al. KCNA1 and TRPC6 ion channels and NHE1 exchanger operate the biological outcome of HGF/scatter factor in renal tubular cells. *Growth Factors*. 2007;25(6):382-91.
- Gregorini M, Bosio F, Rocca C, Corradetti V, Valsania T, Pattonieri EF, et al. Mesenchymal stromal cells reset the scatter factor system and cytokine network in experimental kidney transplantation. *BMC Immunol*. 2014;3:15-44.
- Gregorini M, Fante CD, Pattonieri EF, Avanzini MA, Grignano MA, Cassaniti I, et al. Photopheresis abates the anti-HLA antibody titer and renal failure progression in chronic antibody-mediated rejection. *Biology (Basel)*. 2021;10(6):547.
- Billen EVA, Christiaans MHL, Doxiadis IIN, Voorter CEM, van den Berg-Loonen EM. HLA-DP antibodies before and after renal transplantation. *Tissue Antigens*. 2010;75(3):278-85.
- Hörmann M, Dieplinger G, Rebellato LM, Briley KP, Bolin P, Morgan C, et al. Incidence and impact of anti-HLA-DP antibodies in renal transplantation. *Clin Transplant*. 2016;30(9):1108-14.
- Redondo-Pachón D, Pascual J, Pérez-Sáez MJ, García C, Hernández JJ, Gimeno J, et al. Impact of preformed and de novo anti HLA DP antibodies in renal allograft survival. *Transpl Immunol*. 2016;34:1-7.
- Rosenberg WM, Bushell A, Higgins RM, Wordsworth BP, Wood KJ, Bell JI, et al. Isolated HLA-DP mismatches between donors and recipients do not influence the function or outcome of renal transplants. *Hum Immunol*. 1992;33(1):5-9.