



# A Late Coronary Stent Infection: Its Diagnosis and Surgical Treatment-A Case Report

Dhiren Shah<sup>1\*</sup>, Milan Chag<sup>2</sup>, Deepa Shah<sup>3</sup>, Dhaval Naik<sup>1</sup>, Amit Chandan<sup>1</sup>, Chintan Sheth<sup>1</sup>, Niren Bhavsar<sup>1</sup>, Hiren Dholakiya<sup>1</sup> and Parloop Bhatt<sup>4</sup>

<sup>1</sup>Department of Cardiac Surgery, CIMS Hospital, India

<sup>2</sup>Department of Cardiology, CIMS Hospital, India

<sup>3</sup>Department of Radiology, CIMS Hospital, India

<sup>4</sup>Department of Pharmacology, L. M. College of Pharmacy, India

## Abstract

Percutaneous Coronary Intervention (PCI) with drug eluting stent placement is a well-established treatment modality for coronary stenotic lesions. Although infection involving implanted stent is rare, it can occur at any point of time, leading to high morbidity and mortality. We describe a rare case of infected coronary stents complicated with recurrent stent thrombosis, sepsis and myocardial abscess formation after 2 years of PCI. Using multi-modality imaging final diagnoses to evaluate the precise location, extent and morphology of Myocardial Abscess (MA) was done. "On pump" Coronary Artery Bypass Graft (CABG) was performed, Left Anterior Descending (LAD) artery intramyocardially was opened up, about 7 ml to 10 ml of pus was evacuated and 2 Drug Eluting Stents (DES) were removed. The isolated identified organism was *Pseudomonas aeruginosa* which had remained dormant and restricted to the stent area for almost 2 years thinning the myocardium; an unusual trait of a very virulent bacterium which otherwise spreads fast to cause septicemia. The present case exemplifies the high index of clinical sensitivity with early multi-modality diagnosis, aggressive medical therapy, multidisciplinary care and timely surgical intervention saving the patient's life in otherwise fatal condition.

**Keywords:** Stent infection; Myocardial abscess; Cardiac magnetic resonance imaging; Positron emission tomography

## Introduction

Percutaneous Transluminal Coronary Angioplasty (PTCA) with metal stent placement has become a well-developed treatment modality for coronary stenotic lesions. Although infection involving implanted stent is rare, it can, however, occur with high morbidity and mortality. It is a potentially life-threatening disease, where early recognition and institution of appropriate medical and surgical therapy is vital for patient survival.

We describe an inserted coronary stent that was infected and complicated with recurrent stent thrombosis, sepsis and myocardial abscess formation. In an effort to raise awareness of the possible fatal outcome of this situation, we herein report our experience.

## Case Report

A 53 year old normotensive, non-diabetic male patient, with history of asthma underwent Percutaneous Coronary Intervention (PCI) in Left Anterior Descending (LAD) in 2015 wherein two Drug-Eluting Stents (DES) were implanted. Post procedure with no apparent cause patient had fever off and on which was treated with antibiotics as and when required.

He presented to our hospital after 2 years of PCI (In November 2017), with pyrexia in a hemodynamically stable state. His respiratory, abdominal and neurological examinations were normal. Three sets of blood cultures were sampled and empirical intravenous antibiotic treatment was initiated. Blood reports revealed leukocytosis with predominant neutrophilia and mild normochromic, normocytic anaemia. His Electrocardiogram (ECG) showed non-specific ST changes with no conduction abnormality. His chest X-ray was unremarkable. Transthoracic Echocardiography (TTE) showed hyper-refractile stent-possibility of thrombosis. There was a surrounding lucency sign of fluid collection possibly abscess around it.

## OPEN ACCESS

### \*Correspondence:

Dhiren Shah, Care Institute of Medical Sciences, Science City Road, Ahmedabad, India, Tel: 9825575933;

E-mail: dhiren.shah@cims.me

Received Date: 27 Jul 2018

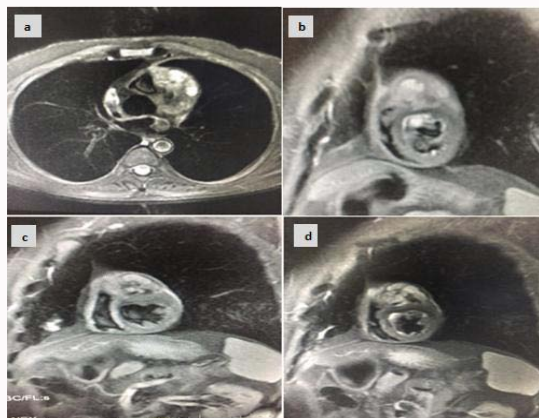
Accepted Date: 21 Aug 2018

Published Date: 28 Aug 2018

### Citation:

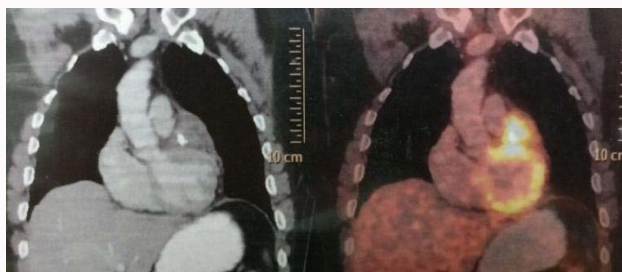Shah D, Chag M, Shah D, Naik D, Chandan A, Sheth C, et al. A Late Coronary Stent Infection: Its Diagnosis and Surgical Treatment-A Case Report. *Ann Cardiovasc Surg.* 2018; 1(3): 1013.

**Copyright** © 2018 Dhiren Shah. This is an open access article distributed under the Creative Commons Attribution License, which permits unrestricted use, distribution, and reproduction in any medium, provided the original work is properly cited.



**Figure 1A and B:** Pre-operative pre contrast T2W and Triple IR sequences showing abscess cavity.

**Figure 1C and D:** Pre-operative post contrast CMRI showing abscess cavity.



**Figure 2:** PET images showing high uptake around stent in proximal LAD with infective lesion.

Echocardiogram (Echo) showed reduced LV systolic function (LVEF=33%), moderately dilated LV and mildly dilated Left Atrium (LA) were also noted. Coronary Angiography (CAG) was suggestive of stent thrombosis. Cardiac Magnetic Resonance Imaging (CMRI) was performed with ECG gated T1W, T2W and post contrast sequences in multiple planes (Figure 1A and B). Standard CMRI sequences using balanced gradients, e.g., True Fast Imaging with Steady State Precession (FISP), and cine images were obtained. CMRI showed enhanced inflammatory/granulation soft tissue with multiple foci of internal tiny abscess along anterior inter ventricular groove encasing stent in LAD (Figure 1C and D). There was involvement of approximately more than 50% of thickness of sub epicardial myocardium (with only 2-3 mm of remaining myocardium) of anterior wall of LV along upper Right Ventricular (RV) insertion point and intra ventricular groove with involvement of adjacent epicardial fat and overlying parietal pericardium. It abuts Right Ventricular Outflow Tract (RVOT) and main pulmonary artery along lateral aspect without evidence of involvement. No evidence of extension of inflammatory soft tissue along course of left main artery was noted. The myopericardium interface was indistinct. Findings were in favor of infective etiology in form of abscess cavity. On cine sequences, hypokinesia of septum, apex and part of anterior wall with normal sized Right Atrium (RA), RV, Pulmonary Artery (PA) and aorta were observed.

All other valves were normal. Positron Emission Tomography (PET) scan confirmed the diagnosis of inflammation of Left Ventricular (LV) wall around LAD artery in anterior LV wall (Figure 2).

Patient was planned for abscess evacuation and CABG. “On

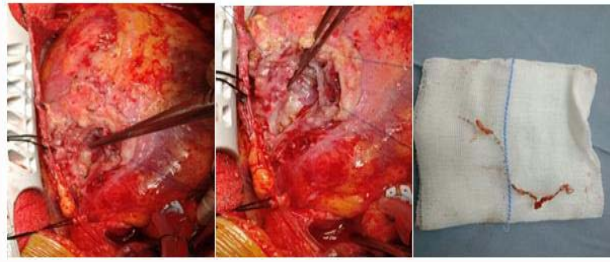
pump” procedure was performed. On dissection abscess around the artery and sinus from epicardium leading to the stent in the LAD artery was opened up and about 7ml-10 ml of pus was evacuated. Entire area was debrided and LAD artery intramyocardially was identified, opened up and both DES stents were removed (Figure 3). Proximal end and distal end of opened LAD artery were tied with 6-0 prolene. Floor of the abscess cavity was paper thin with only few mm of myocardium left out. After debridement and antibiotic wash, the abscess cavity was closed in two layers reinforced with Teflon patch. Saphenous vein graft was anastomosed to distal 1/3 of LAD artery, followed by proximal anastomosis on aorta. Patient was weaned off bypass in routine manner and shifted to Intensive Care Unit (ICU) in a stable condition. Next day patient was extubated and discharged on 8th day. Pus culture from myocardial abscess shows presence of only *Pseudomonas aeruginosa* bacteria. Histopathological examination did not show any granulomatous lesion. At 3 month follow up patient was doing well with no morbidity or sign of infection.

## Discussion

Myocardial Abscess (MA) is a spurious infection of the myocardium, endocardium, native or prosthetic valves, perivalvular structures, the cardiac conduction system and very rarely stents [1]. DES infections are rare, hard to treat, and potentially devastating [2]. Almost all untreated infected aneurysms in case of stent infection eventually lead to rupture [2]. Select characteristics of coronary stent procedures have been associated with an increased risk for infection, including vascular injury, persistence of an arterial sheath for greater than 24 hours, repeated punctures of the arterial access site, lengthy procedures and infection at a distal site that could be a potential source of coincident bacteraemia [3,4]. It is difficult to identify if it is a result of infection at the time of stent placement, or subsequent in stent balloon angioplasty, or of a hematogenous spread from another source of bacteremia. With such low numbers of reported infection, the exact mechanism of stent infections remains unclear. Despite the combined efforts of medical and surgical therapy, the mortality rate has been reported to be 38.9% [3].

While most published episodes of coronary stent infection occur within four weeks of stent placement [3], diagnosing MA after 2 years of PCI in this case was a challenge. Detection, localization and management of this patient were a challenge for the clinicians, surgeons as well as imaging specialists. In the present case high index of clinical suspicion and sensitivity to occurrence of fever and return of angina along with early multi-modality diagnosis, aggressive medical therapy, multidisciplinary care and timely surgical intervention saved the patient's life in otherwise fatal condition.

When imaging a suspected abscess, it is essential to accurately visualize its anatomical location. Earlier, most cases of MA were detected by autopsy. Although a challenge, today detection can be done antemortem, using noninvasive diagnostic modalities including TTE, Transoesophageal Echocardiography (TOE), radionuclide scintigraphy, Computed Tomography (CT) scan and CMRI [1] in the hands of expert radiologist's. TTE has a sensitivity of 23% and specificity of 98.6% in diagnosing MA [5]. TOE is considered the investigation of choice but a recent prospective study of 115 patients revealed it has only 48% sensitivity in diagnosing MA [6]. CMRI a noninvasive imaging modality with high temporal and spatial resolution can provide useful morphological evaluation to help make decision. To the best of our knowledge, no studies have compared the diagnostic value of TOE and CMRI in such cases. Few case



**Figure 3:** Intra operative images showing abscess cavity being evacuated and removal of stent.

reports and studies have suggested good diagnostic yield with CMRI in diagnosing annular abscess, subvalvular abscess and pseudoaneurysm in the setting of complicated Infective Endocarditis (IE) [1]. Radionuclide imaging using different radioisotopes like gallium-67, technetium-99 and indium-111 may serve a complementary role in diagnosing MA, by revealing a focal area of increased uptake in the myocardium suggesting the location of the abscess [7]. In this case final diagnosis was gathered using multi-modality imaging-from ECG, Echo, TTE, PET, CAG, CMRI to diagnose and evaluate the precise location, extent and morphology of MA.

If evidence demonstrates that the stent is infected, appropriate antibiotics should be instituted, the stent should be removed, and the infected tissue should be debrided [8]. Urgent surgery is recommended in most cases of MA since the preoperative risk and chances of rupture increase with the delay to surgery. However, the decision to perform emergency (same day) or urgent (1-2 days) surgery has to be made in individual cases depending on the clinical status of the patient, size of the abscess and thickness of the abscess wall. In the present case since the LAD was intramyocardial, it did not result in distinct aneurysm, but resulted in abscess destroying the surrounding myocardium standing probably as one of the cause of delayed presentation at 2 years with only few mm of myocardium left out. In this patient “On pump” CABG was performed, LAD artery intramyocardially was opened up, about 7ml to10 ml of pus was evacuated and 2 DES stents were removed.

In delayed stent infection the culprit organism is normally atypical mycobacterium which is related to the reuse of percutaneous transluminal angioplasty balloon and catheters [9]. However in the present case the isolated organism was *Pseudomonas Aeruginosa* a very virulent bacterium which spreads fast and can cause septicemia. Contrary, in this case it remained dormant and restricted to the stent area for almost 2 years.

The present case of life threatening MA was handled by multidisciplinary care involving cardiologists, microbiologists, cardiac radiologists and cardiothoracic surgeons whose timely recognition and institution of appropriate medical and surgical therapy was responsible for patient survival.

## Author's Contribution

Each author has contributed significantly to this submitted work.

## References

1. Iqbal J, Ahmed I, Baig W. Metastatic myocardial abscess on the posterior wall of the left ventricle: A case report. *J Med Case Rep.* 2008;2:258.
2. Elieson M, Mixon T, Carpenter J. Coronary Stent Infections-A Case Report and Literature Review. *Tex Heart Inst J.* 2012;39(6): 884-9.
3. Bosman W, Borger B, Schuttevaer H, Thoma S, Joosten H. Infections of intravascular bare metal stents: A case report and review of literature. *Eur J VascEndovascSurg.* 2014;4:87-99.
4. Morris T, Davies O, Bradlow W, Jeffery K, Bowler I. Endovascular stent-associated infection with *Staphylococcus lugdunensis*. *BMJ Case Rep.* 2013;2013:bcr2012008357.
5. Chakrabarti J. Diagnostic evaluation of myocardial abscesses. A new look at an old problem. *Int J Cardiol.* 1995;52:189-96.
6. Hill EE, Herijgers P, Claus P, Vanderschueren S, Peetermans WE, Herregods MC. Abscess in infective endocarditis: The value of transesophageal echocardiography and outcome: A 5-year study. *Am Heart J.* 2007;154:923-8.
7. Campeau R, Ingram C. Perivalvular abscess complicating infective endocarditis: Complementary role of echocardiography and indium-111-labeled leukocytes. *ClinNucl Med.* 1998;23:582-4.
8. Bouchart F, Dubar A, Bessou JP, Redonnet M, Berland J, MoutonSchleifer D, et al. *Pseudomonas aeruginosa* coronary stent infection. *AnnThoracSurg* 1997;64:1810-1813.
9. Soman R, Gupta N, Suthar M, Sunavala A, Shetty A, Rodrigues C. Intravascular stent-related endocarditis due to rapidly growing mycobacteria: A new problem in the developing world. *J Assoc Physicians India.* 2015;63(1):19.