



A Large Concha Bullosa Manifesting as Unilateral Nasal Mass: A Case Report and Literature Review

Shaden Zakariya Yahya Al Riyami*

Department of ENT, OMSB Resident, Oman

Abstract

A 14-year-old boy presented to the ENT clinic at Al Nahda Hospital, with left sided nasal obstruction, headache and postnasal drip symptoms that have been going on for 2 years. An anterior nasal rhinoscopic and endoscopic examination reveals a unilateral pink smooth mass, completely occupying the left nasal cavity and reaching to the anterior border of the inferior turbinate. Coronal and sagittal planes computer tomography demonstrate a huge left concha bullosa with a smaller one inside it. Both are of complete opacification, blocking the ostiomeatal complex and causing opacification of the left maxillary sinus. The mass is pushing the nasal septum causing a deviation to the contralateral side. The patient has undergone an excision of both concha bullosa as well as a left sided antrostomy. The patient reported an improvement and relieve of his symptoms post-operatively.

Keywords: Sinus; Computed tomography (CT); Hyposmia; Rhinoscopy

Introduction

The extensive use of paranasal sinus Computed Tomography (CT) and Endoscopic Sinus Surgery (ESS) have accentuated the significance of the paranasal sinus anatomy and its variations [1]. It is essential for the surgeon, as well as the radiologist to be aware of the details of the lateral nasal wall anatomical variations. Recognizing these variations preoperatively reduces the rate of possible intraoperative complications [2].

The medial wall of the ethmoid sinus is formed by the middle turbinate. The middle turbinate plays a role in the humidification, upper airway lubrication, airway and temperature regulation, and olfaction and filtering the inhaled air [3].

The literature has described various types of middle turbinate, including pneumatized, paradoxically curved, bifurcate, trifurcate, secondary and accessory [3].

The term Concha Bullosa is referred to an aerated turbinate, which is commonly present in the middle turbinate. The location and the degree of pneumatization determine the symptoms of a concha bullosa [4].

Case Presentation

This case report describes a 14-year-old boy, presented to our ENT clinic, at Al Nahda Hospital, complaining of left sided nasal obstruction, post nasal drip, hyposmia and purulent rhinorrhea for two years. The patient did not complain of any headache, facial pain or fever. He did not have history of any other medical problems, and did not undergo any surgical procedures in the past. On examination, the patient was found to have a broad nasal dorsum with broad alar base and drooping of the nasal tip. Anterior rhinoscopy revealed a mass occupying left nasal cavity. Nasal endoscopy revealed a mass with a smooth surface, overlaid with a normal nasal mucosa and its inferior edge reaching the inferior border of inferior turbinate. Some purulent nasal discharge was noticed on its surface and on palpation it was bony hard (Figure 1). The anterior nasal septum was pushed to the right side. Right nasal cavity looks normal apart from a deviated nasal septum. Ears, throat and neck examination was normal. The patient was otherwise healthy, and results of his routine laboratory tests were normal. Computed Tomography (CT) further demonstrated an extensively pneumatized middle turbinate engulfing another smaller pneumatized middle turbinate, extending from nasal bone anteriorly to the level of the posterior ethmoids air cells, measuring 2 cm × 3 cm and causing significant nasal septum deviation to the right side. In addition to complete opacification of frontal sinuses and ethmoidal air cells (Figure 2a and 2b). The giant concha was of complete opacification and

OPEN ACCESS

*Correspondence:

Shaden Zakariya Yahya Al Riyami,
Department of ENT, OMSB Resident,
Oman, Tel: (00968)98990064;
E-mail: shaden_zr@yahoo.com

Received Date: 12 Aug 2020

Accepted Date: 28 Aug 2020

Published Date: 31 Aug 2020

Citation:

Al Riyami SZY. A Large Concha Bullosa Manifesting as Unilateral Nasal Mass: A Case Report and Literature Review. *Ann Clin Otolaryngol.* 2020; 5(1): 1044.

Copyright © 2020 Shaden Zakariya Yahya Al Riyami. This is an open access article distributed under the Creative Commons Attribution License, which permits unrestricted use, distribution, and reproduction in any medium, provided the original work is properly cited.

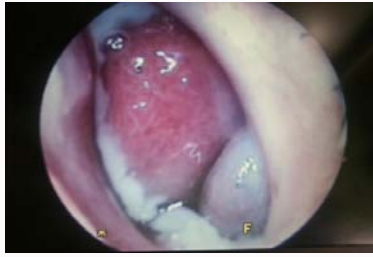

Figure 1: Endoscopic view of the giant concha bullosa presenting as a unilateral nasal mass.

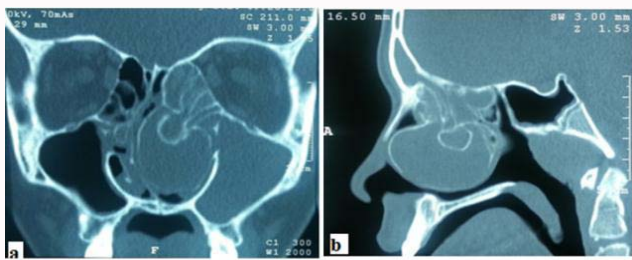


Figure 2: CT a) coronal and b) sagittal cuts demonstrate large concha bullosa contains a smaller one, both of complete opacification, causing a deviation of the nasal septum to the right side and obliteration of the osteomeatal complex on the same side.

engulfing another much smaller chocha bullosa, completely opacified as well. The patient underwent transnasal endoscopic surgery, concha bullosa excision, under general anesthesia. An incision in the anterior wall of the large concha was made; thick pus discharge came out of the incision. Lateral lamella of the large concha was removed, and medial lamella was trimmed. Lateral lamella of the small concha was also removed and similarly, thick pus was drained. Uncinectomy and antrostomy was performed on the same side. Post operatively, the patient's condition remained stable and his symptoms improved.

Discussion

Concha bullosa has been defined as any aeration of the middle turbinate [5]. The symptoms caused by concha bullosa depend on the size of the concha and its effect on adjacent structures. This case report describes an unusual anatomical variation of the middle turbinate. Our patient presented with a unilateral huge mass, occupying the left nasal cavity, containing another smaller concha both of pus discharge content. This is the second reported case of a giant concha presents as a unilateral nasal mass.

Bolger et al. [6] classified pneumatization of concha bullosa into three groups. They referred to pneumatization localized to the vertical lamella of the middle concha as "lamellar concha bullosa," pneumatization localized to the inferior (or bulbous) pair of the concha as "bulbous concha bullosa," and extensive pneumatization to both the vertical lamella and the bulbous part of the of the concha as "extensive concha bullosa." The degree of pneumatization is directly proportional to the severity of symptoms. Whereas the lamellar and bulbous types are usually asymptomatic, extensive bullous concha manifests symptoms.

A deviated nasal septum to the opposite side of the concha was seen in the CT of our patient. Jamie et al. studied the incidence of concha bullosa and its relationship to nasal septal deviation and paranasal sinus disease [6]. His paper concluded that there is a strong association between the presence of a concha bullosa and contralateral deviation of the nasal septum.

Furthermore obliteration of osteomeatal complex in both sides was also noted in our case. However, in the same paper, Jamie et al. failed to prove a statistically significant relationship between any sinus disease and the presence of a unilateral or dominant concha bullosa [6].

Concha bullosa can manifest in various ways our case presented with a unilateral nasal mass. Jin Yong Jang et al. [4] described a similar case in 2009 and it was published in the Korean Journal of Otolaryngology and Head and Neck Surgery. That report dealt with a giant concha bullosa of middle turbinate of 4.5 cm in length, 2.2 cm in width size causing complete nasal obstruction [4].

In 2012, Ibrahim Cukurova et al. [1] described a 53-year-old Caucasian woman who presented with concha bullosa in another concha bullosa [2]. Similarly our patient was found to have a smaller concha within a giant concha. Nevertheless, both concha in our patient were undergoing an inflammatory process, resulting in the collection of thick pus discharge.

Conclusion

Concha bullosa is a common anatomic variant. A number of variations been described in the literature. There is a correlation between these variations and the manifestations it can cause. Studying these variations and identifying them will assess in providing the proper management to the patient.

References

1. Cukurova I, Yaz A, Gumussoy M, Yigitbasi OG, Karaman Y. A patient presenting with concha bullosa in another concha bullosa: A case report. *J Med Case Rep.* 2012;6(1):87.
2. Ozgursoy OB, Kucuk B. Giant concha bullosa containing another concha bullosa inside: Unique anatomic variation of the middle turbinate. *Rhinology.* 2007;45(3):248–50.
3. Peric A, Baletic N, Sotirovic J. A case of an uncommon anatomic variation of the middle turbinate associated with headache. *Acta Otorhinolaryngol Ital.* 2010;30(3):156–9.
4. Jang JY, Han JH, Park DH, Kim KT. A case of giant concha bullosa causing complete unilateral obstruction of nasal cavity. *Korean J Otorhinolaryngol-Head Neck Surg.* 2009;52(4):369.
5. Stallman JS, Lobo JN, Som PM. The incidence of concha bullosa and its relationship to nasal septal deviation and paranasal sinus disease. *Am J Neuroradiol.* 2004;25(9):1613–8.
6. Bolger WE, Butzin CA, Parsons DS. Paranasal sinus bony anatomic variations and mucosal abnormalities: CT analysis for endoscopic sinus surgery. *Laryngoscope.* 1991;101(1 Pt 1):56–64.