



A Case Report of Parapharyngeal Space Tumour

Melissa Laus^{1*}, Luciano Magaldi^{2*}, Domenico Crescenzi², Marco Radici² and Adelchi Croce¹

¹Department of ENT, University "G D'Annunzio" of Chieti-Pescara, Italy

²Department of Head and Neck Oncology, University of Foggia, Italy

³UOC of Otolaryngology, General Hospital "S. Giovanni Calibita - Fatebenefratelli", Italy

Abstract

The parapharyngeal space is a virtual anatomic region that extends from the base of the skull to the hyoid bone. It plays an important role for the great variety of structures that contains and for the varied nature of the tumors it can contain. Benign tumors account for approximately 80% with the pleomorphic adenoma being the most frequent. It can develop *de novo* or may arise from deep lobe of the parotid and extend through the stylomandibular tunnel into the parapharyngeal space. Symptoms are usually rare or not significant but if not diagnosed early, continued expansion may result in potential life-threatening complications. The aim of this report is to present the symptoms and clinical signs, diagnostic procedures, surgical approach and histopathological findings of one case of primary pleomorphic adenoma.

Introduction

The parapharyngeal space (PPS) is a well-defined anatomic region extending from the skull base to the hyoid bone. This deep anatomical space has the shape of an inverted triangular pyramid with a base, a vertex, and 3 walls. The base (upper limit) is the petrotympanic region of the temporal bone, and the vertex (lower limit) is the greater horn of the hyoid bone. The external wall comprises the sternocleidomastoid muscle and its aponeurosis, the superficial cervical aponeurosis lining the parotid, and the ascending branch of the lower jaw, with the pterygoid and masseter muscles. The medial wall is formed by the lateral face of the pharynx. The posterior wall is formed by the aponeurosis, the prevertebral muscles and the cervical transverse apophyses [1]. This space is divided into the prestyloid and poststyloid compartment by layers of fascia extending from the styloid process to the tensor-vascular-styloid fascia which is comprise by tensor veli palatine muscle, its fascia, the stylopharyngeal and the styloglossus muscle [2-4]. The anterior or prestyloid compartment is occupied by the deep lobule of the parotid, fat, and lymph nodes, the internal maxillary artery and the inferior, lingual and auriculotemporal alveolar nerves. The posterior or poststyloid compartment contains the neurovascular axis, comprising the carotid artery, the jugular vein, the cervical sympathetic chain and the IX, X, XI, and XII nerve pairs [1,5].

The PPS is important for the diversity of structures it houses and for the varied nature of the tumors it can contain (primary tumors, metastatic lymph nodes and involvement from adjacent neoplasms). These tumors are rare, accounting for 0.5% of all head and neck tumors. They are known as pharyngomaxillary, pterygomandibular, pterygopharyngeal or lateropharyngeal tumors. Benign tumors account for approximately 80% while the remainings are malignant tumors [4]. In the prestyloid space, salivary gland neoplasms (especially parotid gland pleomorphic adenomas) are the most common, while neurogenic tumours (e.g. schwannomas and neurofibromas) are those most commonly affecting the poststyloid. Pleomorphic adenoma can develop *de novo* or may arise from deep lobe of the parotid and extends through the stylomandibular tunnel into the PPS [6].

Other less common neoplasms include: vascular tumours (paragangliomas), chordomas, lipomas, lymphomas, chemodectomas, rhabdomyomas, chondrosarcomas, desmoid tumours, ameloblastomas, amyloid tumours, ectomesenchymomas, fibrosarcomas and plasmocytomas [4].

The symptoms and clinical manifestations of these tumors are multiple and relate to the prestyloid and poststyloid localization. The symptoms include frequent foreign body sensation, difficult deglutition, ontological symptoms and hoarseness. While, the clinical manifestations include a mass in the oropharynx, a neck mass, cranial nerve deficit and Eustachian tube obstruction [7-11]. Symptoms are usually rare or not significant for Pleomorphic adenoma in the PPS [12].

If the tumors are not diagnosed early, continued expansion of even benign tumors may result in

OPEN ACCESS

*Correspondence:

Melissa Laus, Department of ENT,
University of Chieti, Via dei Vestini
5, 66013, Chieti, Italy, Tel: + 39 0871
552033/358375;

E-mail: Melissa.laus@hotmail.it

Received Date: 30 Nov 2016

Accepted Date: 16 Jan 2017

Published Date: 18 Jan 2017

Citation:

Laus M, Magaldi L, Crescenzi D,
Radici M, Croce A. A Case Report of
Parapharyngeal Space Tumour. *Ann
Clin Otolaryngol.* 2017; 2(1): 1006.

Copyright © 2017 Melissa Laus. This is an open access article distributed under the Creative Commons Attribution License, which permits unrestricted use, distribution, and reproduction in any medium, provided the original work is properly cited.

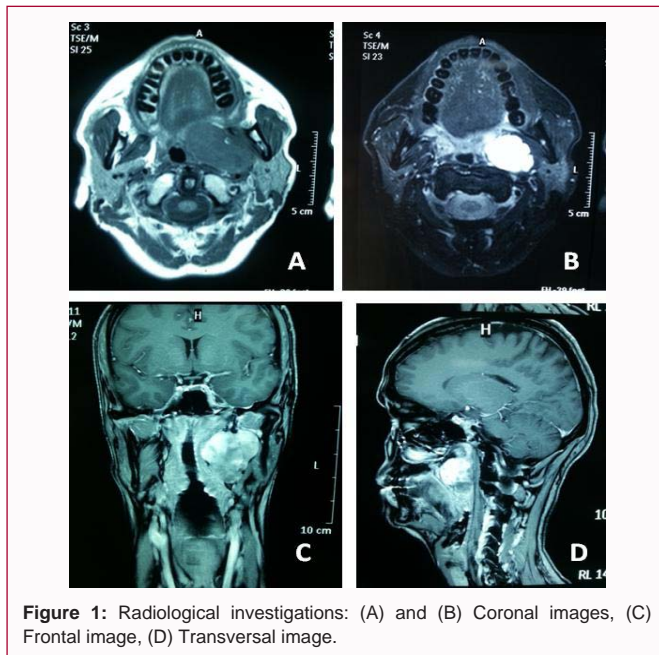


Figure 1: Radiological investigations: (A) and (B) Coronal images, (C) Frontal image, (D) Transversal image.

potential life-threatening complications, such as airway obstruction, and may lead to cranial nerve compression with significant organ dysfunctions [13,14]. Imaging, in particular computed tomography (CT) with contrast medium, magnetic resonance (MR) and angiography, is essential for information on localization, extent, and the nature of the tumor itself. While the Fine Needle Aspiration Cytology (FNAC) is very specific (accurate in 90-95% of cases) for the histological diagnosis [9]. Open biopsy is not advised, due to the risk of bleeding, opening of the capsule and, accordingly, relapse and seeding to neighbouring tissues [15,16].

Surgery is performed on the basis of information provided by CT or MRI and it requires adequate exposure to identify and protect the anatomic vital structures.

Case Presentation

An otherwise healthy 44-year-old Caucasian woman was referred to us with a diagnosis of tumour in the left PPS. The patient had initially noted a left intraoral mass in the 6 month earlier and a discomfort and foreign body sensation when swallowing in the 1 month earlier. She did not present other associated symptoms. On intraoral examination showed left intraoral mass displacing the soft palate medially and extending to the oropharynx. There was no significant lymph nodes enlargement in the neck. Clinical examination did not reveal involvement of any of the cranial nerves. No other abnormalities were found in the head and neck region. We performed of radiological investigations to better characterize the lesion (Figure 1). After obtaining the patient's informed consent to the surgical procedure, we performed a security tracheotomy and a complete excision of the lesion using the trans-oral approach. The oral cavity was exposed using a retractor, an incision was made in the lateral part of the soft palate, the muscular plane was bisected in order to directly see the tumor (Figure 2). The tumor was separated from the other structures without breaking the capsule. After enucleation, the lateral wall of the pharynx was repaired by planes, using absorbable suture (Figure 3A). On gross examination the lesion was composed by two well demarcated masses measuring 3.5 x 2 x 1 cm and 3.5 x 3 x 1, were encapsulated with a yellowish, irregular,

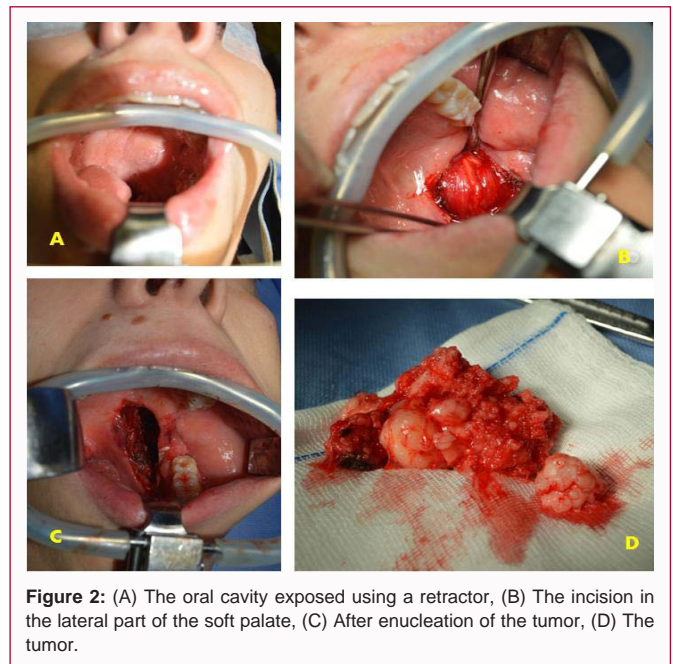


Figure 2: (A) The oral cavity exposed using a retractor, (B) The incision in the lateral part of the soft palate, (C) After enucleation of the tumor, (D) The tumor.

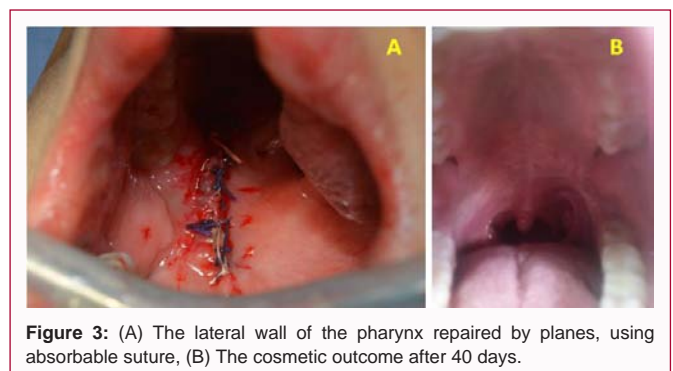


Figure 3: (A) The lateral wall of the pharynx repaired by planes, using absorbable suture, (B) The cosmetic outcome after 40 days.

bosselated surface. Histological examination revealed a pleomorphic adenoma. Her postoperative course was regular: on 3 postoperative day, the tracheal cannula was removed, on day 5, the nasogastric tube was removed and then she began oral feeding. The cosmetic outcome was very good (Figure 3B).

Discussion

The prestyloid compartment is often affected by cancers with location in the deep lobe of the parotid gland, representing more than 50% of all parapharyngeal cancers. These tumors are usually benign and are given by pleomorphic adenoma that develops in the deep lobe of the gland or in a polycentric modality in the two lobes, sometimes taking the shape of a hourglass. These tumors end up in parapharyngeal space because of the constantly increasing volume and the slow development. Infact, they can reach this seat for natural evolution since this space presents less resistance to their spread than others [17].

CT scan and MRI are important diagnostic tools, they help in determining the extent of disease, the local spread and the type of tumour. MRI has been shown to be superior to computed tomography in the investigation of parapharyngeal space tumours [9].

The treatment of pleomorphic adenoma is essentially surgical. In surgery of the PPS tumors, the surgeon must take care not to damage and rupture the capsule of the pleomorphic adenoma. The success of

the surgery in the PPS depends mainly on two conditions.

1. Correct identification and exposition of PA to allow complete removal and prevent the recurrence possibility.
2. Minimum functional and aesthetic morbidity taking into account the risks of surgery in this space [18].

The intraoral approach has been described for the removal of small benign extraparotid neoplasms that originate in the prestyloid compartment. The simple cervical approach is used in extra-parotid tumors of small size that can be removed by means of research and digital dissection. The transparotid approach is indicated for tumors of the deep lobe of the parotid while a combined transparotid–intraoral approach by preservation of the superficial parotid lobe was employed for removal giant PAs involving the prestyloid compartment of the PPS (as happened in our case report) [19]. The present case report has brought to light another issue: to do or not a prophylactic tracheotomy before surgery. In our experience, we decided to perform it before removal of the tumor.

Conclusion

Parapharyngeal tumors are infrequent in the population and initially asymptomatic due to their peculiar anatomical location. Diagnosis is based on radiology, CT or MRI, and in certain cases we will need to perform conventional angiographies. The surgical approach depends on the location and dimensions of the tumor.

References

1. Suarez-Fente V, Llorente-Pendas JL, Gomez-Martinez J, Garcia-Gonzalez LA, Lopez-Alvarez F, Suarez-Nieto C. Primary tumours of the parapharyngeal space. Our experience in 51 patients. *Acta Otorrinolaringol Esp.* 2009; 60: 19-24.
2. Attia A, El-Shafiey M, El-Shazly S, Shouman T, Zaky I. Management of parapharyngeal space tumors at the National Cancer Institute, Egypt. *J Egypt Natl Canc Inst.* 2004; 16: 34-42.
3. Lombardi D, Nicolai P, Antonelli AR, Maroldi R, Farina D, Shaha AR. Parapharyngeal lymph node metastasis: an unusual presentation of papillary thyroid carcinoma. *Head Neck.* 2004; 26: 190-196.
4. Bozza F, Vigili MG, Ruscito P, Marzetti A, Marzetti F. Surgical management of parapharyngeal space tumours: results of 10-year follow-up. *Acta Otorhinolaryngol Ital.* 2009; 29: 10-15.
5. Work W, Hybels RL. A study of tumors of the parapharyngeal space. *Laryngoscope.* 1974; 84: 1748-1755.
6. Rodriguez-Giurana J, Rodado C, Saez M, Bassas C. Giant parotid pleomorphic adenoma involving the parapharyngeal space: report of a case. *J Oral Maxillofac Surg.* 2000; 58: 1184-1187.
7. Allison RS, Waal VD, Snow GB. Parapharyngeal tumors-a review of 23 cases. *Clin Otolaryngol Allied Sci.* 1989; 14: 199-203.
8. Carrau RL, Myers EN, Johnson JT. Management of tumors arising in the parapharyngeal space. *Laryngoscope.* 1990; 100: 583-589.
9. Khafif A, Segev Y, Kaplan DM, Gil Y, Fliss DM. Surgical management of parapharyngeal space tumors-a 10 year review. *Otolaryngol Head Neck Surg.* 2005; 132: 401-406.
10. Myers EN, Johnson JT, Curtin HG. Tumors of parapharyngeal space. Myers EN, Suen JY, Myers JN, Hanna EY, eds, 4th ed. In: *Cancer of the Head and Neck*, vol. 22. Philadelphia: WB Saunders 2003: 511-513.
11. Work PW, Hybels RL. A study of tumors of the parapharyngeal space. *Laryngoscope* 1974; 1748-1755.
12. Sergi B, Limongelli A, Scarano E, Fetoni AR, Paludetti G. Giant deep lobe parotid gland pleomorphic adenoma involving the parapharyngeal space. Report of three cases and review of the diagnostic and therapeutic approaches. *Acta Otorhinolaryngol Ital.* 2008; 28: 261-265.
13. Lau WF, Lam KH, Wei W. Parapharyngeal space tumours. *Aust N Z J Surg.* 1986; 56: 835-42.
14. Shaw CK, Sood S, Bradley PJ, Krishnan S. Unusual mass in the parapharyngeal space: a warthin's tumour. *ANZ J Surg.* 2006; 76: 193-194.
15. Acosta L, Montalvao P, Magalhaes M, Olias J, Santiago N. Parapharyngeal space tumors. Our experience. I.P.O. Francisco Gentil, Lisbon. *Acta Otorrinolaringol Esp.* 2002; 53: 485-490.
16. Ferro MF, Sanroman JF, Lopez AC, Gutierrez JS, De Sanchez AL. Surgical treatment of benign parapharyngeal space tumours. Presentation of two clinical cases and revision of the literature. *Med Oral Patol Oral Cir Bucal.* 2008; 13: E61-E64.
17. Chiamenti C, Rodriguez S, Staffa and A. Gentile. *Chirurgia della parotide e delle ghiandole salivari minori.* Masson vol. 2 cap. 11 pag. 103-115.
18. Infante-Cossio P, Gonzalez-Cardero E, Gonzalez-Perez LM, Leopoldo-Rodado M, Garcia-Perla A and Esteban F. Management of parapharyngeal giant pleomorphic adenoma. *Oral Maxillofac Surg.* 2011; 15: 211-216.
19. Dimitrijevic MV, Jescic SD, Mikic AA, Arsovic NA, Tomanovic NR. Parapharyngeal space tumors: 61 case reviews. *Int J Oral Maxillofac Surg.* 2010; 39: 983-989.