



Aneurysm Bone Cyst like Angiosarcoma of the Breast

Rodrigo Y Adame-Moreno¹, Claudia A Caro-Sánchez², Mariana Cobos-Ortiz² and Rafael Vázquez-Romo^{3*}

¹Department of Surgery, National Cancer Institute, Mexico

²Department of Pathology, National Cancer Institute, Mexico

³Department of Breast Cancer, Division of Surgery, National Cancer Institute, Mexico

Clinical Image

We present the case of a 49-year-old woman with a history of breast tumor, right side, 5.5 cm × 5 cm, mammography and breast ultrasound showed a BIRADS 5 category (Figures 1 and 2).

A core biopsy showed a Fibroadenoma with infiltrating lobular carcinoma (ILC) SBR 4, with signet ring cells, infiltrating ductal carcinoma (IDC) SBR 6, lobular carcinoma *in situ* (LC*si*) and ductal carcinoma *in situ* (DC*is*), immunohistochemistry showed positive estrogen and progesterone

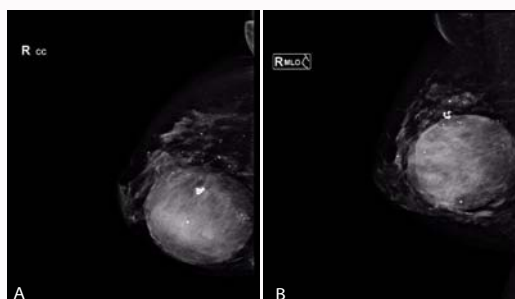


Figure 1: A & B) Mastography shows a round, mixed-density nodule, partially circumscribed in the central zone in right breast.

OPEN ACCESS

*Correspondence:

Rafael Vázquez-Romo, Department of Breast Cancer, Division of Surgery, National Cancer Institute, 14080, Mexico, Tel: 525556280400;

E-mail: vrrafa@yahoo.com.mx

Received Date: 16 May 2017

Accepted Date: 01 Jun 2017

Published Date: 11 Jun 2017

Citation:

Adame-Moreno RY, Caro-Sánchez CA, Cobos-Ortiz M, Vázquez-Romo R. Aneurysm Bone Cyst like Angiosarcoma of the Breast. *World J Breast Cancer Res.* 2017; 1(1): 1001.

Copyright © 2017 Vázquez-Romo

R. This is an open access article distributed under the Creative Commons Attribution License, which permits unrestricted use, distribution, and reproduction in any medium, provided the original work is properly cited.

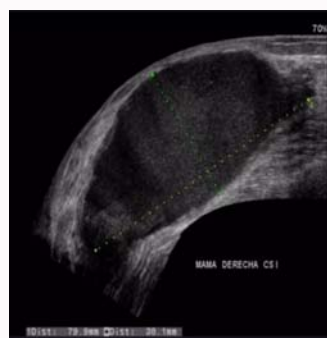

Figure 2: Ultrasound shows an anechoic heterogeneous nodule with internal echoes and a thick wall with dimensions of 90 mm × 80 mm × 90 mm.

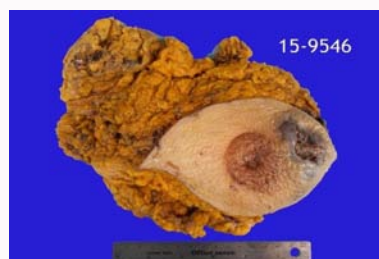

Figure 3: Macroscopic image (MRMD). We observe on the internal superior quadrant, an ulcer of 2.4 cm × 2.1 cm, with elevated edges, necrotic and hemorrhagic material on its interior. Nipple retraction. The tumor was irregular, with necrotic and hemorrhagic areas, a white glandular wall with ill-defined margins of 7.5 cm × 5 cm × 4 cm.

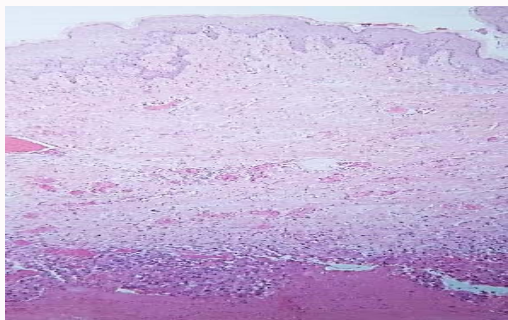


Figure 4: We observe the skin and the tumor beneath it at a mural level.

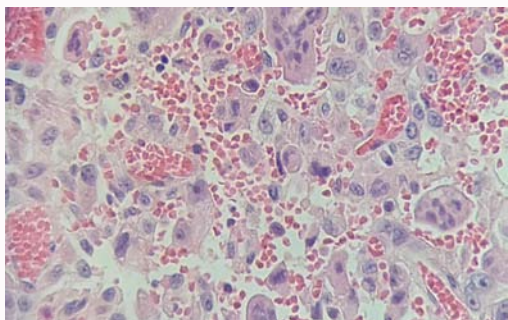


Figure 5: We observe vascular spaces with erythrocytes. These channels are covered by pleomorphic and some giant cells, with atypia, prominent nucleolus and intravascular spaces with lone cells or giant cells.

receptors and Her-2/neu negative. She received neo-adjuvant chemotherapy she underwent a modified radical mastectomy. Histopathology showed an aneurysm bone cyst like angiosarcoma, grade 3, with giant cells, 7.5 cm × 7 cm × 4 cm, a focal area with ILC, the axilla with 12 negative lymph nodes; immunochemistry positive for CD31, CD 136, ER positive at 140 Ki67 of 2% and negative for CKAE/AE3, PR, HER-2/neu (Figures 3-6). The patient received adjuvant radiotherapy. She is currently without local or metastatic disease.

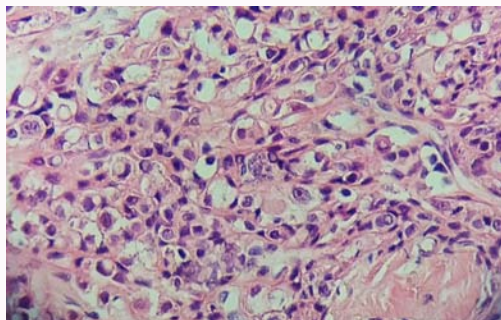


Figure 6: Morphologic with signet ring cells, with irregular nucleus, a prominent nucleolus; cells in single file or nest pattern showing invasiveness.