



# Usefulness of Duplex Color-Coded Ultrasonography in the Cervical Rotational Position in Combination with Head MRI and MRA for the Diagnosis of Vertebrobasilar Insufficiency

Kuruma T\*, Arimoto M, Yo K, Kawade Y, Kondo A, Uchida Y, Ogawa T and Fujimoto Y

Department of Otorhinolaryngology, Head and Neck Surgery, Aichi Medical University, Aichi, Japan

## Abstract

**Background:** The purpose of this study was to confirm whether the 3-dimensional hemodynamics of the vertebrobasilar artery system can be evaluated using a combination of ultrasonography, head and neck Magnetic Resonance Imaging (MRI), and Magnetic Resonance Angiography (MRA) as a diagnostic method for Vertebrobasilar Insufficiency (VBI).

**Materials and Methods:** Subjects were 40 patients with suspected VBI based on clinical symptoms seen between January 2016 and December 2017 (22 males, 18 females; mean age, 78.1 years). Cervical ultrasonography and MRI and MRA of the head and neck were performed on all patients. Changes in VA blood flow in the mid-neck and cervical rotation positions were also measured and compared. We compared blood flow status of the vertebral artery measured by cervical ultrasonography with morphological changes such as stenosis and occlusion of the vertebral artery measured by MRI and MRA.

**Results:** Eight patients showed VA blood flow changes in cervical rotation on cervical ultrasonography. Of these patients, three had normal cervical ultrasound in the mid-neck position with no problems with VA blood flow, and 3 patients showed no problems on MRA. Of the 17 patients with no VA occlusion on cervical ultrasonography, MRI showed internal carotid artery lesions in 6 cases and VA dissection in 1 case, while MRA showed VA lesions in 6 cases.

**Conclusion:** In the diagnosis of VBI, we considered that cervical ultrasonography alone is insufficient, but in combination with MRA can help to construct a 3-dimensional picture of blood flow dynamics in the patient.

**Keywords:** Vertebrobasilar Insufficiency (VBI); Ultrasonography; MRI; MRA

## Introduction

Vertebrobasilar artery Insufficiency (VBI) is a general term for conditions in which organic or functional abnormalities of the vertebrobasilar artery system result in impaired blood flow or ischemia in the territory predominantly supplied by the vertebrobasilar artery [1,2]. According to the World Health Organization criteria proposed in 1988, Transient Ischemic Attack (TIA) is defined as rapidly developing clinical signs of focal or global disturbance of cerebral function, lasting less than 24 h, with no apparent non-vascular cause [3]. VBI is thought to be similar to TIA and is considered a type of TIA of the vertebrobasilar artery system. TIA of the vertebrobasilar artery system. The definition of VBI as a pathological entity differs among experts, and no consensus has been reached [4].

TIA is mainly caused by atherothrombosis, cardiogenic/non-cardiogenic emboli, and hemodynamic abnormalities in the vertebrobasilar artery system, and VBI is thought to have a similar pathogenesis. In addition, the pathogenesis of VBI also includes divergence, malformation, and spasm of the vertebrobasilar artery, as well as external compression due to aortitis syndrome and cervical spine abnormalities. For example, bow hunter's stroke, in which the Vertebral Artery (VA) is compressed at the level of the annulus and axial vertebrae due to neck rotation, and Powers' syndrome, in which the VA is compressed during neck extension and rotation due to malformation of the origin of the VA and thickening of the anterior scalene muscle [5,6].

## OPEN ACCESS

### \*Correspondence:

Tessei Kuruma, Department of Otorhinolaryngology, Head and Neck Surgery, Aichi Medical University, 1-1 Yazakokarimata, Nagakute-shi, Aichi 480-1195, Japan, Tel: +81 561 62 3311; Fax: +81 561 63 3403; E-mail: kuruma.tessei.231@mail.aichi-med-u.ac.jp

Received Date: 27 Apr 2022

Accepted Date: 18 May 2022

Published Date: 25 May 2022

### Citation:

Kuruma T, Arimoto M, Yo K, Kawade Y, Kondo A, Uchida Y, et al. Usefulness of Duplex Color-Coded Ultrasonography in the Cervical Rotational Position in Combination with Head MRI and MRA for the Diagnosis of Vertebrobasilar Insufficiency. *Am J Otolaryngol Head Neck Surg.* 2022; 5(7): 1198.

**Copyright** © 2022 Kuruma T. This is an open access article distributed under the Creative Commons Attribution License, which permits unrestricted use, distribution, and reproduction in any medium, provided the original work is properly cited.

The diagnostic guidelines of the Japan Society for Equilibrium Research (1995) emphasize the presence of neurological symptoms, stating that VBI should be suspected in cases of vertigo that is easily induced by cervical movements or positional changes and is accompanied by neurological symptoms [2]. However, many reports have described VBI occurring with vertigo alone [7,8]. If the direct cause of vertigo can be proven to be impaired blood flow in the vertebrobasilar artery system, considering vertigo symptoms alone as VBI seems reasonable. To evaluate the circulatory dynamics of the vertebrobasilar artery system, imaging modalities such as Magnetic Resonance Angiography (MRA), Digital Subtraction Angiography (DSA) or 3-Dimensional (3D) Computed Tomographic Angiography (CTA) are the main methods used to show organic and irreversible lesions in the brain parenchyma and cerebral vessels.

However, functional imaging is necessary to confirm the hemodynamics of the VA and Basilar Artery (BA). We performed ultrasonography of the neck as an aid in the diagnosis of vertebrobasilar artery circulatory insufficiency. In this study, we examined whether neck ultrasonography offers a screening method for the diagnosis of VBI due to hemodynamic abnormalities.

## Materials and Methods

### Subjects

This retrospective analysis investigated 40 patients (22 males, 18 females; mean age,  $70.4 \pm 10.95$  years; range, 38 to 83 years) who visited our clinic between January 2016 and December 2017 with a chief complaint of dizziness and suspected VBI based on clinical symptoms. VBI was diagnosed without regard to the presence or absence of neurological symptoms. If the patient was elderly and had underlying diseases such as hypertension, diabetes mellitus, lipid abnormalities, or arrhythmia, or had recurrent dizziness, possible VBI or circulatory VBI was diagnosed [4].

### Methods

All patients underwent cervical ultrasonography as well as Magnetic Resonance Imaging (MRI) and MRA of the head. For MRA, not only intracranial but also cervical images were taken to visualize the entire vertebrobasilar artery.

### Cervical ultrasonography

**Method and items for measuring blood flow in the VA:** For the neck ultrasonography, a color Doppler ultrasound system (SSA 270A; Toshiba Medical Systems Corp.,

Otawara-shi, Tochigi-ken, Japan) was used together with 5- and 7.5-mHz transducers.

The neck echo measured blood flow status of the VA and Internal Carotid Artery (ICA). The method of delineation of the VA is described below. First, the common carotid artery was delineated in the longitudinal direction. The vertebral vein and VA running between them were observed. The deeper part was taken as the VA.

The VA was identified by B-mode and color Doppler methods, and the diameter of the VA was measured. In addition, Peak Systolic Velocity (PSV) and end-diastolic velocity were measured using the pulsed Doppler method, and the time-averaged maximum flow velocity was calculated as the mean blood flow velocity (V mean).

**Measurement of VA blood flow and determination of blood flow decrease by neck rotation method:** Blood flow velocity in the VA was measured in the supine position and in the VA on the side

contralateral to the direction of rotation while the neck was rotated 45° to the right and left. Supine PSV (PSV-S) and PSV during neck Rotation (PSV-R) were compared, and a flow velocity change of  $\geq 20\%$  ( $(PSV-S - PSV-R)/PSV-S \geq 0.2$ ) in either left or right head positions was judged to represent a decrease in blood flow.

**Estimation of the site of VA occlusion:** The VA occlusion site flow chart by Saito et al. was used to infer the site of VA occlusion from VA blood flow status on cervical ultrasonography [9]. Based on VA blood flow velocity and vessel diameter, VA occlusion was classified into VA origin, before the Posterior Inferior Cerebellar Artery (PICA) bifurcation, after the PICA bifurcation, or at the end of the PICA (Figure 1).

**Detection of stenosis rate of the internal carotid artery:** The stenosis rate of the ICA was measured. The degree of stenosis was determined by the percentage of stenosis due to plaque formed in the lumen of the ICA, and the degree of stenosis was defined as: Grade 3, severe stenosis  $\geq 70\%$ ; Grade 2, moderate stenosis, 69% to 50%; Grade 1, mild stenosis,  $<50\%$  but  $>0\%$ ; or Grade 0, no stenosis [10].

### Comparison between cervical ultrasonography and MRI/MRA

We compared the status of blood flow in the VA measured by cervical ultrasonography with morphological changes such as stenosis and occlusion of the VA as measured by MRI and MRA.

### Study items and statistical methods

The items to be examined were as follows. Pearson's correlation analysis was used to analyze the correlations.

- Correlation between mean blood flow velocity (V mean) of right and left VAs and age.
- Correlation between mean VA blood flow velocity left-right ratio (MV-ratio) and age.
- Correlation between mean MV-ratio and internal carotid artery stenosis.
- Classification of VA occlusion site by cervical ultrasonography.
- Comparison of VA delineation and occlusion sites by cervical ultrasonography and MRA.
- Cervical ultrasound and MRA findings in patients with altered blood flow in the VA due to cervical rotation.
- MRI and MRA findings in patients with no occlusion of the VA on cervical ultrasonography.

## Results and Discussion

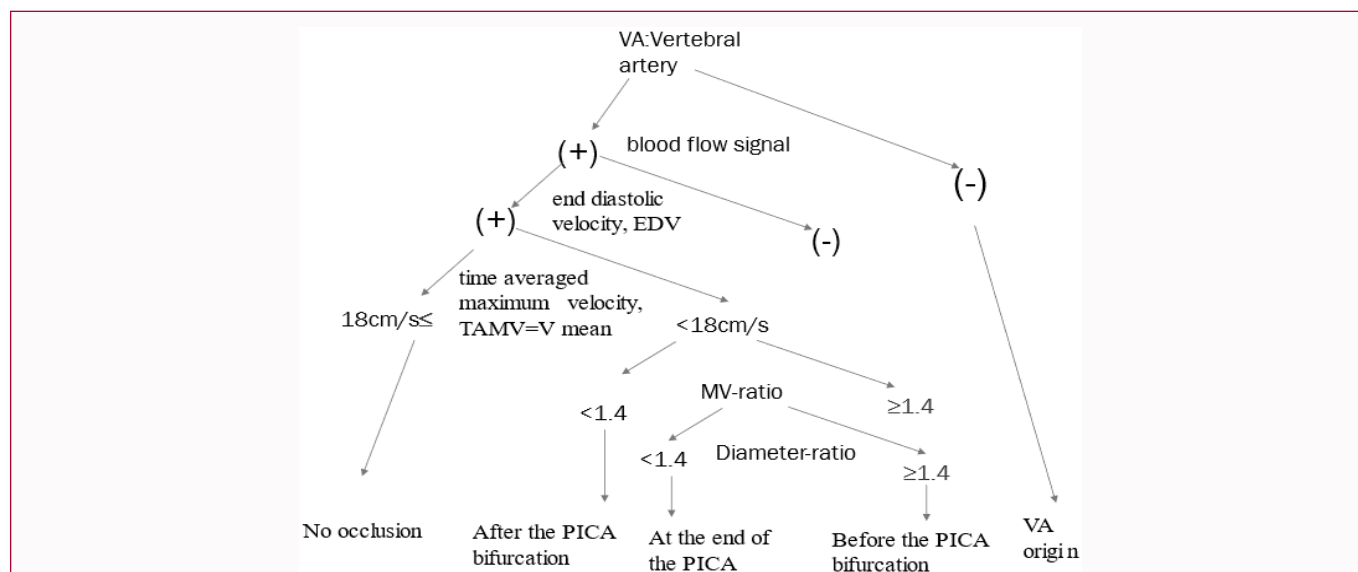
### Results

1. Correlation between V mean of right and left VAs and age.

The correlation between mean blood flow velocity in the right and left vertebral arteries (V mean) added together and divided by two and age was examined (Figure 2). A weak positive correlation was found between the two variables ( $r=0.26$ ,  $p= <0.05$ ).

2. Correlation between mean VA blood flow velocity (MV-ratio) and age.

The correlation between mean difference ratio of left and right blood flow velocities in the VA (MV-ratio) and age was examined (Figure 3). A moderate negative correlation was evident between age

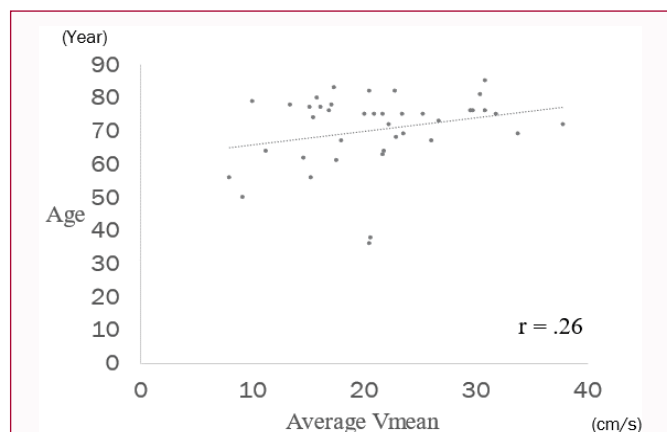


**Figure 1:** Flow chart for diagnosing vertebral artery occlusion site by cervical ultrasonography.

PICA: Posterior Inferior Cerebellar Artery.

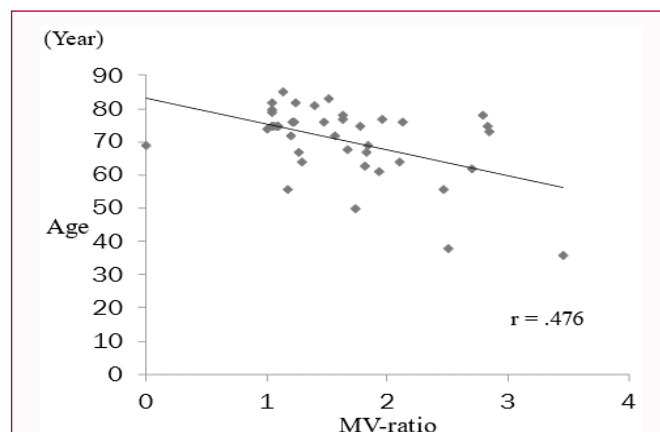
**Mean-ratio:** Mean blood flow velocity of the contralateral vertebral artery/Mean blood flow velocity of the affected vertebral artery.

**Diameter-ratio:** Contralateral vertebral artery diameter/ventral artery diameter on the affected side).



**Figure 2:** Correlation between mean blood flow velocity (V mean) of right and left VAs and age.

Average V mean: The sum of the average blood flow velocities (V mean) of the left and right vertebral arteries and divided by two.



**Figure 3:** Correlation between mean VA blood flow velocity left-right ratio (MV-ratio) and age.

and left-right difference ratio of mean blood flow velocity in the VA ( $r=0.476$ ,  $p<0.05$ ).

3. Correlation between VA mean blood flow velocity left-right ratio (MV-ratio) and carotid artery stenosis.

The correlation between VA mean blood flow velocity left-right ratio (MV-ratio) and carotid artery stenosis was examined (Figure 4). A weak positive correlation was seen between the two variables ( $r=0.289$ ,  $p<0.05$ ).

4. Classification of VA occlusion site by cervical ultrasonography

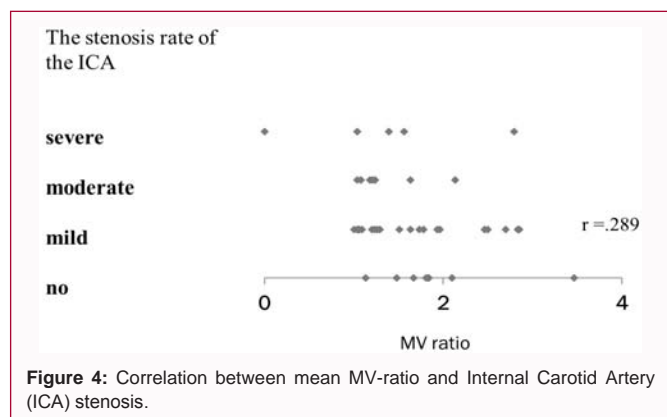
Classifications of the site of VA occlusion by cervical ultrasonography are shown in Table 1. Of the 40 cases, 23 showed VA occlusion. Of those 23 cases with VA occlusion, 4 cases were at the end of the PICA and 18 cases were occluded after the PICA bifurcation. One case of occlusion at the origin of the VA presented with subclavian artery steal syndrome due to typical subclavian artery

occlusion. The remaining 17 cases showed no occlusion of the VA.

5. Comparison of VA delineation and occlusion sites by cervical ultrasonography and MRA

Comparisons of the evaluation of VA blood flow by cervical ultrasonography and MRA are shown in Table 2. In 6 cases, the VA was occluded after the PICA bifurcation on cervical ultrasonography, although the VA was well visualized on MRA. In another 6 cases, the VA was occluded after the bifurcation of the PICA on cervical ultrasonography, although no problem with blood flow in the VA was seen on cervical ultrasonography. The VAs was not occluded on either MRA or neck ultrasonography in 11 cases.

6. Cervical ultrasonography and MRA findings in patients with altered blood flow in the VA due to cervical rotation. Cervical ultrasonography with neck rotation showed blood flow changes in the VA in 8 cases (Table 3). Of these, 3 patients had no problems with VA blood flow during normal supine cervical ultrasonography. In addition, 3 patients displayed no VA problems on MRA, and 2 patients exhibited changes in VA blood flow on cervical rotation



**Figure 4:** Correlation between mean MV-ratio and Internal Carotid Artery (ICA) stenosis.

**Table 1:** Classification of VA occlusion site by cervical ultrasonography.

VA occlusion site	case
PICA end	4
After the PICA bifurcation	18
VA origin	1
No occlusion	17
Total	40

VA: Vertebral Artery; PICA: Posterior Inferior Cerebellar Artery  
 PICA end: Occlusion at the end of the PICA

**Table 2:** Comparison of VA delineation and occlusion sites by cervical ultrasonography and MRA.

	Right VA stenosis	Left VA stenosis	Bilateral VA stenosis	Normal	Total
PICA end	3	1	0	0	4
After the PICA bifurcation	8	4	0	6	18
VA origin	1	1	0	0	1
No occlusion	2	3	1	11	17
Total	13	9	1	17	40

VA: Vertebral Artery; PICA: Posterior Inferior Cerebellar Artery

cervical ultrasonography without showing any abnormalities in the VA on normal cervical ultrasonography or MRA.

7. MRI and MRA findings in patients with no occlusion of the VA on cervical ultrasonography.

We reviewed the MRI and MRA findings of 17 patients who had no VA occlusion on cervical ultrasonography (Table 4). Six patients had ICA lesions (including 4 cases of ICA stenosis and 2 cases of ICA aneurysm formation), 1 case of old cerebellar infarction, 1 case of pontine infarction, 1 case of old pontine hemorrhage, 1 case of VA

neurovascular compression, and 1 case of right VA dissection. MRA showed 3 cases of poor left VA delineation, 2 cases of poor right VA delineation, and 1 case of poor delineation for both VAs.

### Discussion

A large number of patients visit our outpatient department with recurrent dizziness or head-position dizziness. Reaching a diagnosis of the cause of dizziness is often difficult. VBI is also included among those dizziness disorders that are difficult to distinguish. For VBI, although diagnostic criteria exist, in many cases the diagnosis is based on clinical symptoms.

As a diagnostic imaging for VBI, angiography of the vertebrobasilar artery can be invasive and difficult to perform in all suspected VBI cases. Regarding the pathophysiology of VBI, the main causes are: a) Cardiogenic/non-cardiogenic embolism; b) atherosclerosis; c) hemodynamic abnormalities; and d) physical compression. Vertebrobasilar artery dissociation, malformations, convulsions, and atherosclerosis syndrome are also considered [11-14]. Embolism, atherosclerosis and physical compression are frequently detectable on imaging. As a method for investigating hemodynamic abnormalities in the vertebrobasilar artery system, we decided to investigate whether cervical ultrasonography/Doppler examination under load conditions such as cervical rotation is useful.

The purpose of this study was to perform cervical ultrasonic Doppler examination by cervical rotation for patients with recurrent head-position dizziness who are elderly and have diseases such as hypertension, dyslipidemia, and diabetes and are suspected of having VBI. This was to evaluate the hemodynamics of the vertebrobasilar artery system.

Cases of dizziness associated with head position change without cranial nerve symptoms are overwhelmingly examined in the outpatient department of otolaryngology rather than in neurology. For these cases, we considered performing cervical ultrasonography as a screening test in the otolaryngology department, and at the same time, performing MRI/MRA of the head and neck for comparison. This is because the circulatory dynamics of the vertebrobasilar artery can be considered in 3 dimensions by performing imaging tests concurrently. Many studies of VA blood flow changes related to cervical spine rotation have been reported [15-26]. Several Doppler measurements suggest that contralateral VA blood flow is compromised on full rotation in both healthy subjects and patients [18-25]. In addition, a meta-analysis by Mitchell et al. found that VA blood flow velocity was compromised more in patients with VBI than in healthy individuals on contralateral rotation [27]. Mitchell et al. reviewed nine sonographic studies of cervical rotation in the VAs [18-26].

**Table 3:** Cervical ultrasonography and MRA findings in patients with altered blood flow in the VA due to cervical rotation.

Patient No	Changes in blood flow due to cervical rotation ultrasonography	VA stenosis site classification by ultrasonography	MRA findings
1	No right VA depiction	PICA end	Right VA stenosis
2	No right VA depiction	PICA end	Right VA stenosis
3	No both VA depiction	after the PICA bifurcation	Right VA stenosis
4	Left VA blood flow decrease	after the PICA bifurcation	No right VA depiction
5	Right VA blood flow decrease	after the PICA bifurcation	Normal
6	Bilateral VA blood flow decrease	no occlusion	Normal
7	Bilateral VA blood flow decrease	no occlusion	Normal
8	Right VA blood flow decrease	no occlusion	Both VA stenosis

VA: Vertebral Artery; PICA: Posterior Inferior Cerebellar Artery  
 PICA end: Occlusion at the end of the PICA



**Table 4:** MRI and MRA findings in patients with no occlusion of the VA on cervical ultrasonography.

Patient No	MRA findings	MRI findings
1	Left VA stenosis	Old-cerebellar infarction
2	Right VA stenosis	normal
3	Right VA stenosis	No right VA depiction
		Left vascular nerve compression
		Both ICA stenosis
4	Normal	normal
5	normal	normal
6	normal	ICA origin stenosis
7	Both VA stenosis	old pons infarction
8	normal	Left ICA stenosis
9	normal	Both ICA stenosis
10	normal	normal
11	Left VA stenosis	Right VA dissection
12	normal	Old pons bleeding
13	normal	Basilar artery fenestration
14	normal	normal
15	normal	Right ICA stenosis and aneurysm
16	Left VA stenosis	normal
17	normal	Left ICA aneurysm

ICA: Internal Carotid Artery; VA: Vertebral Artery

Most blood flow studies measured changes in blood flow velocity with cervical rotation. Blood flow velocity (measured in centimeters per second) and blood flow rate (measured in cubic centimeters per second, i.e., giving consideration to the cross-sectional area of the vessel in question) are expected to change proportionally [28,29]. Indicators of changes in blood flow velocity with cervical spine motion thus provide good indicators of associated changes in blood flow.

In this study, systolic blood flow velocity in the contralateral VA was measured in the supine position during cervical midline and cervical rotation, and a blood flow velocity decrease >20% was considered to represent a blood flow change associated with a change in head position.

The mean change in blood flow velocity with position in the nine articles reviewed by Mitchell et al. on cervical ultrasound with cervical rotation was approximately 15% [27]. Since this value was obtained from cohorts including normal subjects, a 20% decrease in VA blood flow was adopted as the threshold for onset of VBI in our study. However, this value itself needs to be evaluated in future studies.

Licht et al. performed cervical Doppler ultrasound with neck rotation in 20 healthy adults and reported decreased blood flow velocity in the VA contralateral to the direction of neck rotation but increased blood flow in the ipsilateral VA [25]. In this study, blood flow measurements of the VAs ipsilateral to cervical rotation did not provide data on changes in blood flow in the VAs ipsilateral to cervical rotation because it was difficult to visualize the VAs in obese patients.

On the other hand, Rossiti et al. measured dynamic changes in blood flow velocity in the intracranial VA and BA during head rotation in healthy subjects using pulsed-wave Transcranial Doppler

ultrasonography (TCD) [19]. In another group, both VAs was examined simultaneously with two-channel TCD. Blood flow velocity was decreased in all vessels, regardless of left or right, compared to the neutral position. The results of that study showed that the blood flow velocity in the vertebrobasilar artery system was critically decreased by head rotation in healthy subjects. Rossiti et al. suggested that this physiological phenomenon may affect cerebral blood flow in patients with impaired cerebrovascular autoregulation, low blood flow reserve in contralateral cerebral vessels, or insufficient collateral circulation due to normal anatomical changes, especially in patients under general anesthesia or in a coma [19].

Nemati et al. measured blood flow in VAs by age and found no significant changes in VA diameter, vascular resistance, PSV, or blood flow (FV) with aging [30]. They speculated that these findings may be due to the lower degree of atrophy of the brainstem compared to the cerebral hemispheres in the elderly. This was also consistent with the report by Seidal et al. [31].

In this study, we examined the correlation of mean blood flow velocity in the VA with aging and the correlation between the left-right ratio of mean blood flow velocity in the VA and plaque in the ICA, although we only considered VBI patients. However, we did not find any strong correlations. These results support the findings of Nemati et al. that VA blood flow is largely unaffected by aging.

On the other hand, for anatomical reasons, PSV and FV in the left VA were significantly higher than those in the right VA for younger patients compared with older patients.

In this study, a moderate negative correlation was seen between age and the difference in mean velocity of blood flow in the VA between right and left sides (MV-ratio). This indicates that the left-right difference in VA blood flow decreases with age.

The central vestibular system in the brainstem is more vulnerable to ischemia, and the autoregulatory capacity of the vertebrobasilar artery system is inferior to that of the ICA system, suggesting that even minute decreases in blood flow can cause dizziness [32].

The VAs have an autoregulatory capacity in which the contralateral VA works compensatively to maintain circulation in the vertebrobasilar artery system when blood flow on one side becomes weak. Age-related decreases in left-right difference in VA blood flow may be related to the autoregulatory capacity of the vertebrobasilar artery system. The older a person gets, the weaker the autoregulatory capacity of the vertebrobasilar artery system is considered to become, making the elderly more prone to dizziness. Unlike the ICA, the VA runs in the transverse process of the cervical spine and flows into the cranium, and so can be compressed or placed under tension by neck rotation or flexion, resulting in arterial dissection or reduced or blocked blood flow.

In this study, we classified the site of VA occlusion by cervical ultrasonography, referring to the report by Saito et al. [9] (Figure 1). Saito et al. stated that even when VA occlusion is suspected, post-PICA occlusion may be due to hypoplasia or previous asymptomatic occlusion (PICA-end), and distinguishing whether the VA is symptomatically occluded is also important.

In bow hunter's syndrome, when blood flow in the contralateral VA is transiently reduced by compression of the contralateral VA due to rotation, especially when the unilateral VA terminates at the PICA due to hypoplasia or occlusion, a sudden decrease in blood flow to the

brainstem and cerebellum may cause symptoms such as dizziness and loss of consciousness [30].

In this study, 23 of 40 patients had VA occlusion on cervical ultrasonography. Eighteen patients experienced occlusion after the bifurcation of the PICA, and 4 patients showed occlusion at the end of the PICA, indicating that the majority of patients had VA occlusion after the PICA. We therefore hypothesized that VA occlusions in these patients may cause dizziness symptoms during cervical rotation, similar to bow hunter's syndrome. In this study, 6 cases showed VA occlusion after the PICA bifurcation on cervical ultrasonography, despite MRA having no problem depicting the VA. In another 6 cases, cervical ultrasonography did not show any problems with VA blood flow where MRA detected VA lesions.

In addition, MRI was able to detect 6 cases of ICA lesions, 1 case of a BA lesion, 3 cases of old infarction or hemorrhage in the brainstem, and 1 case of VA neurovascular compression syndrome among the 15 patients with no VA blood flow problems on cervical ultrasound. MRI can detect anatomical abnormalities and foci in the brain, while MRA is suitable for looking at the overall vascular status, including both intra- and extra-cranially. Cervical ultrasonography is suitable for assessing the state of blood flow in the VAs at any given moment. By combining these examinations, we believe that it is possible to construct a 3D picture of the circulatory status of the vertebrobasilar arteries.

Cervical ultrasonography can facilitate diagnosis by recording the VA waveform with the neck in the midline position, reproducing the position of the neck where symptoms appear, and observing how VA blood flow changes during that time. This is very useful in cases of transient occlusion, because occlusion patterns change after and before the PICA [33].

In this study, we found that 8 of 40 cases had hidden bow hunter's syndrome, in which blood flow in the VA is altered by performing neck ultrasound while the neck is rotated. These cases included 3 cases each in which MRA or conventional ultrasonography of the neck in the midline position did not show any problems with VA blood flow. Real-time assessment of the VAs would have been difficult without ultrasound, and it would have been possible to avoid symptoms by examining the degree of body position at which the effect on blood flow to the VAs appeared.

The present study did not attempt to describe the circulatory dynamics of the VAs by cervical ultrasonography alone, as this has been reported in other studies [15,29,34].

The combination of MRI, MRA, and other tests to detect organic abnormalities and neck ultrasonography performed with the neck in a rotated position provided a more concrete image of the circulatory state of the VAs. Cervical ultrasonography is very useful in estimating intracranial vascular occlusion by allowing easy examination of the neck vessels at the bedside. Recent advances in ultrasound function and imaging have made it possible to evaluate blood flow in the VAs in great detail. Cervical ultrasonography is simple, non-invasive, and provides a great deal of information because it can assess anatomy and blood flow in real time. Serial cervical ultrasonography may also be useful in determining the efficacy of treatment.

Cervical ultrasound is available at most general hospitals. We hope that cervical ultrasonography will become more widely recognized

as a common method for diagnosing VBI in Otorhinolaryngology Departments, as the departments most frequently seeing vertigo patients.

## Conclusion

In this paper, we used cervical ultrasonography to confirm the blood flow status of the VA in the mid-neck and cervical rotation positions in 40 patients with suspected VBI. We also examined the circulatory status of the vertebrobasilar artery by combining head and neck MRI and MRA findings. Cervical ultrasonography under cervical rotation was able to detect hidden circulatory and dynamic VBI that could not be detected by conventional cervical ultrasonography in the mid-neck position, head and neck MRI, or MRA. The combination of these examinations would facilitate a deeper understanding of the circulatory status of the complex vertebrobasilar artery system.

## References

- Baloh RW. Vertebrobasilar insufficiency and stroke. *Otolaryngol Head Neck Surg.* 1995;112(1):114-7.
- Komatsuzaki A, Hutatsuki T, Harada Y, Bokuzawa J, Ishii T, Kamei T, et al. Vertebro-basilar insufficiency. *Equilibrium Res Suppl.* 1995;11:51-2.
- WHO MONICA Project Principal Investigators. The World Health Organization MONICA Project (monitoring trends and determinants in cardiovascular disease): A major international collaboration. *J Clin Epidemiol.* 1988;41(2):105-14.
- Yamanaka T. Vertebrobasilar insufficiency. *Equilibrium Res.* 2014;73(3):117-26.
- Sorensen BF. Bow hunter's stroke. *Neurosurgery.* 1978;2(3):259-61.
- Powers SR Jr, Drislane TM, Nevins S. Intermittent vertebral artery compression; a new syndrome. *Surgery.* 1961;49:257-64.
- Grad A, Baloh RW. Vertigo of vascular origin: Clinical and electronystagmographic features in 84 cases. *Arch Neurol.* 1989;46(3):281-4.
- Gomez CR, Cruz-Flores S, Malkoff MD, Sauer CM, Burch CM. Isolated vertigo as a manifestation of vertebrobasilar ischemia. *Neurology.* 1996;47(1):94-7.
- Saito K, Ueno S. Duplex color-coded ultrasonography for evaluation of the vertebrobasilar arteries. *Equilibrium Res.* 2009;68(4):184-92.
- Stein JH, Korcarz CE, Hurst RT, Lonn E, Kendall CB, Mohler ER, et al. Use of carotid ultrasound to identify subclinical vascular disease and evaluate cardiovascular disease risk: A consensus statement from the American Society of Echocardiography Carotid Intima-Media Thickness Task Force. Endorsed by the Society for Vascular Medicine. *J Am Soc Echocardiogr.* 2008;21(2):93-111.
- Millikan CH, Siekert RG. Studies in cerebrovascular disease. I. The syndrome of intermittent insufficiency of the basilar arterial system. *Proc Staff Meet Mayo Clin.* 1955;30(9):61-8.
- Bradshaw P, McQuaid P. The syndrome of vertebra-basilar insufficiency. *J Med.* 1963;32(3):279-6.
- Meyer JS, Wegner W, Kane CA, Reinmuth OM. Electro-encephalographic evaluation of treatment on obstructive disease of the basilar and carotid arteries. *Neurol.* 1957;7(11):765-76.
- Yamanaka T, Sawai Y, Hosoi H. Bilateral sub-clavian steal syndrome with vertigo. *Auris Nasus Larynx.* 2014;41(3):307-09.
- Licht PB, Christensen HW, Hoilund-Carlsen PF. Vertebral artery volume flow in human beings. *J Manipulative Physiol Ther.* 1999;22(6):363-7.
- Weingart JR, Bischoff HP. Doppler-sonographische Untersuchung der A. Vertebralis unter Berücksichtigung chirotherapeutisch relevanter

- Kopfpositionen. *J Man Med.* 1992;30:62-5.
17. Refshauge KM. Rotation: A valid pre-manipulative dizziness test? Does it predict safe manipulation? *J Manipulative Physiol Ther.* 1994;17(1):15-9.
  18. Stevens A. Functional Doppler sonography of the vertebral artery and some considerations about manual techniques. *J Man Med.* 1991;6:102-5.
  19. Rossiti S, Volkmann R, Lofgren J. Changes of blood flow velocity in the vertebro-basilar circulation during rotation of the head in the normal human. *Biomech Sem.* 1992;6:92-99.
  20. Licht PB, Christensen HW, Hojgaard P, Hoilund-Carlsen PF. Triplex ultrasound of vertebral artery flow during cervical rotation. *J Manipulative Physiol Ther.* 1998;21(1):27-31.
  21. Rivett DA, Sharples KJ, Milburn PD. Effect of pre-manipulative tests on vertebral artery and internal carotid artery blood flow: A pilot study. *J Manipulative Physiol Ther.* 1999;22(6):368-75.
  22. Mitchell J. Changes in vertebral artery blood flow following rotation of the cervical spine. *J Manipulative Physiol Ther.* 2003;26(6):347-51.
  23. Rivett DA, Sharples KJ, Milburn PD. Reliability of ultrasonographic measurement of vertebral artery blood flow. *NZ J Physiother.* 2003;31:119-28.
  24. Arnold C, Bourassa T, Langer T, Stoneham G. Doppler studies evaluating the effect of a physical therapy screening protocol on vertebral artery blood flow. *Man Ther.* 2004;9(1):13-21.
  25. Mitchell J, Keene D, Dyson C, Harvey L, Pruevey C, Phillips R. Is cervical spine rotation, as used in the standard vertebrobasilar insufficiency test, associated with a measurable change in intracranial vertebral artery blood flow? *Man Ther.* 2004;9(4):220-27.
  26. Mitchell J, Kramschuster K. Real-time ultrasound measurements of changes in suboccipital vertebral artery diameter and blood flow velocity associated with cervical spine rotation. *Physiother Res Internat.* 2009;13:241-54.
  27. Mitchell J. Vertebral artery blood flow velocity changes associated with cervical spine rotation: A meta-analysis of the evidence with implications for professional practice. *J Man Manip Ther.* 2009;17(1):46-57.
  28. Aaslid R. *Transcranial Doppler sonography.* Vienna, Austria: Springer-Verlag; 1986.
  29. Newell DW, Aaslid R. *Transcranial Doppler.* New York: Raven Press; 1992.
  30. Nemati M, Babil AS, Taheri N. Comparison of normal values of Duplex indices of vertebral arteries in young and elderly adults. *Cardiovasc Ultrasound.* 2009;7:2.
  31. Seidel E, Eicke BM, Tettenborn B, Krummenauer F. Reference values for vertebral artery flow volume by duplex sonography in young and elderly adults. *Stroke.* 1999;30(12):2692-6.
  32. Yamanaka T, Yamamoto T, Miyahara H, Matsunaga T. Vestibular neural function of cats following unilateral vertebral artery occlusion. *Acta Otolaryngol.* 1998;533:26-9.
  33. Sakaguchi M, Kitagawa K, Hougaku H, Hashimoto H, Nagai Y, Yamagami H, et al. Mechanical compression of the extracranial vertebral artery during neck rotation. *Neurology.* 2003;61(6):845-7.
  34. Ozdemir H, Cihangiroglu M, Berilgen S, Bulut S. Effects of cervical rotation on hemodynamics in vertebral arteries. *J Diagnostic Med Sonography.* 2005;21:384-91.