



Unusual Presentation of Chest Pain

Myola Ignotas A and Pranas Serpytis*

Department of Emergency Medicine, Vilnius University, Lithuania

Abstract

Rupture of pulmonary abscess and subsequent pleural empyema with pneumothorax is unusual acute chest pain cause. Brief history, physical examination, simple chest X-ray makes rupture of pulmonary abscess to pleural cavity quickly recognizable. Patient vital signs can deteriorate rapidly, thus depending on findings chest tube placement is crucial and can be lifesaving. In this report we present clinical case of 56 male who presents to rural Emergency Department (ED) complaining worsening dyspnea and sharp severe pain in right chest side, one month ago he was treated in the hospital for Community Acquired Pneumonia.

Introduction

Chest pain is the second most common complaint in ED. Diseases of the heart, aorta, lungs, esophagus, stomach, mediastinum, pleura, and abdominal viscera may all cause chest discomfort. Patients with life-threatening etiologies for chest pain may appear from deceptively well to severe cardiopulmonary failure, thus ED physicians must focus on the immediate recognition and exclusion of life-threatening causes of chest pain. The authors report an unusual case of acute chest pain due to sudden rupture of pulmonary abscess with subsequent acute cardiopulmonary failure.

Case Presentation

A 56 years male presents to rural ED complaining worsening dyspnea and sharp severe pain in right chest side. These symptoms developed two hours ago after vigorous coughing. One month before he was admitted to hospital where he was treated of right side pneumonia. Upon discharge from hospital rare cough remained. From medical history he has chronic AF, takes warfarin, has implanted pacemaker.

Upon presentation, the patient's vital signs were: heart rate, 72 beats/min; respiratory rate, 30 breaths/min; blood pressure, 84 mmHg/55 mmHg. Oxygen saturation was 92% on 5 l/min oxygen. Physical examination revealed absent sounds in right lung and distended neck veins. Complete blood count revealed leukocytosis, CRP was 359 mg/L. X-ray of chest was performed with signs of right pleural effusion up to 7 costal level and pneumothorax (Figure 1).

The emergent tube thoracotomy was performed on the right chest side due to worsening vital signs liter of pus drained for chest tube [1] (Figure 2). Vital signs improved and the patient was admitted to Intensive Care Unit (ICU). After 6 six days of treatment with broad spectrum of antibiotics, patient was transferred to tertiary level hospital for definite surgical treatment. Surgical lung decortication was performed with subsequent antibacterial therapy. He was eventually discharged after 13 days of treatment.

OPEN ACCESS

*Correspondence:

Pranas Serpytis, Department of
Emergency Medicine, Varena Hospital,
Vilnius University, Lithuania,
E-mail: pranas.serpytis@santa.lt

Received Date: 20 Jun 2019

Accepted Date: 16 Jul 2019

Published Date: 23 Jul 2019

Citation:

Myola Ignotas A, Serpytis P. Unusual
Presentation of Chest Pain. *Int J Intern
Emerg Med.* 2019; 2(2): 1021.

Copyright © 2019 Pranas Serpytis.

This is an open access article
distributed under the Creative
Commons Attribution License, which
permits unrestricted use, distribution,
and reproduction in any medium,
provided the original work is properly
cited.



Figure 1: Pleural effusion in right lung.

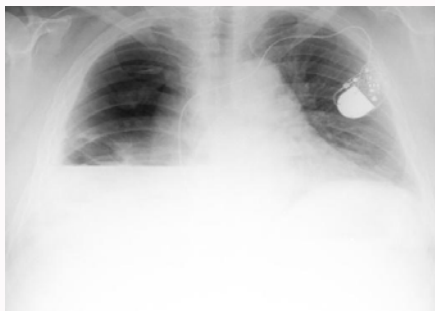


Figure 2: Pus drained from chest tube.

Discussion

Lung abscess is defined as a localized necrosis of the lung parenchyma, typically caused by suppurative microbial infection. This initial infections usually caused by aspiration of oral contents. Lung abscess may also develop as a result of hematogenous spread of infectious material to the lung parenchyma or lung infarct. Primary lung abscess occurs in individuals in good health or in those prone to aspiration. Approximately 80% of lung abscesses are primary. Secondary lung abscess is associated with malignancy, immunosuppressant, extra pulmonary infection or sepsis, or complication of surgery; the mortality is higher than seen in primary lung abscess, often over 50%. Lung abscesses present for less than 1 month are acute, with the rest being considered chronic [2].

Recommended therapy includes piperacillin-tazobactam 3.375 gm to 4.5 gm every 6 h IV or imipenem 0.5 gm to 1.0 gm IV every 6 h. Add vancomycin for methicillin-resistant *Staphylococcus aureus* in those at risk. Those at risk for methicillin-resistant *S. aureus* include patients recently hospitalized, patients who have an

invasive medical device, and patients residing in a long-term care facility. Complications of lung abscess include empyema, massive hemoptysis, contamination of the uninvolved lung, and failure of the abscess cavity to resolve. Approximately 10% of bacterial lung abscesses require surgical intervention. In this case patient developed pulmonary abscess after pneumonia treated one month ago in hospital [3].

BTS Community Acquired Pneumonia (CAP) guidelines require a Chest Radiograph (CXR) 6 weeks after discharge in high risk patients. In this case abscess rupture occurred 4 weeks after the patient was discharged from hospital [4].

Conclusion

In conclusion rupture of pulmonary abscess is unusual cause of acute chest pain. Brief history, physical examination, simple chest X-ray makes rupture of pulmonary abscess quickly recognizable. Patient vital signs can deteriorate rapidly, thus depending on findings chest tube placement is crucial and can be lifesaving.

References

1. Nucera G, Cantoni G, Pietro M. An unusual case of chest pain. *J Heal and Soc Sci.* 2016;1(2):123-8.
2. Tintinalli JE, Stephan Stapczynski J, John Ma O, Cline D, Rita KC, Meckler GD. *Tintinalli's Emergency Medicine: A Comprehensive Study Guide, 7e.* The American College of Emergency Physicians.
3. Merritt RE, Shrager JB. Indications for surgery in patients with localized pulmonary infection. *Thorac Surg Clin.* 2012;22(3):325-32.
4. Lim WS, Baudouin SV, George RC, Hill AT, Jamieson C, Le Jeune I, et al. BTS guidelines for the management of community acquired pneumonia in adults: update 2009. *Thorax.* 2009;64(3):1-55.