



## Triple Ectopic Thyroid Excision by Robotic Surgery via Trans-Oral and Post-Auricular Approach Report of a Case

Man-Wei Hua<sup>1</sup>, Wen-Chun Lin<sup>1</sup> and Chen-Chi Wang<sup>1,2,3,4\*</sup>

<sup>1</sup>Department of Otolaryngology, Head and Neck Surgery, Taichung Veterans General Hospital, Taiwan

<sup>2</sup>School of Medicine, National Yang-Ming University, Taiwan

<sup>3</sup>School of Speech Language Pathology and Audiology, Chung Shan Medical University, Taiwan

<sup>4</sup>Department of Audiology and Speech-Language Pathology, Asia University, Taiwan

### Abstract

**Background:** Ectopic thyroid refers to the presence of thyroid tissue in locations other than the normal anterior lower neck region. Lingual thyroid is the most common type accounting for 90% of cases. The other locations at head and neck region or other places distant from neck have also been documented. However, multiple ectopic thyroids are extremely rare. In asymptomatic cases, observation is preferred. Further intervention would be recommended in those having obstructive symptoms, hormone dysfunction or suspicion of malignancy.

**Case Summary:** In this paper, we would like to report a patient with long history of triple ectopic thyroids at tongue base and neck region over submental and hyoid bone level. She denied surgery before for fear of possible cosmetic deformity and tracheostomy by devastating conventional open surgery. However, the ectopic thyroids enlarged recently and caused her dysphagia with severe foreign body sensation. Malignant transformation should be ruled out too with this scenario. In recent years, da-Vinci robot has been used for minimal invasive trans-oral excision of upper aerodigestive tumors without tracheostomy. It also has been used in post-aural approach for removing cervical tumors with better cosmetic outcome by hidden scar. We performed both aforementioned robotic surgeries for her and successfully removed three tumors without tracheostomy or major complications. She is satisfied with the functional and cosmetic results after 2 year follow up.

**Conclusion:** Multiple ectopic thyroids over tongue base and neck region could be removed by robotic surgery with less invasiveness and better cosmetic results.

**Keywords:** Case report; Da-Vinci robot; Ectopic thyroid; Robotic surgery; Trans-oral

### Introduction

Ectopic thyroid gland is an uncommon embryological aberration resulting from the arrest of migration from foramen cecum to the typical pretracheal position. Arrest during the pathway resulted in ectopic thyroid. The prevalence of ectopic gland is about 1 case per 100,000 to 300,000 persons [1]. Dual, triple and multiple ectopic thyroids is even rare, with only a few small case series and case reports [2-5]. In asymptomatic cases, observation with close follow-up is recommended. For those have hormone dysfunction, suspicion of malignancy, and obstructive symptoms such as dysphagia, dyspnea, and obstructive sleep apnea, hormone suppression therapy or surgical removal should be considered [6]. In the past, surgical approach to lingual thyroid, especially bigger tumor, might require mandibulotomy and even tracheostomy [6-8], which caused significant morbidity and obvious scar on the neck. As the development of da-Vinci robot, the application of trans-oral robotic surgery to tongue base lesion could minimize the surgical risks and give optimal surgical result [9,10]. Furthermore, robotic surgery with post auricular approach for tumors located at neck region also provides patients with hidden scar and therefore better cosmetic outcomes. We hereby present a case with symptomatic triple ectopic thyroids which were successfully removed by using robotic surgery combining both transoral and post auricular approach.

### Case Presentation

This case report was approved by the Institutional Review Board of TCVGH (IRB No.CE19155A). A 56-year-old woman presented with firm midline neck mass for more than 5 years. Thyroid scan with 30 mCi-131 was ever performed at other hospital, and it revealed three ectopic thyroid tissue

### OPEN ACCESS

#### \*Correspondence:

Chen-Chi Wang, Department of Otolaryngology, Head and Neck Surgery, Taichung Veterans General Hospital, 1650, Sec. 4, Taiwan Boulevard, Taichung 40705, Taiwan, Tel: 886423592525;

E-mail: entccwang@msn.com

Received Date: 31 May 2019

Accepted Date: 18 Jun 2019

Published Date: 24 Jun 2019

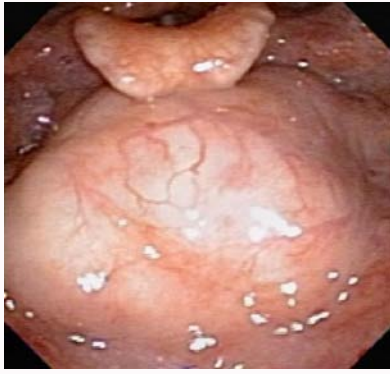#### Citation:

Hua M-W, Lin W-C, Wang C-C. Triple Ectopic Thyroid Excision by Robotic Surgery via Trans-Oral and Post-Auricular Approach Report of a Case. *Ann Clin Case Rep.* 2019; 4: 1680.

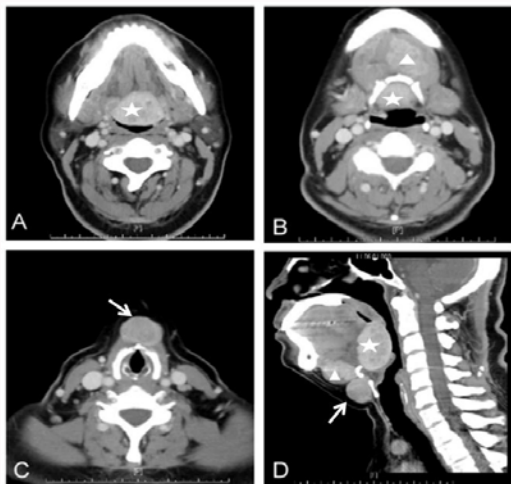
ISSN: 2474-1655

Copyright © 2019 Chen-Chi Wang.

This is an open access article distributed under the Creative Commons Attribution License, which permits unrestricted use, distribution, and reproduction in any medium, provided the original work is properly cited.

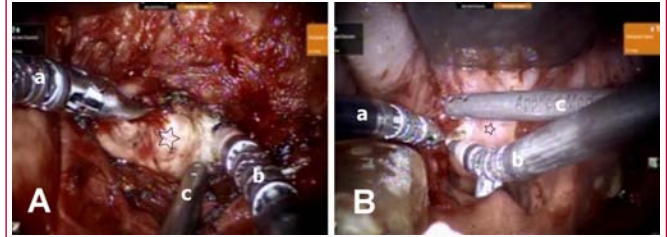


**Figure 1:** Flexible laryngoscopic view of the huge tongue base ectopic thyroid.

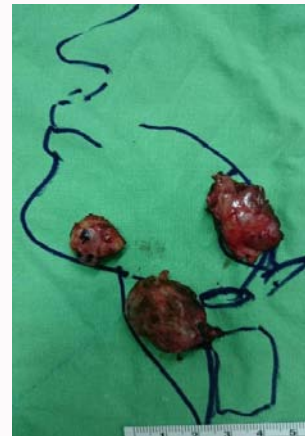

**Figure 2:** Computed tomography image of the triple ectopic thyroid including tongue base lesion (star), submental lesion (triangle) and anterior cervical lesion in front of thyroid cartilage (arrow).

uptakes over the tongue base, the submental area and subcutaneous space of the midline of neck at the level of thyroid cartilage. She also had subclinical hypothyroidism and was advised to take hormone supplement with thyroxine. She did not receive surgery before for fear of possible cosmetic deformity and tracheostomy by devastating conventional open surgery suggested at other hospital. She came to our clinic due to progressive enlargement of the anterior neck masses, and tongue base lesion which caused her dysphagia with severe foreign body sensation of throat. She also worried about the possible malignant change of the lesions at present or in the future. By physical examination, 2 elastic and movable mass lesions about 2 cm in diameter were found over the neck. Flexible laryngoscopy also showed a mass lesion about 3 cm in diameter at tongue base (Figure 1). Fine Needle Aspiration (FNA) of one of the anterior neck masses suggested the lesion was a benign follicular nodule of thyroid gland. Preoperative CT scan demonstrated three contrast enhanced lesions over tongue base, left submental area, and midline of neck at the level of thyroid cartilage. The feature of CT images was consistent with the diagnosis of triple ectopic thyroids (Figure 2). After explaining another robotic surgery options in addition to conventional open surgery, the patient decided to undergo robotic surgery for removal of ectopic thyroid glands without tracheostomy and other invasive open surgical management.



**Figure 3:** Operative view of robot assisted excision for ectopic thyroid lesions. A) Cervical lesions (star) was removed via right postauricular approach with Maryland dissector (a), spatula tip electro-cautery (b) and suction tube (c) controlled by bedside assistant. B) Tongue base lesion was also removed via trans-oral approach with Maryland dissector (a), spatula tip electro-cautery (b) and suction tube (c) controlled by bedside assistant.

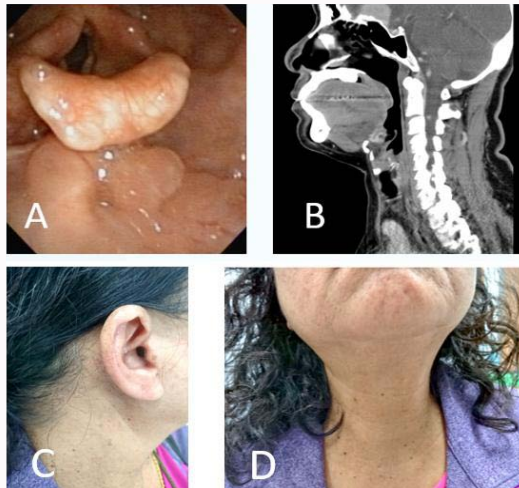


**Figure 4:** Surgical specimens of the triple ectopic thyroid lesions locating at tongue base, submental region and anterior neck region.

**Surgical technique**

Under general anesthesia with Nasoendotracheal intubation, the operative field including oral cavity and cervical skin was sterilized with aqua betadine. The operation was started from neck surgery by right post-auricular approach *via* an inverted “V” incision along the scalp-auricular fold and hair line. A surgical tunnel was made under the subplatysmal skin flap to reach the ectopic thyroids located at left submental and anterior neck region. The MODENA retractor (CEATEC® Medizintechnik GmbH, Wurmlingen, Germany) was applied to maintain the working space in the tunnel. The da Vinci Si surgical system (Intuitive Surgical, Sunnyvale, CA) was positioned at patients left axilla area with a 30 degree angle relative to the surgical bed and the robot’s axis aiming at right postauricular wound. The robotic endoscope was inserted into the wound at the center with Maryland dissector at left hand side and spatula tip electro-cautery at right hand side. The left submental and the anterior neck mass were meticulously dissected from the surrounding tissue with interchanged 0-degree, 30-degree up or 30-degree down endoscopic view. Two masses were removed smoothly along the tumor capsule without causing much bleeding (Figure 3 and 4). A closed system drainage tube was inserted *via* the right post auricular wound and the wound was closed meticulously by layers.

Then another Laryngeal Advanced Retractor System (LARS; Fentex, Tuttlingen, Germany) was applied for the exposure of the lingual thyroid located at tongue base. The axis of da Vinci robot was rotated 90 degree and the 30-degree face up endoscope with aforementioned 2 instruments were inserted into patient’s mouth.



**Figure 5:** Post operative follow up examinations. A) Post-operative flexible laryngoscopic view showed normal tongue base with lingual tonsils. Sagittal CT scan showed no tumor recurrence at 2-year follow up, C) The hidden post aural scar is almost invisible from lateral view of the face. D) There is no visible scar on the anterior neck after robotic esthetic neck surgery without tracheostomy.

The resection was carried out from the anterior border of the lingual thyroid along the capsule of ectopic thyroid tissue without causing much bleeding (Figure 3 and 4).

#### Postoperative care and follow up

The patient tolerated the whole procedure well without intra-operative or postoperative complications except wound pain. The patient could resume soft diet soon after extubation of Nasoendotracheal tube. The pathology report of all 3 lesions showed only goiter without malignancy. After 2-year follow up, there is no tumor recurrence and she is satisfied with the functional and cosmetic results without significant cervical scars (Figure 5).

#### Discussion

Ectopic thyroid is an embryological abnormality of the aberrance or failure during the thyroid gland migration from foramen cecum to the typical pretracheal position since gestational age 4<sup>th</sup> week. The most common localization was lingual region and the other localizations of ectopic thyroid include sublingual, higher or lower cervical, the mediastinum, and even the below the diaphragm [1,6]. Although ectopic thyroid is usually benign, but ectopic thyroid cancer had been documented in literature [11], and surgery is mandatory if malignancy is concerned. Multiple ectopia of thyroid is extremely rare. Around 34 cases of dual ectopic thyroid and 3 cases of triple lesions has been reported in literature [2-5,12]. None of the three patients with triple ectopic thyroid gland received surgical intervention (Two had observation only, and one received hormone suppression therapy due to anterior neck swelling). Our case is the first triple ectopic thyroid managed successfully by robotic surgery, with less invasive approach and better functional and cosmetic results.

There were several ways to approach lingual thyroid, including transoral route, transhyoid, suprahyoid, or lateral pharyngotomy from the neck [7]. For smaller lingual thyroid lesions, transoral excision with conventional instrument could probably be done. However, conventional transoral approach has the disadvantages of limited exposure and difficulty in manipulation and hemostasis. Bigger lesions such as the one presented in our paper might require midline

mandibulotomy or tongue splitting technique, which result in more tissue trauma and ugly scar on the neck and temporary tracheostomy is usually necessary. In 1999, da-Vinci robot was developed by intuitive company in USA. It contains high magnification 3-D endoscope, endo-wristed instruments with motion scaling and tremor filtration function that help surgeons to perform endoscopic surgery with more precision, dexterity and control. In recent years, it has been used for minimal invasive trans-oral excision of upper aero-digestive tumors without tracheostomy. There has been a few articles reporting TORS as an effective and safe way to remove lingual thyroid [9,13]. In addition, the robotic surgery also has been adopted to do esthetic neck surgery with better cosmetic outcomes by hiding the scar [14]. Our case indicated that robotic surgery combining transoral and postauricular approach is a better surgical option for multiple ectopic thyroids located at the tongue base and cervical regions. The minimal invasiveness feature of this management will not hinder patients from early surgical removal, the life quality of the patient could be improved with lowering risk of malignant change in the future.

#### Conclusion

The triple ectopic thyroid is an extremely rare case. By using state-of-the-art da-Vinci robot surgical techniques including TORS and esthetic neck surgery *via* post auricular approach. Ectopic thyroid or even multiple lesions in aero-digestive tract and neck could be successfully treated without major complications.

#### References

- Santangelo G, Pellino G, De Falco N, Colella G, D'Amato S, Maglione MG, et al. Prevalence, diagnosis and management of ectopic thyroid glands. *Int J Surg*. 2016;28(Suppl 1):S1-6.
- Chawla M, Kumar R, Malhotra A. Dual ectopic thyroid: case series and review of the literature. *Clin Nucl Med*. 2007;32(1):1-5.
- Hussain SZ, Ayub MF. A case of dual ectopic thyroid. 2017;4(8):2862-4.
- Kuramoto R, Oikawa K, Fujita K, Oridate N, Fukuda S. Triple ectopic thyroid: a case report and review of literature. *Thyroid Disorders & Ther*. 2013;2(2):1-3.
- Rahalkar M, A Rahalkar, S Solav. A rare case of triple thyroid ectopia. *Indian J Endocrinol Metab*. 2014;18(2):238-40.
- Guerra G, Cinelli M, Mesolella M, Tafuri D, Rocca A, Amato B, et al. Morphological, diagnostic and surgical features of ectopic thyroid gland: a review of literature. *Int J Surg*. 2014;12(Suppl 1):S3-11.
- Noussios G, Anagnostis P, Goulis DG, Lappas D, Natsis K. Ectopic thyroid tissue: anatomical, clinical, and surgical implications of a rare entity. *Eur J Endocrinol*. 2011;165(3):375-82.
- Kumar LK, Kurien NM, Jacob MM, Menon PV, Khalam SA. Lingual thyroid. *Ann Maxillofac Surg*. 2015;5(1): 104-7.
- May JT 4<sup>th</sup>, Newman JG, Padhya TA. Transoral robot-assisted excision of a lingual thyroid gland. *J Robot Surg*. 2011;5(3):217-20.
- Mercante G, Ruscito P, Pellini R, Cristalli G, Spriano G. Transoral robotic surgery (TORS) for tongue base tumours. *Acta Otorhinolaryngol Ital*. 2013;33(4):230-5.
- Klubo-Gwiedzinska J, Manes RP, Chia SH, Burman KD, Stathatos NA, Deeb ZE, et al. Clinical review: ectopic cervical thyroid carcinoma-review of the literature with illustrative case series. *J Clin Endocrinol Metab*. 2011;96(9):2684-91.
- Konde SR, Singh H, Pawar A, Sasane A. Triple ectopic thyroid. *Med J Armed Forces India*. 2012;68(2):173-5.

13. Prisman E, Patsias A, Genden EM. Transoral robotic excision of ectopic lingual thyroid: case series and literature review. *Head Neck*. 2015;37(8):E88-91.
14. Ji YB, Song CM, Bang HS, Park HJ, Lee JY, Tae K. Functional and cosmetic outcomes of robot-assisted neck dissection by a postauricular facelift approach for head and neck cancer. *Oral Oncol*. 2017;70:51-7.