Annals of Clinical Otolaryngology

Opinion
Published: 05 Mar, 2022

Tongue Base Reduction Surgery in Snoring and Obstructive Sleep Apnea: Is it Difficult Decision?

*Ahmed Mohamed Mohy Eldin Elbassiouny**

Department of Otolaryngology, Cairo University, Egypt

Abstract

Objective: To highlight the importance of hypopharyngeal obstruction in the treatment of Obstructive Sleep Apnea (OSA) and to delineate the role of tongue base in upper airway, the possible ways for tongue base enlargement evaluation that may contributes to patient's selection and the concepts behind optimal patient selection for hypopharyngeal OSA surgery with the objective of ensuring best patient outcomes.

Conclusion: Decision for tongue base reduction surgery in patients with obstructive sleep apnea should be carefully considering the possible surgical complications, unfavorable surgical outcomes that may force the patients to have further surgical intervention.

Keywords: Tongue base reduction; Obstructive sleep apnea; Surgery

Introduction

Going through the progression of Obstructive Sleep Apnea (OSA) surgery, tongue base surgery has always been a site of challenge and debate, retropalatal collapse has been addressed to be more common than the retrolingual obstruction in spite that the latter is often relevant [1,2]. In the context of sleep surgery, hypopharyngeal collapse is broadly accepted as an area encompassing tongue base, lingual tonsil, epiglottis, and aryepiglottic fold and hypopharyngeal wall [3]. According to a large study conducted by Vroegop et al. [4], hypopharyngeal obstruction is common in OSA patients, with tongue base obstruction in 46.6%, conventional tongue base surgical procedures, as for example with midline glossectomy, are usually aggressive and associated with considerable incidence of both immediate and long-term complications [5-9]. Different surgical techniques have been developed aiming to minimize postoperative morbidity and complications simultaneously with maximizing the amount of tongue tissue resected [10].

Hypopharyngeal obstruction is associated with obesity and increased percentage of tongue base fat. Tongue volume, and specifically tongue base, obviously will increase with fat deposition, thereby contributes to variable degrees of upper air way obstruction [11].

Tongue base collapse can be visualized accurately with DISE which can occurs separately or in combination with epiglottic collapse, "trap door" phenomenon that will add more to the upper way obstruction [12].

Over the past few decades, procedures have been developed to treat hypopharyngeal obstruction in adults with OSA [13]. Surgical decision making should consider not only the patient's history, physical examination, and other evaluations related to the pattern of obstruction but also surgeon training, surgeon personal experience, and patient preferences [14,15].

Following tongue base surgery, immediate and late complications may be encountered. Immediate postoperative upper airway edema, infection, bleeding, lingual paralysis, taste dysfunctions and persistent odynophagia may be recorded. Loss of appetite with possible loss of weight can be one of the drawbacks of taste dysfunctions [16].

In this article, we will try to have the chance to introduce a tongue base surgery algorism to achieve the best treatment outcomes.

Discussion

The presence of different techniques and modalities of OSA treatment reflect that the conditions have a multifactorial and multilevel issue. However, as the effectiveness of surgery is not granted in this area of the airway surgeons must have a precise preoperative assessment with balancing the

OPEN ACCESS

Correspondence:
Ahmed Mohamed Mohy Eldin Elbassiouny, Department of Otolaryngology, Cairo University, Egypt, Tel: 00201116072205; E-mail: ahmedeldeen662000@yahoo.com

Received Date: *07 Feb 2022*
Accepted Date*: 21 Feb 2022*
Published Date*: 05 Mar 2022*

Citation:
Elbassiouny AMME. Tongue Base Reduction Surgery in Snoring and Obstructive Sleep Apnea: Is it Difficult Decision?. Ann Clin Otolaryngol. 2022; 7(1): 1055.

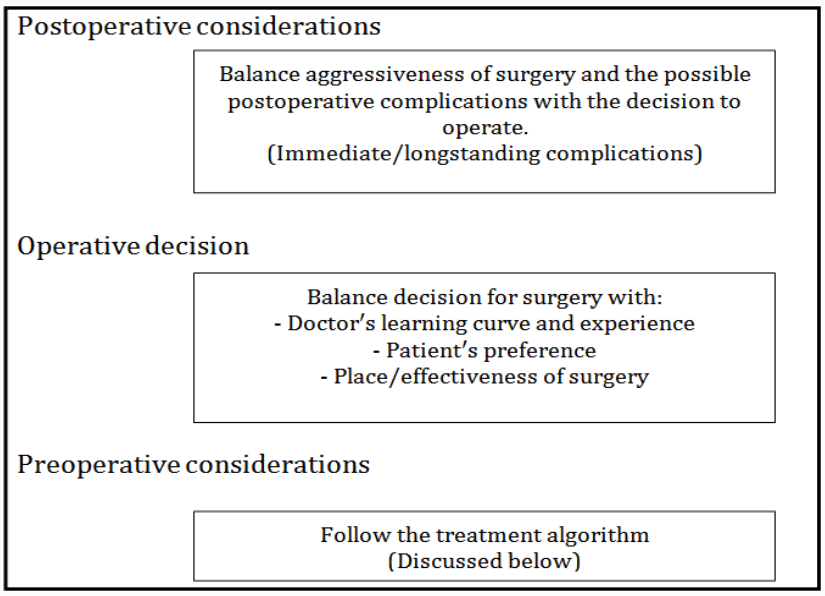

Figure 1: Tongue base surgery balanced decision considerations.

invasiveness of the surgery with the expected outcome [17].

Selection of tongue base reduction technique is not an easy job and may be a complex one. Aiming to reduce the postoperative morbidity and complications, minimally invasive tongue base surgery has been developed. Coblation assisted Submucosal Minimally Invasive Lingual Excision (SMILE) was introduced to reduce the possible complications and maximize patients benefit [10]. Elshaug et al. [18] considered a different opinion in the management algorithm, giving the priority for conservative treatment over the surgical treatment should be the role and surgery should be preserved only at the level of study purposes.

How should we change our practice?

The aim of this article is to handle the tongue base surgery in a different management approach. If we go through the trip of the tongue base surgery for any OSA patient, it will be better to start thinking from the postoperative period inwards. With the following discussion, we are hoping that the patient's approach will be changed (Figure 1).

Decision for tongue base reduction surgery in patients with obstructive sleep apnea should be carefully considering the possible surgical complications, unfavorable surgical outcomes that may force the patients to have further surgical intervention.

Characterizing postoperative complications of OSA surgery is of equal importance, to be considered. Most of the literatures addressed the immediate postoperative on the expense of the long-term postoperative complications, such as dysphagia and taste disturbance [19-21].

Surgery for Obstructive Sleep Apnea (OSA) is known to have an increased incidence of perioperative complications [22,23]. Based on the American Society of Anesthesiologists Guidelines, the operative risk for OSA patients depends mainly one the degree and severity of airway obstruction along with the degree of invasiveness of the operation [24,25]. These expert opinion-based guidelines considered OSA surgery as one of the highest risks of perioperative complications. OSA surgery, as a must, needs an intimate perioperative monitoring as it may leads to dangerous and potentially life-threatening complications as the airway is extremely narrow by different a anatomical abnormality that contributes to airway obstruction and any postoperative edema or bleeding will compromise the airway more. Terris et al. [26] concluded that close postoperative monitoring in the first 2 h and every effort should be consumed to guide against any bleeding or airway obstruction and for the maximum patient's safety, a postoperative nasal airway should be ready, and patients should be observed in high-dependency unit at least overnight.

Woodson, in 2007, performed an open tongue resection with the assistance of coblation technology and direct laryngoscope to minimize the risk of trauma and edema and to reduce morbidity [27]. With the use of coblation technology, a relatively new approach, Submucosal Minimally Invasive Lingual Excision (SMILE), has been developed as a minimally invasive technique aiming to maximize tongue base tissue ablation with minimal side effects. However, the possible need for repeated surgical sessions is an obvious disadvantage [10].

Surgeons should take into consideration when tongue base surgery is performed the hypopharynx's role in respiration, speech, and swallowing.

Taste Dysfunction (TD) has been underestimated in the literature as one of the long-standing complications of tongue base reduction surgery. However, however, surgeon must inform the patient about this considerable complication as it is remaining a high alert concern for all the patients. The most warning surgical techniques in the literatures that carry the risk of postoperative Taste Dysfunction (TD) includes coblation lingual tonsillectomy, Transoral Robotic Surgery (TORS) Base of Tongue (BOT) reduction, and submucosal lingualplasty. However, for most of the patients, TD is frequently a short team complication that resolves after a few months, but it can be more problematic if stay more longer [28]. Eun et al. [29] reported that gustatory function remained unchanged after RF-TBR in their short-term follow-up. However, certain degrees of TD can occur with other tongue base reduction surgeries. Lin et al. [30] concluded that TD can be one of the late complications after their Endoscopic coblator

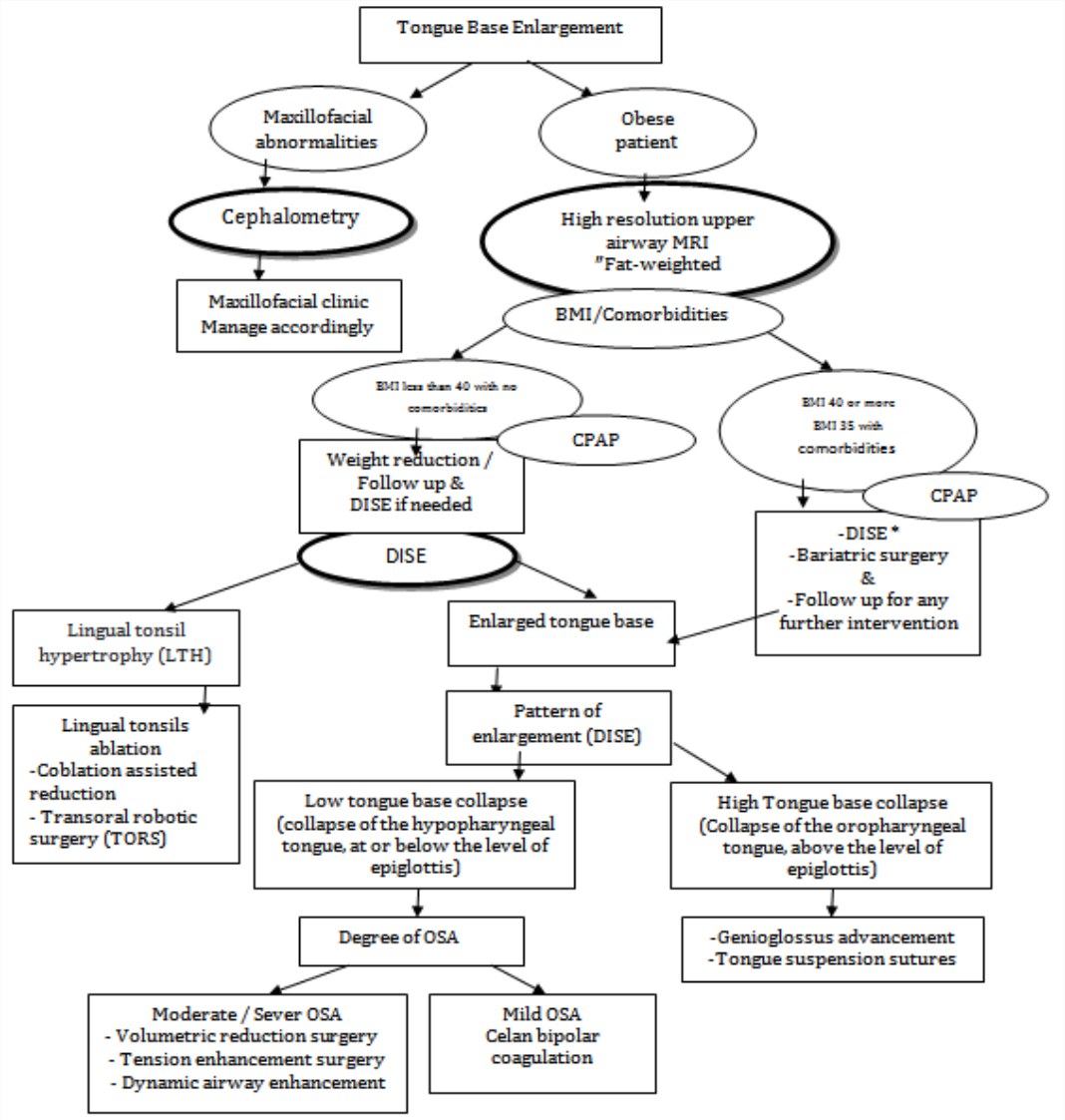

Figure 2: Management algorithm for tongue base surgery.
*DISE: Performed for documentation of upper airway obstruction sites

open Tongue Base Resection (Eco-TBR) technique. Generally, as the degree of TD can be related to the modality of surgical intervention and the operation time, surgeons should clearly notify the patients about the possibility of postoperative TD. Further studies are needed to considerably clarify the risk of TD with each modality of surgical intervention.

Although still in its infancy, the clinical assessment of gustatory function subjective and objective testing should be part of the pre and postoperative workup of the OSA patients. Different gustatory function tests are available, yet there is no gold standard one. Because of its clinical convenience and good test–retest reliability, the three-drop method using four main flavors has been widely used to examine basic tastes [31].

Dysphagia considerably cited to be the most common long-term complication in OSA surgery. Because of wide time range of symptom assessment, the reported incidence of dysphagia was between zero and 60%, even with separate surgical technique studies [32,33]. Hyoid Myotomy with Suspension (HMS) is one of the tongue base reduction surgeries that strongly need to have preoperative dysphagia counseling with OSA patients [34]. Although not frequently cited as a complication of sleep surgery, globus is generally a common complaint and although benign, it may have a persistent course. Radio Frequency Ablation (RFA) treatment of the tongue base has been shown to increase the incidence of gloubs sensation by fivefold in comparison to others mostly because of increased formation of postoperative scar tissue. This in turn, explain the magnitude of increase in complaint seen in RFA that is absent in other procedures [34,35]. Preoperative swallowing tests and late postoperative assessment, both are important in-patient selection and postoperative follow up.

Operative decision making needs to have some requirements. Balancing the operative risks, which vary considerably between different types of operations, versus the outcome is the first and most important factor. The combination of genioglossus advancement and hyoid suspension has been recommended to be as a guide surgical technique for the surgical treatment outcomes after the publication of a large series using this combination to treat

hypopharyngeal obstruction [36]. Second, which has a key stone value, the incorporation of the clinical expertise, training level of the surgeon? Patient values and preference must be considered in making treatment decisions.

Running through the preoperative assessment of OSA patient, obesity should have a considerable concern.

Looking back on the advancements of Obstructive Sleep Apnea (OSA) surgery, tongue base surgery has always been a challenge. Traditionally, hypopharyngeal/tongue base procedures for OSA are usually aggressive and more technically challenging.

Tongue fat deposition has been linked to be one of the major risk factors in obese patients with OSA [37]. An autopsy study addressed that the percentage of tongue fat deposition, specifically tongue base, was matched with the degree of obesity with accompanying increase in tongue volume [38]. Kim et al. [39] has been used the three-point Dixon method (a method for fat/water discrimination) aiming to differentiates between fat deposition in obese patients with and without sleep apnea. First, Dixon MR imaging visualized tongue fat deposition better than the spin echo sequence. Second, intramuscular fat percentage was very high (32.6%), after controlling demographic factors. In contrast to previous autopsy [38], and fast spin echo imaging [40] studies, they found that fat in not equally deposited in the muscles of the upper air way and the tongue has the upper hand as a fat deposition reservoir. Genetic heritability of fat distribution phenotypes can be an explanation for increased fat in the apneic tongue in obese patients [41]. Fat deposits in the abdomen in men and neck in women have been previously as a risk factor for OSA in obese patients [42,43]. Soft palatal fat deposition has been reported also in obese patients with OSA [44]. As the tongue is known to be an increased, intramuscular tongue will be a major factor that affects the not only the tongue size, which affects airway size and collapsibility, but the pharyngeal dilator muscle function of the tongue. Intern, this adversely will alter the tongue's shape, that will be reflected on airway shape, and reduce its contractile force as a main pharyngeal dilator. The retroglossal airway size will be reduced increasing the risk of sleep apnea [45-47]. Increase in intramuscular fat may modify transmission of contractions across multiple muscles within the tongue. Fat infiltration at these critical junctions may adversely affect the shape modifications needed to prevent apneic attacks [48]. Bariatric surgery has been proven to gives the optimum weight loss and results in cure or improvement of OSA in a significant proportion of patients [49]. Bariatric surgery approved to has a significant improvement in both subjective and objective parameters of OSA [50-53].

Going through the first lines of treatment for OSA patients with enlarged tongue base, different options will be available. Continuous Positive Airway Pressure (CPAP) remains the gold standard first line treatment for obstructive sleep apnea in adults [54,55]. Weight reduction is recommended as adjunctive treatment [56]. With CPAP failure, mandibular advancement devices may be considered with conservative management as second line treatment [57]. Surgery for obstructive sleep apnea, specifically tongue base surgery, should be reserved as a last line of treatment that should be done within acceptable level of evidence and patients should be informed in detail about the perioperative details, as well as of the postoperative drawback and outcomes. Figure 2 show the management algorithm for tongue base surgery.

Conclusion

Basic concepts in Hypopharyngeal Surgery should be clear before deciding any line of treatment for this group of patients. Understanding these concepts builds a framework in the thought process of customizing the treatment decisions to individual patients in the setting of multiple variables. Decision for tongue base reduction surgery in patients with obstructive sleep apnea should be carefully considering the possible surgical complications, unfavorable surgical outcomes that may force the patients to have further surgical intervention.

Conventional tongue base surgical procedures, as for example with midline glossectomy, are usually aggressive and associated with considerable incidence of both immediate and long-term complications. As a first line of treatment, Continuous Positive Airway Pressure (CPAP) with conservative weight reduction should be strongly advised and applied.

References

1. Friedman M, Ibrahim H, Joseph NJ. Staging of obstructive sleep apnea/hypopnea syndrome: A guide to appropriate treatment. Laryngoscope. 2004;114(3):454-9.
2. Lee CH, Hong SL, Rhee CS, Kim SW, Kim JW. Analysis of upper airway obstruction by sleep video fluoroscopy in obstructive sleep apnea: A large population-based study. Laryngoscope. 2012;122(1):237-41.
3. KK Li. Hypopharyngeal airway surgery. Otolaryngol Clin N Am. 2007;40(4):845–53.
4. Vroegop VA, Vanderveken OM, Boudewyns AN, Scholman J, Saldien V. Drug-induced sleep endoscopy in sleep-disordered breathing: Report on 1,249 cases. Laryngoscope. 2014;124(3):797–802.
5. Fujita S, Woodson BT, Clark JL, Wittig R. Laser midline glossectomy as a treatment for obstructive sleep apnea. Laryngoscope. 1991;101(8):805–09.
6. Prinsell JR. Maxillomandibular advancement surgery in a site-specific treatment approach for obstructive sleep apnea in 50 consecutive patients. Chest. 1999;116(6):1519–29.
7. DeRowe A, Gunther E, Fibbi A, Lehtimaki K, Vahatalo K, Maurer J, et al. Tongue-base suspension with a soft tissue-to-bone anchor for obstructive sleep apnea: preliminary clinical results of a new minimally invasive technique. Otolaryngol Head Neck Surg. 2000;122(1):100–103.
8. Neruntarat C. Genioglossus advancement and hyoid myotomy: Short-term and long-term results. J Laryngol Otol. 2003;117(6):482–6.
9. Hormann K, Baisch A. The hyoid suspension. Laryngoscope. 2004;114(9):1677–9.
10. Maturo SC, Mair EA. Submucosal minimally invasive lingual excision: An effective, novel surgery for pediatric tongue base reduction. Ann Otol Rhino Laryngol. 2006;115(8):624–30.
11. Foster GD, Borradaile KE, Sanders MH. A randomized study on the effect of weight loss on obstructive sleep apnea among obese patients with type 2 diabetes: The sleep Ahead study. Arch Intern Med. 2009;169(17):1619-26.
12. Sethukumar P, Kotecha B. Tailoring surgical interventions to treat obstructive sleep apnoea: One size does not fit all. Breathe (Sheff). 2018;14(3):e84–e93.
13. Kezirian EJ, Goldberg AN. Hypopharyngeal surgery in obstructive sleep apnea: An evidence-based medicine review. Arch Otolaryngol Head Neck Surg. 2006;132(2):1-8.
14. Shen T, Shimahara E, Cheng J, Capasso R. Sleep medicine clinical and surgical training during otolaryngology residency: A national survey of otolaryngology residency programs. Otolaryngol Head Neck Surg. 2011;145(6):1043-8.
15. Sackett DL, Straus SE, Richardson WS, Rosenberg W, Haynes RB. Evidence-based medicine: How to practice and teach EBM. 2nd Ed.

Philadelphia: Churchill Livingstone; 2000.

16. Maheswaran T, Abikshyeet P, Sitra G, Gokulanathan S, Vaithiyanadane V, Jeelani S. Gustatory dysfunction. J Pharm Bioallied Sci. 2014;6(suppl 1):S30–S33.

17. Lin HC, Friedman M, Chang HW, Gurpinar B. The efficacy of multilevel surgery of the upper airway in adults with obstructive sleep apnea/hypopnea syndrome. Laryngoscope. 2008;118(5):902–08.

18. Elshaug AG, Moss JR, Hiller JE, Maddern GJ. Upper airway surgery should not be first line treatment for obstructive sleep apnoea in adults. BMJ. 2008;336(7634):44-5.

19. Harmon JD, Morgan W, Chaudhary B. Sleep apnea: Morbidity and mortality of surgical treatment. South Med J. 1989;82(2):161–4.

20. Kezirian EJ, Weaver EM, Yueh B, Deyo RA, Khuri SF, Daley J, et al. Incidence of serious complications after uvulopalatopharyngoplasty. Laryngoscope. 2004;114(3):450–53.

21. Altman JS, Halpert RD, Mickelson SA, Senior BA. Effect of uvulopalatopharyngoplasty and genial and hyoid advancement on swallowing in patients with obstructive sleep apnea syndrome. Otolaryngol Head Neck Surg. 1999;120(4):454–7.

22. Kaw R, Pasupuleti V, Walker E, Ramaswamy A, Foldvary-Schafer N. Postoperative complications in patients with obstructive sleep apnea. Chest. 2012;141(2):436-41.

23. Liao P, Yegneswaran B, Vairavanathan S, Zilberman P, Chung F. Postoperative complications in patients with obstructive sleep apnea: A retrospective matched cohort study. Can J Anaesth. 2009;56(11):819-28.

24. Gross JB, Bachenberg KL, Benumof JL. Practice guidelines for the perioperative management of patients with obstructive sleep apnea: A report by the American Society of Anesthesiologists Task Force on Perioperative Management of patients with obstructive sleep apnea. Anesthesiology. 2006;104(5):1081-93.

25. American Society of Anesthesiologists Task Force on Perioperative Management of patients with obstructive sleep apnea, 2014. Practice guidelines for the perioperative management of patients with obstructive sleep apnea: An updated report. Anesthesiology. 2014;120(2):268-86.

26. Terris DJ, Fincher EF, Hanasono MM, Fee WE Jr, Adachi K. Conservation of resources: indications for intensive care monitoring after upper airway surgery on patients with obstructive sleep apnea. Laryngoscope. 1998;108(6):784-8.

27. Woodson BT. Innovative technique for lingual tonsillectomy and midline posterior glossectomy for obstructive sleep apnea. Oper Techn Otolaryngol Head Neck Surg. 2007;18(1):20-28.

28. Kwinter A, Pang K, Brian R. Should surgeons routinely inform patients about risks of taste dysfunction after tongue base surgery for sleep apnea? Laryngoscope. 2017;127(6):1253–4.

29. Eun YG, Shin SY, Byun JY, Gu Kim M, Lee KH, Kim SW. Gustatory function after radiofrequency tongue base reduction in patients with obstructive sleep apnea. Otolaryngol Head Neck Surg. 2011;145(5):853–7.

30. Lin HC, Hwang MS, Liao CC, Friedman M. Taste disturbance after tongue base resection for OSA. Laryngoscope. 2016;126(4):1009-13.

31. Li HY, Lee LA, Wang PC, Hsiao HR, Hsu CY, Chen NH, et al. Taste disturbance after uvulopalatopharyngoplasty for obstructive sleep apnea. Otolaryngol Head Neck Surg. 2006;134(6):985–90.

32. Steele CM, Bailey GL, Chau T, Molfenter SM, Oshalla M, Waito AA, et al. The relationship between hyoid and laryngeal displacement and swallowing impairment. Clin Otolaryngol. 2011;36(1):30–36.

33. Stuck BA, Starzak K, Verse T, Hormann K, Maurer JT. Complications of temperature-controlled radiofrequency volumetric tissue reduction for sleep disordered breathing. Acta Otolaryngol. 2003;123(4):532–5.

34. MG Kato, MJ Isaac, MB Gillespie. Characterizing swallowing symptoms following OSA surgery. J Clin Sleep Med. 2018;14(1):127–32.

35. Lim DJ, Kang SH, Kim BH, Kim HG. Treatment of primary snoring using radiofrequency-assisted uvulopalatoplasty. Eur Arch Otorhinolaryngol. 2007;264(7):761–7.

36. Riley RW, Powell NB, Guilleminault C. Obstructive sleep apnea syndrome: A review of 306 consecutively treated surgical patients. Otolaryngol Head Neck Surg. 1993;108(2):117-25.

37. Kovanlikaya A, Guclu C, Desai C, Becerra R, Gilsanz V. Fat quantification using three-point dixon technique: *In vitro* validation. Acad Radiol. 2005;12(5):636-9.

38. Nashi N, Kang S, Barkdull GC, Lucas J, Davidson TM. Lingual fat at autopsy. Laryngoscope. 2007;117(8):1467-73.

39. Kim AM, Keenan BT, Jackson N, Chan EL, Staley B, Poptani H, et al. Tongue fat and its relationship to obstructive sleep apnea. SLEEP. 2014;37(10):1639-48.

40. Humbert IA, Reeder SB, Porcaro EJ, Kays SA, Brittain JH, Robbins J. Simultaneous estimation of tongue volume and fat fraction using IDEALFSE. J Magn Reson Imaging. 2008;28(2):504-8.

41. Malis C, Rasmussen EL, Poulsen P, Petersen I, Christensen K, Nielsen HB, et al. Total and regional fat distribution is strongly influenced by genetic factors in young and elderly twins. Obes Res. 2005;13(12):2139-45.

42. Simpson L, Mukherjee S, Cooper MN, Ward KL, Lee JD, Fedson AC, et al. Sex differences in the association of regional fat distribution with the severity of obstructive sleep apnea. Sleep. 2010;33(4):467-74.

43. Schwab RJ, Pasirstein M, Kaplan L, Pierson R, Mackley A, Hachadoorian R, et al. Family aggregation of upper airway soft tissue structures in normal subjects and patients with sleep apnea. Am J Respir Crit Care Med. 2006;173(4):453-63.

44. Li Y, Na L, Ye J, Chang Q, Han D, Sperry A. Upper airway fat tissue distribution differences in patients with obstructive sleep apnea and controls as well as its effect on retropalatal mechanical loads. Respir Care. 2012;57(7):1098-105.

45. White DP. 2006. Sleep apnea. Proc Am Thorac Soc. 2006;3:124-8.

46. Leiter JC. Upper airway shape: Is it important in the pathogenesis of obstructive sleep apnea? Am J Respir Crit Care Med. 1996;153(3):894-8.

47. Watanabe T, Isono S, Tanaka A, Tanzawa H, Nishino T. Contribution of body habitus and craniofacial characteristics to segmental closing pressures of the passive pharynx in patients with sleep-disordered breathing. Am J Respir Crit Care Med. 2002;165(2):260-5.

48. Kjaer M. Role of extracellular matrix in adaptation of tendon and skeletal muscle to mechanical loading. Physiol Rev. 2004;84(2):649-98.

49. Haines KL, Nelson LG, Gonzalez R, Torrella T, Martin T, Kandil A, et al. Objective evidence that bariatric surgery improves obesity-related obstructive sleep apnea. Surgery. 2007;141(3):354-8.

50. Varela JE, Hinojosa MW, Nguyen NT. Resolution of obstructive sleep apnea after laparoscopic gastric bypass. Obes Surg. 2007;17(10):1279–82.

51. Fritscher LG, Mottin CC, Canani S, Chatkin JM. Obesity and obstructive sleep apnea-hypopnea syndrome: The impact of bariatric surgery. Obes Surg. 2007;17(1):95–9.

52. Sarkhosh K, Switzer NJ, El-Hadi M, Birch DW, Shi X, Karmali S. The impact of bariatric surgery on obstructive sleep apnea: A systematic review. Obes Surg. 2013;23(3):414–23.

53. Buchwald H, Avidor Y, Braunwald E, Jensen MD, Pories W, Fahrbach K, et al. Bariatric surgery: A systematic review and meta-analysis. JAMA. 2004;292(14):1724–37.

54. Young T, Skatrud J, Peppard P. Risk factors for obstructive sleep apnea in

adults. JAMA. 2004;291(16):2013-6.

55. Scottish Intercollegiate Guidelines Network. Management of obstructive sleep apnoea/hypopnoea syndrome in adults: A national clinical guideline Edinburgh: SIGN. 2003.

56. Morgenthaler TI, Kapen S, Lee-Chiong T, Alessi C, Boehlecke B, Brown T, et al. Practice parameters for the medical therapy of obstructive sleep apnea. Sleep. 2006;29(8):1031-5.

57. Lim J, Lasserson TJ, Fleetham J, Wright J. Oral appliances for obstructive sleep apnoea. Cochrane Database Syst Rev. 2006;(1):CD004435.