Journal of Dentistry and Oral Biology

Case Report
Published: 07 Sep, 2017

Three-Dimensional Surface Model Analysis of Intraoral Maxillary Protraction Combined with Alt-RAMEC: A Case Report

*Hatice Gökalp**

Department of Orthodontics, University of Ankara, School of Dentistry, Beşevler, Ankara, Turkey

Abstract

Protraction face-mask (PFM) therapy is the most common approach for early treatment of Class III patients with maxillary deficiency. Main goal of the therapy is to achieve the orthopedic effect rather than dento-alveolar correction. Maxillary protraction combined with maxillary expansion simplifies maxillary advancement. On the other hand, early Class III treatment with PFM therapy generally needs patient's cooperation. Effective protraction of maxilla is provided by disarticulation of maxilla from neighbor bones. The use of intraoral protraction spring (IPS) combined with the Alternate Rapid Maxillary Expansions and Constrictions (Alt-RAMEC) is preferred method recently not only to eliminate patient's cooperation but also to disarticulate maxilla from the circum-maxillary sutures. The purpose of this case report is to evaluate the skeleto-facial effects of IPS combined with Alt-RAMEC in pubertal growth period by cone beam computed tomography (CBCT). Alt-RAMEC-IPS therapy affected the naso-maxillary structures entirely and showed significantly favorable effects on maxillary advancement. The use of Alt-RAMEC/IPS appears to be a promising treatment method instead of using PFM therapy.

Keywords: Alt-RAMEC; Intraoral maxillary protraction; Maxillary deficiency

Introduction

Treatment of Class III malocclusion with maxillary deficiency is one of the most challenging skeletal anomalies in orthodontics. Protraction face mask (PFM) therapy combined with rapid maxillary expansion (RME) is the most common approach for early treatment of these patients. As well as this treatment approach results uncertain skeletal and inevitable dento-alveolar effects [1,2], wearing these un-aesthetic extra-oral appliance is required for 12 to 16 h per day for 9 to 12 months for satisfactory clinical success [3-5]. Force delivered by rapid maxillary expansion affects directly on mid-palatal suture and partially on circumaxillary sutures. Disarticulation of the maxilla from circumaxillary bones is required for simplifying maxillary protraction. Double-hinged expansion screw is used by a new the expansion protocol named alternate maxillary expansions and constrictions (Alt-RAMEC) that disarticulates the maxillary bone from the surrounding sutures for providing effective maxillary protraction. Effects of Alt-RAMEC on circumaxillary sutures are researched by both animal [6,7] and clinical [1,8-14] studies. Advantage of the method is to provide pure maxillary protraction without using any extra-oral protraction appliance. Furthermore, in serious maxillary deficiencies it is recommended to use Alt-RAMEC combined with intraoral protraction spring (IPS) instead of extra-oral appliance [1,14]. It is stated that using intraoral maxillary protraction combined with Alt-RAMEC increases the orthopedic effects [1,14]. Three dimensional images have been recently used in orthodontics for eliminating the insufficiency of traditional two-dimensional images [15]. Purpose of this case report is to evaluate the skeleto-facial effects of the IPS combined with Alt-RAMEC in a pubertal patient by cone beam computed tomography (CBCT).

Case Presentation

Diagnosis and etiology

The patient, an adolescent girl, age 13 years, came to University of Ankara, Department of Orthodontics in Turkey with a complaint about her un-aesthetic facial-dental appearance and anterior cross-bite in addition to posterior cross-bite of right side. In her medical history, her uncle had similar skeletal discrepancy. She had Class III malocclusion associated with maxillary retrusion with an -3 overjets and 8 mm overbite. There was a 3 mm midline discrepancy caused by

OPEN ACCESS

***Correspondence:**
Hatice Gökalp, Department of Orthodontics, University of Ankara, School of Dentistry, Beşevler, Ankara, Turkey,
E-mail: haticegokalp@yahoo.com

Received Date: *16 Jun 2017*
Accepted Date*: 30 Aug 2017*
Published Date*: 07 Sep 2017*

Citation:
Gökalp H. Three-Dimensional Surface Model Analysis of Intraoral Maxillary Protraction Combined with Alt-RAMEC: A Case Report. J Dent Oral Biol. 2017; 2(12): 1078.

ISSN: 2475-5680

Figure 1: Extraoral and intraoral photograps before treatment.

mandible. Upper and lower arch length discrepancy was -12 mm/-4 mm respectively (Figure 1). Her growing stage was stage III according to cervical vertebra maturation (CV) method.

Treatment objectives

The main treatment objectives were to resolve transverse and sagittal maxillary discrepancy and to establish facial and smile esthetic.

Treatment alternatives

Two treatment alternatives were proposed. The first option was the contemporary technique combined use of rapid maxillary expansion (RME) and extra oral protraction facemask (PFM). On the other hand, it was demonstrated that RME insufficiently effects on circumaxillary sutures [16-18] and patient co-operation using PFM leads unsuccessful results because of un-esthetic appearance of it. For this reason, in many cases, patients would prefer to undergo surgical correction rather than to use the extra-oral appliances when growth was completed. Protraction spring has been the only intraoral device that delivers reasonable orthopedic force for maxillary orthopedic protraction. Because she was an adolescent nonsurgical treatment consisted of Alt-RAMEC-IPS combination was planned in this case.

Treatment progress

Before the treatment, patient and her parent provided written informed consent after receiving verbal and written explanations of the treatment. The appliance containing a hyrax expansion screw was applied to open the maxillary suture by a protocol of Alt-RAMEC. The patient's parent was instructed to open the screw by 0.5 mm per day during the first week and to close it by 0.5 mm per day the week after. This alternate opening and closing was repeated for 7 consecutive weeks and immediately after expansion period IPSs were applied for 6 months. Alt-RAMEC effect on circumaxillary sutures is simulated to tooth extraction in which the tooth is rocked buccally and lingually to loosen from the alveolar socket. Similarly, opened and closed of the expansion screw rocks the maxillary sutures articulated circumaxillary bone. Maxillary protraction was produced by a pair of fixed 0.036" TMA helical springs having 100° to 120° angle with mandibular anchorage by banding first molars, premolars and canines with 0.018 × 0.025 inch pre-adjusted bracket system and a lingual arch in this case (Figure 2). Active maxillary protraction was applied for 4 months and protraction springs was kept intra-orally for 2 months without adding extra-oral force. After maxillary protraction, she was in the CV stage IV growing period according to cervical vertebra maturation method. Upper and lower arch length discrepancy was -15 mm and 3 mm respectively and 2 mm overjet and

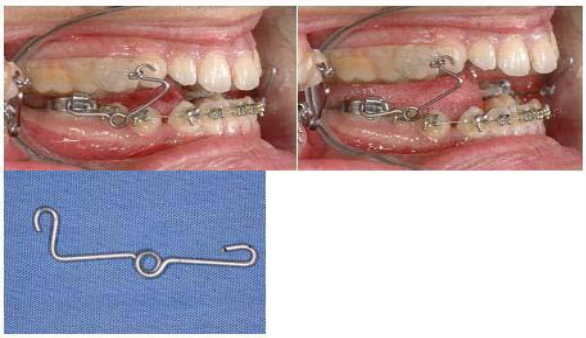

Figure 2: Intraoral Protraction Spring (IPS). **A.** IPS view closed the mouth; **B**. IPS view opened the mouth.

Figure 3: Extraoral and intraoral photograps after treatment of IPS combined with Alt-RAMEC.

Figure 4: Extraoral and intraoral photograps after Orthodontic treatment.

2 mm overbite was maintained (Figure 3). At the end of orthopedic traction, hyrax expander and springs removed and trans-Palatal arch was inserted on palate. First permanent premolars in the both side were extracted to eliminate the upper arch length discrepancy and first molars, premolars and canines banded with 0.018 × 0.025 inch

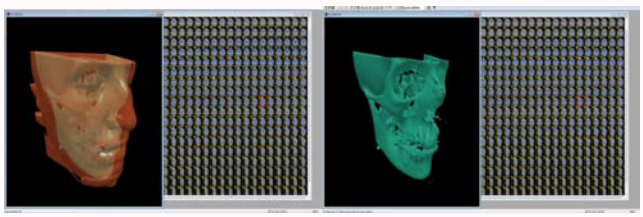

Figure 5: Segmentation process.

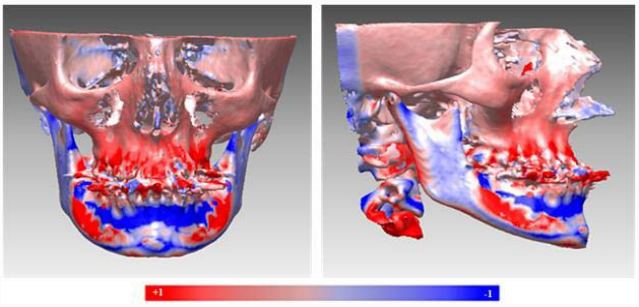

Figure 6: Color maps of 3D superimpositions of craniofacial structures at T1-T2.

pre-adjusted bracket system. Total treatment time was 34 months (Figure 4). To visualize the treatment changes in 3 dimensions, CBCT records were taken before treatment (T1), immediately after orthopedic treatment included IPS-Alt-RAMEC combination (T2) and at the end of fixed orthodontic therapy (T3). Three-dimensional surface models of the anatomic region were constructed from T1, T2 and T3 images of patient by using 3D modeling software Rhinoceros 4.0 (3670 Woodland Park Ave N, Seattle, WA 98103 USA) and match and quality control software VR Mesh Studio (Virtual Grid Inc, Bellevue City, WA, USA).

For modeling the bone tissue, cranio-facial region was scanned by a cone beam computed tomography (ILUMA, Orthocad, CBCT, 3M Imtec, Oklahoma, USA). 601 cross-sectional images were obtained at 120 kVp, 3.8 mA and a voxel size of 0.3 mm, with an exposure time 40 s. Cross-sectional images were saved as digital imaging and communications in medicine (DICOM) files and taken to 3D-Doctor programme for re-construction. By Interactive Segmentation method, Hounsfield values were evaluated and bone tissue was separated (Figure 5). After separation, 3D models were obtained by 3D- Complex Render technique. At T1, T2 and T3, 3D models were registered on anterior cranial fossa structures, specifically the endocrinal surfaces of the cribriform plate region of the ethmoid bone and internal surface of the frontal bone. These regions were chosen because of their early completion of growth [19-21]. Three dimensional surfaces were created for all models and loaded into superimposition program. The initial and registered final models were superimposed, and treatment changes were expressed via color maps that represent the closest-point surface distance from the final model to the initial one. For additional comparative assessment of changes between the models, non-transparent superimpositions were also used. DICOM files were also used to create synthetic lateral cephalograms for T1, T2 and T3 by using imaging software (version 10.1, Dolphin Imaging, Chastworth, Calf), which uses an algorithm that recreates perspective projections. The software allows the user to specify where the central ray of the imaginary x-ray beam is focused. Lateral cephalograms for T1, T2 and T3 were digitally traced. The

Table 1: Cephalometric analysis before treatment (T1), After Alt- RAMEC-Protraction Spring treatment (T2) and at the end of fixed Orthodontic Treatment.

Measurements	T1	T2	T3
SNA (°)	82°	8	82
Na Perp– Point A	-5	0	-1
SNB (°)	86	81.5	81
Na Perp-Pogonion (mm)	0	-2	-3
ANB (°)	-4	1.5	1°
Go-Gn/FH (°)	30	34.5	32.5
Facial axis angle	90	95	96
Co–A (mm)	104	101	98
Co–Gn (mm)	145	138	136
CoGn–CoA (mm)	39	39.5	43
1-NA (mm)	5	7	7
1–NB (mm)	7	5	7
Maxillary first molar width (mm)	64	68	69
Lateroorbitale width (mm)	77	78	78
Lateronasal width (mm)	16	18	18
Bizygomatic width (mm)	147	149	150
Maxillary width (mm)	75	77	77
Upper lip to S line (mm)	-4	-2	-2.5
Lower lip tp S line (mm)	0	1.5	-1.5

cephalometric measures show on Table 1.

Treatment results

Patient was evaluated with focus on the following anatomic regions:

1. Anterior and posterior surface of maxilla
2. Zygomatic process of maxilla
3. Anterior and posterior surface of mandible
4. Inferior border of mandible
5. Anterior and posterior surface of condyles
6. The soft tissues in nasal region, the upper and lower lips, cheek and chin.

The skeletal and soft tissue changes between T1, T2 and T3 in the areas of interest are shown as color maps or non-transparencies in (Figures 6-11). Magnitude and direction of skeletal and soft tissue movements were assessed as color changed from red to blue represented positive (outward) and negative (inward) movement respectively.

Figure 5 and 6 show skeletal changes between T1 and T2 in maxilla, mandible, zygomatic process, condyles as color maps and non-transparencies. Positive (outward) movement showed in anterior and posterior maxillary regions through inferior border of the zygomatic process. Changes in the anterior and posterior mandibular regions were more variable in both magnitude and direction (Figure 6). Surface distance between left and right condyles were similar each other. Condyles showed negative (inward) change on anterior surfaces and positive (outward) change on posterior surfaces. Inferior border of mandible showed positive change (Figure 7).

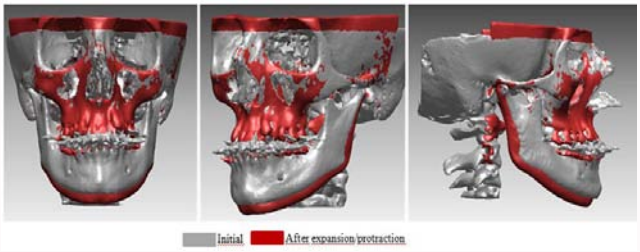

Figure 7: Nontransparent 3D superimpositions of craniofacial structures at T1-T2.



Figure 8: Nontransparent 3D superimpositions of facial soft tissues at T1-T2.

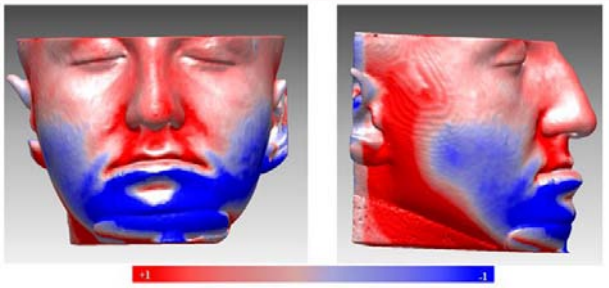

Figure 9: Color maps of 3D superimpositions of facial soft tissues at T1-T2.

The soft tissues in the upper lip and lateral side of nasal regions showed positive changes. Chin and cheeks showed negative changes (Figure 8). Non-transparency of 3D superimpositions was made to evaluate changes of maxilla, circum-maxillary bones, mandible and soft tissues on T1-T2. Gray color showed T1 and red color showed T2 3D model. To evaluate changes of maxillary expansion and protraction (T1-T2), 3D model of red color (T2) was superimposed on 3D model of gray color (T1). Maxillary bone included zygomatic process through bilateral zygomatico-maxillary junction, bilateral inferior orbital border and lateral walls of nasal cavity moved forward bodily (Figure 7). While posterior border of ramus mandible through posterior condylar region moved backward, inferior border of corpus mandible moved downward. Red color was covered by gray color so that chin moved backward in T2. Therefore, red color no visualized in chin because of non-transparency of 3D superimposition. While soft tissues of nose, sub-nasal region and upper lip moved forward, soft tissue chin moved backward (Figures 8 and 9). Figure 10 show skeletal changes between T2 and T3 in maxilla, mandible, condyles as color maps and non-transparencies. Maxillary anterior teeth and maxillary premolars moved forward and lateral. Mandibular anterior teeth moved backward and overjet was positive. Mandibular corpus, ramus and condyle showed positive (outward) movement. Change in chin was invariable in both magnitude and direction (Figure 10).

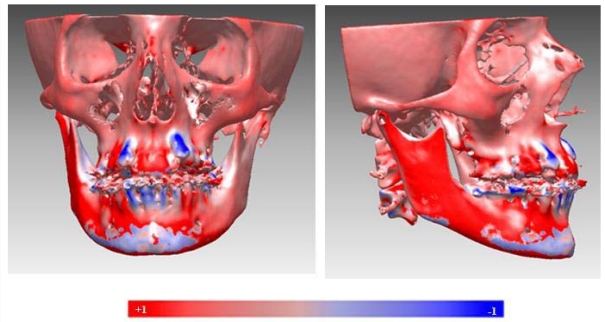

Figure 10: Color maps of 3D superimpositions of craniofacial structures at T2-T3.

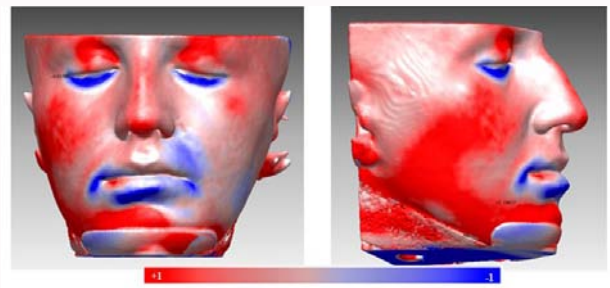

Figure 11: Color maps of 3D superimpositions of facial soft tissues at T2-T3.

Change in upper lip was invariable in both magnitude and direction. Negative movement (inward) showed in lower lip but there were considerable variations in magnitude. Nose tip and cheeks showed positive (outward) movement but more variable in both magnitude and direction (Figure 11). Cephalometric assessment for skeletal, soft tissue and dental changes for Alt-RAMEC/IPS treatment summarize on Table 1. By the therapy, a point showed a great improvement (5 mm) in horizontal movement. Increase in SNA and decrease in SNB angles improved the inter-maxillary relationship (ANB +5.5°) and by this way overjet decreased. A relative increase in vertical dimension at expansion-protraction phase, decreased immediately after acquiring molar contacts by the fixed orthodontic therapy. Clockwise rotation of the mandible and minimal retroclination of lower incisors were obtained. Upper/lower lips changes were variable in T2 and T3 (Table 1).

Discussion

The aim of this case report was to assess a new treatment approach for growing Class III patients combined with maxillary retrusion and to describe the skeletal, dental and soft tissue changes in 3 dimensions. The cephalometric and 3D measurements seem to confirm that Alt-RAMEC-IPS treatment combination comprised more orthopedic correction with less dentoalveoler effect when compared with PFM/RME [22-27]. The 3D assessments for this case report have been shown to be more reliable than 2D imaging alone. Color maps and non-transparencies were preferred to obtain more accurate data. Reports about the effects of maxillary expansion on maxillary position have inconsistencies. Wertz [28], reported forward change in the position of maxilla, whereas Pangrazio-Kulbersh et al. [3] reported no significant displacement, or even Sarver and Johnston [29] reported a posterior displacement of maxilla. Alt-RAMEC protocol is developed for a greater anterior displacement of maxilla by eliminating resistance of circum-maxillary sutures Liou and Tsai [14] presented the Alt-RAMEC protocol in 3 components: a double-hinged rapid maxillary

expander, repetitive weekly protocol of Alt-RAMEC and IPSs. Researchers introduced the new kind of expander as a more superior device than the other types of expanders for the treatment of a hypoplastic maxilla in growing Class III patients. In this case, protocol has been modified by using Alt-RAMEC protocol with a Hyrax-type maxillary expander and IPSs to assess the treatment differences versus the original one. Liou and Tsai [14] reported an excessive anterior movement of maxilla after Alt-RAMEC with double-hinged palatal expander in 2D measurements; while Yilmaz and Kucukkeles [30] found slight forward and downward movement of maxilla in pre-adolescents by 3D evaluation. In this case, maxilla moved forward but pure maxillary displacement by maxillary expansion couldn't be assessed because second record taken at the end of protraction phase by reason of given ionizing radiation exposure. Efficiency of maxillary protraction is based on opening the circum-maxillary sutures. Alt-RAMEC disarticulates maxilla from circum-maxillary sutures and enables maxillary protraction. A point showed a great improvement (5 mm) in horizontal movement and A-point displacement is more excessive than those reported with PFM in limited 2D studies. Assessment of treatment effects on 3D color-map superimpositions becomes possible not only for maxilla but also for circum-maxillary region. Maxillary bone included zygomatic process through bilateral zygomatico-maxillary junction, bilateral inferior orbital border and lateral walls of nasal cavity is affected by Alt-RAMEC/IPS treatment. Inferior border of the zygomatic process showed a positive change in this case. Wang showed that Alt-RAMEC opens coronally running circum-maxillary sutures (Fronto-maxillary, zygomatico-maxillary and inside the orbit) quantatively more than conventional RME in an animal study. This case is the first attempt to explore that a modified Alt-RAMEC procedure affects the circum-maxillary sutures and facilitates the maxillary protraction.

There is a great deal of controversy in the literature regarding to optimal force of PFM treatment, but after summarizing the studies, it could be concluded that 300 g to 400 g of force is more efficient for maxillary protraction. IPS is activated when the mandible closes and a 300 g to 400 g horizontal and upward force on each side is created. Cephalometric measurements showed that increase in SNA and decrease in SNB angles improved inter-maxillary relationship (ANB +5.5°) and by this way overjet decreased. In this case, a skeletal maxillary forward displacement was obtained just in 5, 5 months by an intraoral approach which motivates the patient. However, IPS made by titanium-molybdenum was frequently broken due to material fatique or chewing force and during treatment IPSs needed to be fabricated for multiple times. In addition, IPS is indicated in low angle cases depending on the opening of the bite at the anterior and backward rotation of the mandible. The magnitude of changes in the mandible is more variable in this case. Anterior and partially posterior surface of the mandible showed negative changes by reason of clockwise rotation of mandible. Lingual holding arch is used for mandibular anchorage but despite this precaution, upper segment of the corpus mandible moved inward while lower segment of the corpus mandible moved outward. Collum and ramus mandible moved inward at protraction phase owing to the backward force by the IPSs but on the contrary opposite changes observed after fixed orthodontic treatment because of the late mandibular growing. One of the goals of treatment of Class III malocclusion is to significantly improve the dento-facial profile. Forward movement of the skeletal structures in naso-maxillary region shows similar variations in soft tissues. Favorable soft tissue changes were observed by the treatment similarly in PFM/RME studies.

Conclusion

1. Alt-RAMEC/IPS treatment, improves skeletal relationships in Class III malocclusion associated with maxillary deficiency with minimal dentoalveolar compensation in adolescent patient.

2. This treatment method could be preferred instead of extra-oral appliances for adolescents.

3. 3D data from CBCT allows for documentation of treatment changes.

References

1. Liou EJ. Toothborne orthopedic maxillary protraction in Class III patients. J Clin Orthod. 2005;39(2):68-75.
2. Kim JH, Viana MA, Graber TM, Omerza FF, BeGole EA. The effectiveness of protraction face mask therapy: a meta-analysis. Am J Orthod Dentofacial Orthop. 1999;115(6):675-85.
3. Pangrazio-Kulbersh V, Berger J, Kersten G. Effects of protraction mechanics on the midface. Am J Orthod Dentofacial Orthop. 1998;114(5):484-91.
4. Tortop T, Keykubat A, Yuksel S. Facemask therapy with and without expansion. Am J Orthod Dentofacial Orthop. 2007;132(4):467-74.
5. Keles A, Tokmak E C, Erverdi N, Nanda R. Effect of varying the force direction on maxillary orthopedic protraction. Angle Orthod. 2002;72(5):387-96.
6. Huang CT, Wang YC, Huang CS, Liou EJ. Maxillary displacement after rapid maxillary expansions: An animal study. J Taiwan Assoc Orthod. 2008;20(2):19-31.
7. Wang YC, Chang PM, Liou EJ. Opening of circumaxillary sutures by alternate rapid maxillary expansions and constrictions. Angle Orthod. 2009;79(2):230-4.
8. Isci D, Turk T, Elekdag-Turk S. Activation–deactivation rapid palatal expansion and reverse headgear in Class III cases. Eur J Orthod. 2010;32(6):706-15.
9. Liou EJ, Chen PKT. New orthodontic and orthopaedic managements on the premaxillary deformities in patients with bilateral cleft before alveolar bone grafting. Ann R Coll Surg. 2003;7(3):73-82.
10. Tsai WC, Huang CS, Lin CT, Liou EJ. Dentofacial changes of combined double-hinged rapid maxillary expansion and protraction facemask therapy. J Taiwan Assoc Orthod. 2008;20(2):5-18.
11. da Luz Vieira G, de Menezes LM, de Lima EM, Rizzatto S. Dentoskeletal Effects of Maxillary Protraction in Cleft Patients with Repetitive Weekly Protocol of Alternate Rapid Maxillary Expansions and Constrictions. Cleft Palate Craniofac J. 2009;46(4):391-8.
12. Do-deLatour TB, Ngan P, Martin CA, Razmus T, Gunel E. Effect of alternate maxillary expansion and contraction on protraction of the maxilla: a pilot study. Hong Kong Dent J. 2009;6:72-82.
13. Kaya D, Kocadereli I, Kan B, Tasar F. Effects of facemask treatment anchored with miniplates after alternate rapid maxillary expansions and constrictions; A pilot study. Angle Orthod. 2011;81(4):639-46.
14. Liou EJ, Tsai WC. A new protocol for maxillary protraction in cleft patients: Repetitive weekly protocol of alternate rapid maxillary expansions and constrictions. Cleft Palate Craniofac J. 2005;42(2):121-7.
15. Varghese S, Kailasam V, Padmanabhan S, Vikraman B, Chithranjan A. Evaluation of the accuracy of linear measurements on spiral computed tomography-derived three dimensional images and its comparison with digital cepha lometric radiography. Dentomaxillofac Radiol. 2010;39(4):216-23.
16. Ngan P, Yiu C, Hu A, Hagg U, Wei SH, Gunel E. Cephalometric and occlusal changes following maxillary expansion and protraction. Eur J

Orthod. 1998;20(3):237-54.

17. Williams MD, Sarver DM, Sadowsky PL, Bradley E. Combined rapid maxillary expansion and protraction facemask in the treatment of Class III malocclusions in growing children: A prospective long-term study. Semin Orthod. 1997;3(4):265-74.

18. Alcan T, Keles A, Erverdi N. The effects of a modified protraction headgear on maxilla. Am J Orthod Dentofacial Orthop. 2000;117(1):27-38.

19. Melsen B, Melsen F. The cranial base. The postnatal development of the cranial base studied histologically on human autopsy material. Am J Orthod. 1982;82(4):329-42.

20. Ford EHR. Growth of the human cranial base. Am J Orthod. 1958;44(7):498-506.

21. Scott JH. The cranial base. Am J Phys Anthropol. 1958;16(3):319-48.

22. Mermigos J, Full CA, Andreasen G. Protraction of the maxillofacial complex. Am J Orthod Dentofacial Orthop. 1990;98(1):47-55.

23. Ishii H, Morita S, Takeuchi Y, Nakamura S. Treatment effect of combined maxillary protraction and chin cup appliance in severe skeletal Class III cases. Am J Orthod Dentofacial Orthop. 1987:92(4);304-12.

24. Takada K, Petachai S, Sakuda M. Changes in dentofacial morphology in skeletal Class III children treated by a modified maxillary protraction headgear and a chin cup: A longitudinal cephalometric appraisal. Eur J Orthod. 1993;15(3):211-21.

25. Nanda R. Biomechanical and clinical consideration of a modified protraction headgear. Am J Orthod Dentofacial Orthop. 1980;78(2):125-39.

26. Ngan PW, Hagg U, Yiu C, Wei SH. Treatment response and longterm dentofacial adaptations to maxillary expansion and protraction. Semin Orthod. 1997;3(4):255-64.

27. Yepes E, Quintero P, Rueda ZM, Pedroze A. Systematic Review Optimal force for maxillary protraction facemask therapy in the early treatment of Class III malocclusion. Eur J Orthod. 2014;36(5):586-94.

28. Wertz RA. Skeletal and dental changes accompanying rapid midpalatal suture opening. Am J Orthod Dentofacial Orthop. 1970;58(1):41-66.

29. Sarver DM, Johnston MW. Skeletal changes in vertical and anterior displacement of the maxilla with bonded rapid palatal expansion appliances. Am J Orthod Dentofacial Orthop. 1989;95(6):462-6.

30. Yilmaz BS, Kucukkeles N. Skeletal, soft tissue, and airway changes following the alternate maxillary expansions and constrictions protocol. Angle Orthod. 2014;84(5):868-77.