Annals of Plastic and Reconstructive Surgery

Research Article
Published: 09 Sep, 2020

The Use of Acellular Dermal Matrix for Chest Wall Reconstruction: A Systematic Review

François Lescarbotte[1], Barbara Hersant[1], Raphaëlle Billon[1,2], Koohyar Habibi[1], Oana Hermeziu[1], Jean-Paul Meningaud[1] and Romain Bosc[1,2,3]*

[1]Department of Plastic, Reconstructive, Aesthetic and of Maxillofacial Surgery, Henri-Mondor University Hospital, France

[2]Henri Mondor Breast Center, Paris-Est Créteil University, France

[3]Université Paris-Est Créteil, INSERM, France

Abstract

Background: Chest wall reconstruction is required after full-thickness chest wall resection to preserve respiratory function and protect intra thoracic organs. Surgeons now have access to an array of synthetic and biologic prostheses that, together with soft-tissue coverage, restore chest wall integrity. The effectiveness of Acellular Dermal Matrices (ADM) in chest wall reconstruction has not been formally evaluated. To address this issue, we performed a systematic review of studies analyzing complication rates of ADM for chest wall reconstruction.

Materials and Methods: We performed a literature search in the MEDLINE and Cochrane databases from 2000 until June 2020 to identify studies that have analyzed the use of ADM alone. We then extracted relevant data's from the studies that met the inclusion criteria.

Results: Out of an initial 116 published studies retrieved 20 studies involving 126 patients who underwent chest wall reconstruction with ADM matched our inclusion criteria and were included in the analysis. The total complication rate was 19.0%. The most common complications were local infections 7.1%, postoperative hematoma and seroma 5.5%, followed by few other complications including 2 wound breakdowns, 2 distal flap necrosis without ADM exposure, 2 pleural effusions, 2 postoperative pneumonias and 1 case of Cerebrospinal Fluid (CSF) leak due to dural tear.

Conclusion: ADM appears to be a safe option for reconstructing the chest wall. The array of new products on the market calls for evaluation of their effectiveness in prospective as well as cost-effectiveness studies to determine how these costly products might be incorporated into treatment algorithms.

Keywords: Chest wall; Thoracic wall; Reconstruction; Biologic mesh; Dermal matrix; Artificial dermis

OPEN ACCESS

Correspondence:
François Lescarbotte, Department of Plastic, Reconstructive, Aesthetic and Maxillofacial Surgery, Henri Mondor University Hospital, 51, avenue du Maréchal de Lattre de Tassigny, 94000 Créteil, France, Tel: 33 149812533; Fax: 33 149812532; E-mail: francois.lescarbotte@gmail.com

Received Date: *02 Aug 2020*
Accepted Date*: 05 Sep 2020*
Published Date*: 09 Sep 2020*

Citation:
Lescarbotte F, Hersant B, Billon R, Habibi K, Hermeziu O, Meningaud J-P, et al. The Use of Acellular Dermal Matrix for Chest Wall Reconstruction: A Systematic Review. Ann Plast Reconstr Surg. 2020; 4(4): 1064.

Introduction

Full-thickness chest wall resection is indicated for a number of conditions, including cancer, infection, radiation therapy, trauma, and congenital defects. Chest wall reconstruction is required following the procedure to ensure protection of the intra thoracic organs and good respiratory function. Surgeons can now choose from a variety of techniques and materials - biologic, synthetic, and metallic - to restore chest wall integrity and stability [1]. The characteristics of these materials vary and are regularly modified by manufacturers to improve tolerability, mechanical properties, and elasticity. These continuous developments make it difficult to evaluate the clinical effectiveness of the various products available. Several authors have developed treatment algorithms to guide the choice of surgical technique for chest wall reconstruction after full-thickness resection [2-4], but faced with a wide range of materials, surgeons often choose a prosthesis with which they are familiar [2].

Acellular Dermal Matrices (ADM) were approved for use in thoracic surgery following their success in abdominal wall surgery and other fields of surgery, but the experience of the effectiveness in this new setting has been limited to a few single cases and small series [5,6]. ADM is derived from human donors or animals in a process that preserves the extracellular matrix to a greater or lesser extent [7]. Once implanted, the graft becomes progressively revascularized and remodeled into autologous tissue [7,8] without losing its mechanical structure [8].

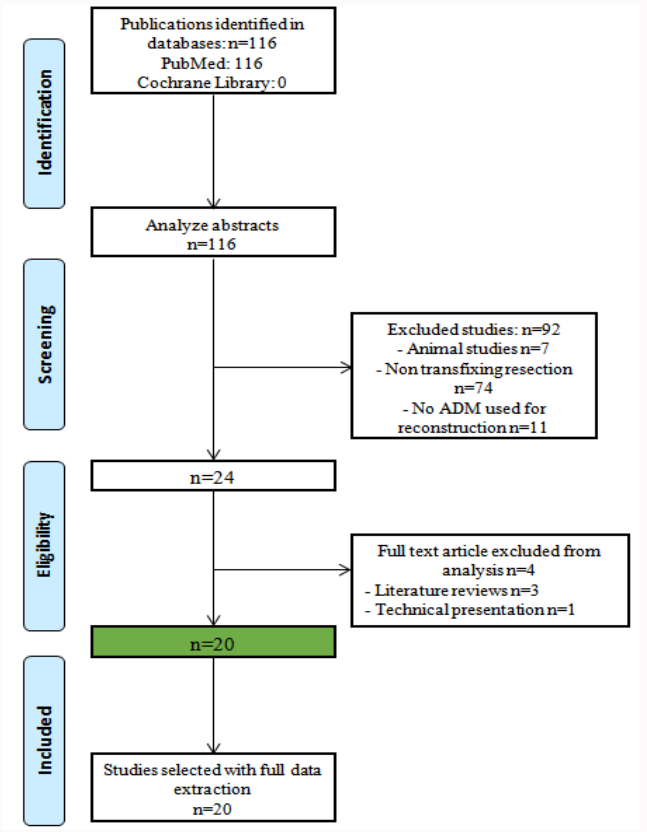

Figure 1: Flowchart showing inclusion and exclusion of articles.

Compared with synthetic meshes, ADM has been found to offer greater resistance to bacterial infection [9,10] and also appears to be better tolerated thanks to its progressive incorporation into vascularized tissue [8]. Its advantages and drawbacks have been analyzed in several series [11,12], but the number of patients studied remains small. New biomaterials are costly, and it is therefore essential to carefully evaluate their effectiveness in clinical practice before recommending wider-scale use or including them in treatment algorithms.

We therefore performed a systematic review to investigate the complication rates of ADM in chest wall reconstruction.

Materials and Methods

We performed a literature search in MEDLINE and the Cochrane Database of Systematic Reviews. Search terms referring exclusively to the use of ADM (e.g., biologic mesh and artificial dermis/dermal or dermal matrix) were applied to identify studies that have analyzed the use of these products. We searched for studies published in English from 2000 until June 2020, including all level of evidence according to the CEBM classification.

The search was further refined through keywords related to chest wall resection and reconstruction. The search algorithm was as follows:

((artificial dermal) OR (biologic mesh) OR (dermal matrix) OR (artificial dermis) OR (acellular dermis)) AND ((thoracic wall reconstruction) OR (thoracic reconstruction) OR (chest wall) OR (thoracic repair)). (See Appendix 1 for full list of search terms.) The inclusion criteria were: 1) studies of patients who underwent full-thickness chest wall resection and 2) studies of patients who underwent chest wall reconstruction with ADM alone. The exclusion criteria were 1) studies of patients who underwent a less than full-thickness chest wall resection and 2) animal model studies.

All the articles selected for full-text review were read twice by two surgeons working separately who extracted all relevant information.

Studies selected for inclusion were analyzed using the PRISMA (Preferred Reporting Items for Systematic Reviews and Meta-Analysis) checklist (Appendix 2) and classified according to their level of evidence, assessed using the Oxford Centre for Evidence-Based Medicine (CEBM) criteria. Data extracted were the occurring of any type of complications during follow-up.

The main outcome of interest was the rate of all types of surgical and medical complications reported. Other variables extracted were duration of follow-up, defect size prior to reconstruction, indications, chest wall stability after surgery and rate of local and systemic postoperative infections.

Results

The literature search retrieved 116 articles, 20 of which were included in our study (Figure 1). Seventy-four articles (80.4%) were excluded because the patients had not undergone a full-thickness resection, seven (7.6%) because they were animal studies, and 11 (12%) because ADM was not used. An additional four studies - three literature reviews (13.6%) [1,13,14] and a descriptive study of chest wall reconstruction techniques (4.5%) [15] - were excluded because they did not report relevant outcomes [1,13-15].

Eleven of the 20 studies included in the systematic review were retrospective case series [5,6,9,16-24,] and the other nine were case reports [9,25-33] (Table 1). All studies were classified with a CEBM level of evidence IV. Overall, 126 patients underwent chest wall reconstruction with ADM used alone or in conjunction with another prosthesis following full-thickness chest wall resection. The population consisted of 77 females (61.1%) and 49 males (38.9%) with a mean age of 45.8 years (range, 1 month to 76 years).

Not all the studies specified the type or brand of ADM used. The brands mentioned were Strattice (Allergan) (30 cases, 24%), Surgimend (Integra) (25 cases, 20%), AlloDerm (Bio Horizons) (17 cases, 13%), Permacol (Medtronic) (12 cases, 10%), Protexa (AFS) (11 cases, 9%), and Biodesign (Cook Medical) (8 cases, 6%).

The surgical technique consisted of anchoring the mesh to the ribs using single-tied non absorbable polyethylene sutures or screw anchors. Muscle and soft-tissue coverage was achieved using a local myocutaneous flap (bilateral pectoral is muscle flap or latissimus dorsi muscle flap in most cases) or by direct closure if the defect was small [6,21]. ADM was used alone in all 126 patients.

The rate of all types of surgical and medical complications was 19.0% (24 cases of 126 patients). The most common complications were local infections (9 cases, 7.1%), postoperative hematoma and seroma (7 cases, 5.5%). These were followed by few other complications including 2 cases of wound breakdown, 2 cases of distal flap necrosis without ADM exposure, 2 cases of pleural effusion, 2 cases of postoperative pneumonia [21,22], and 1 case of Cerebrospinal Fluid (CSF) leak due to dural tear [9] (Table 2).

In the study by Ge et al. [22], three of the nine patients who underwent chest wall reconstruction with ADM (Flex HD in two

Table 1: Specifications of included studies.

Title of study	Author	Year	Study Type	*n*	Mean age, y	Indications
Synthetic Mesh Versus Acellular Dermal Matrix for Oncologic Chest Wall Reconstruction: A Comparative Analysis	GIORDANO	2020	Retrospective series	51	51,7	Oncologic
Primary pediatric chest wall tumors necessitating surgical management	MAISTRY	2020	Retrospective series	8	4,4	5 Sarcomas 2 Lipoblastomas 1 Myofibroma
Chest wall reconstruction with porcine acellular dermal matrix (strattice) and autologous tissue transfer for high risk patients with chest wall tumors.	KHALIL	2018	Retrospective series	8	50	7 Sarcomas 1 Breast cancer
Reoperation 7 years after sternal reconstruction with a porcine acellular dermal matrix.	V.N SHAH	2018	Case report	1	73	Infection
Complex sternal and rib reconstruction with allogeneic material	MALISKA	2018	Case Report	1	62	Chronic sternal instability
Reconstruction of congenital sternal clefts: Surgical experience and literature review.	ALSHOMER	2017	Case report	1	3 mo	Sternal cleft
Reconstruction of the thoracic wall with biologic mesh after resection for chest wall tumors: A presentation of a case series and original technique.	D'AMICO	2017	Retrospective series	11	60	8 Sarcomas 1 Breast cancer 1 Schwannoma 1 Mesothelioma
A case of "en bloc" excision of a chest wall leiomyosarcoma and closure of the defect with non-cross-linked collagen matrix (Egis®).	RASTRELLI	2016	Case report	1	50	Sarcoma
Non-cross-linked porcine acellular dermal matrix (Strattice Tissue Matrix) in pediatric reconstructive surgery.	BEGUM	2016	Retrospective series	2	16	2 Sarcomas
Chest wall reconstruction: Evolution over a decade and experience with a novel technique for complex defects.	AZOURY	2016	Retrospective series	10	60	8 Tumors 1 Desmoid tumors 1 Other
Thoracic wall reconstruction with acellular porcine dermal collagen matrix.	SCHMIDT	2016	Retrospective series	6	46	6 Sarcomas
Major chest wall resection for the treatment of invasive breast carcinoma: A series of 33 patient	AL AMERI	2013	Retrospective series	4	55	Breast cancer
Chest wall reconstruction with acellular dermal matrix (Strattice(™)) and a TRAM flap.	BRUNBJERG	2012	Case report	1	69	Breast cancer
Chest wall reconstruction using implantable cross-linked porcine dermal collagen matrix (Permacol).	LIN	2012	Retrospective series	5	15.5	3 Sarcomas 2 PNETs
The combination of polytetrafluoroethylene mesh and titanium rib implants: An innovative process for reconstructing large full thickness chest wall defects.	BERTHET	2011	Retrospective series	1	59	NSCLC
Chest wall reconstruction with strattice in an immunosuppressed patient.	KAPLAN	2011	Case Report	1	26	Cardiac paraganglioma
Chest wall reconstruction with porcine acellular dermal matrix (strattice) and a latissimus myocutaneous flap.	HUSTON	2011	Case Report	1	61	Breast cancer
The use of human acellular dermal matrix for chest wall reconstruction.	GE	2010	Retrospective series	9	48	4 Sarcomas 2 NSCLCs 3 Infections
The use of Permacol® for chest wall reconstruction in a case of desmoid tumour resection.	MIRZABEIGI	2010	Case Report	1	39	Desmoid tumor
Pelvic, abdominal, and chest wall reconstruction with AlloDerm in patients at increased risk for mesh-related complications.	BUTLER	2005	Retrospective series	2	41.5	1 Sarcoma 1 histiocytoma
Chest wall reconstruction with acellular dermal matrix (AlloDerm) and a latissimus muscle flap.	COTHREN	2004	Case Report	1	61	Sarcoma

NSCLC: Non-Small-Cell Lung Cancer; PNET: Primitive Neuroectodermal Tumor

patients and AlloDerm in two) developed a seroma within 30 days of surgery. All the seromas resolved satisfactorily in spite of one becomes infected.

Khalil et al. [5] described two postoperative complications in their series of eight patients treated with Strattice: One patient had wound breakdown and one patient developed superficial distal flap necrosis 14 days after treatment without exposure of the ADM mesh.

D'Amico et al. [21] reported five complications in 11 patients treated with Protexa [21]: Three cases of wound healing difficulty due to postoperative hematoma, one case of pneumonia, and one case of atrial fibrillation. Two-year mortality was 27.2%: One patient died of cancer recurrence, one of myocardial infarction, and one of sepsis secondary to chemotherapy.

Azoury et al. [18] did not specify whether local complications other than abscesses were associated with synthetic meshes used alone or in combination with ADM, but reported only one local complication on the 10 patients who had been reconstructed using only ADM.

Lin et al. [23] described two complications (a catheter infection and a seroma that required drainage by an interventional radiologist)

Table 2: Results of the included studies.

Author	n	Material/closure technique	Follow-up	Mean Defect size, cm²	Complications
GIORDANO	51	17 Strattice, 24 Surgimend, 10 Alloderm	17,2 mo	183,1	8 (15%, 7%)
					-7 Local infection
					-2 Seroma
					-1 Pneumothorax
					-2 Pleural effusion
					-1 Skin necrosis
					-1 Pneumonia
MAISTRY	8	8 Biodesign	3,6 y		1 (12%, 5%)
KHALIL	8	Strattice. MSTRAM (n=4), TFL (n=1), LDM (n=3)	9-52 mo	511	2 (25%)
					- 1 Wound breakdown
					-1 Distal lap nerosis
SHAH	1	Strattice. PMM	1 mo	450	0 (0%)
ALSHOMER	1	Surgimend. PMM	6 mo		0 (0%)
D'AMICO	11	Protexa. PMM (n=2), LDM (n=9)	0.75 to 5.13 y	171.5	5 (40.9%)
					- 1 Atrial ibrillation
					- 1 Pneumonia
					- 2 Hematomas
					- 1 Local infection
RASTRELLI	1	Egis.	4 mo	80	0 (0%)
BEGUM	2	Brand not specified. Direct closure	28.5 mo	150	0 (0%)
AZOURY	10	Brand not specified.	96.5 to 767.5 d	143	1 (10%)
SCHMIDT	6	Permacol. LDM (n=1), PMM (n=1), directclosure (n=4)	8 to 42 mo	149	0 (0%)
AL AMERI	4	Integra	NA	NA	1 Local infection
BRUNBJERG	1	Strattice. TRAM	18 d	160	0 (0%)
LIN	5	Permacol	1.1 to 2.6 y	390	2 (40%)
					- 1 Seroma
					- 1 Catheter sepsis
BERTHET	1	XCM. PMM		108	0 (0%)
GE	9	AlloDerm (n=4), Flex HD (n=5)	4 mo to 3 y		4 (44.4%)
					- 2 Seromas
					- 1 Pneumonia
					- 1 Wound breakdown
MIRZABEIGI	1	Permacol. PMM		40	0 (0%)
BUTLER	2	AlloDerm. LDM (n=4), serratus muscle (n=1) ALT (n=1)	2 to 13 mo	324	1 (50%)
COTHREN	1	Alloderm. LDM	9 mo	400	0 (0%)
MALISKA	1	No brand specified. Donor sternum + ADSVF cells + ADM + TRAM + PMM	2 y		0 (0%)
KAPLAN	1	Strattice. PMM	14 mo	100	0 (0%)
HUSTON	1	Strattice. LDM		135	0 (0%)

ADM: Acellular Dermal Matrix; ALT: Antero Lateral Thighflap; ADSVF: Adipose-Derived Stromal Vascular Fraction; LDM: Latissimum Dorsi Muscleflap; MSTRAM: Muscle-Sparing Transverse Abdominis Myocutaneous flap; PMM: Pectoralis Major Muscle Flap; TFL: Tensor Fasciae Latae; TRAM: Transverse Rectus Abdominis Musculocutaneous Flap

in a series of five patients who underwent chest wall reconstruction with Permacol.

Butler et al. [9] reported just one type of complication (CSF leak due to dural tear after spinal resection) in two patients who underwent trunk reconstruction with AlloDerm and who subsequently required percutaneous drainage.

Maistry et al. [17] only reported one case of transient paresis of the upper left abdominal wall following chest wall resection and reconstruction on the 8 patients. Complete recovery was noted two years after surgery. There was no postoperative wound or graft infection.

Giordano et al. [16] noted 8 complications on 51 patients reconstructed with ADM. There were 7 surgical site infections, 1 pneumothorax, 2 pleural effusion, 2 seromas and 1 skin necrosis.

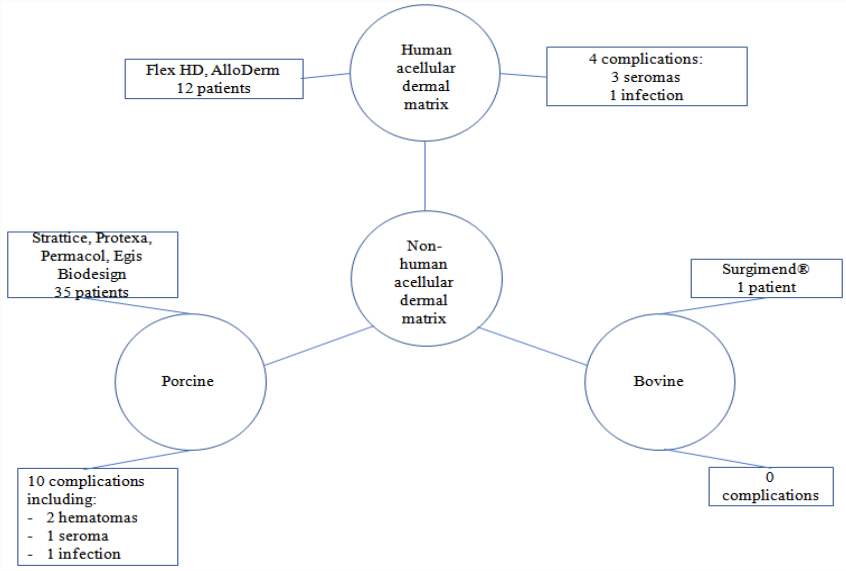

Figure 2: Breakdown of patients and complication rate according to type of acellular dermal matrix used, when mentioned.

This retrospective study analyzed and compared 146 patients who underwent chest wall reconstruction using either ADM alone (n=51) or synthetic mesh (n=95).

No complications were reported in the other studies, which accounted for 80.9% of the patients included in this analysis.

Regarding infectious complications, in the study by Azoury et al. [18], two patients who underwent chest wall reconstruction with ADM and a synthetic mesh and five patients who underwent reconstruction with a synthetic mesh only developed an abscess in the follow-up period. The mesh had to be surgically removed in four of the five patients in the synthetic group (80%) but in neither of the patients in the combined ADM/synthetic group. The overall complication rates described by Azoury et al. [18] for the three groups of patients they compared were: 10% for the ADM only group; 22% for the synthetic group; and 31.8% for the combined ADM/synthetic group (p=0.47). D'Amico et al. [21] described a wound infection in one patient, but this resolved and had no impact on healing outcome. Ge et al. [22] described one case of pneumonia without surgical site infection and one of wound seroma that became infected but healed well after drainage.

Giordano et al. [16] noted 7 cases of postoperative surgical site infection, 4 cellulitis and 3 abscesses. Two of the biologic meshes had to be removed (4%). The mean defect size for the overall group was 253.1 cm^2.

Mean follow-up for the 20 studies was 16, 7 months (range, 0.6 to 52 months). In the case reported by Shah et al. [30], the follow-up time was just 1 month, but it consisted of a second coronary artery bypass procedure in a patient 7 years after sternal reconstruction by Strattice for a previous coronary artery bypass.

The main indications for chest wall resection were cancer in 106 patients (84.1%), infection in 5 (3.9%), sternal instability and sternal cleft in two (1.6%).

Most studies reported good chest wall stability immediately after surgery [6,21-23,26,33], but only 12 of the 20 studies reported stability outcomes at the end of follow-up. In the larger series, Giordano et al. [16] did not detect any paradoxical chest wall motion among the two analyzed groups. And D'Amico et al. [21] described excellent stability in 90% of patients and good stability in 10%. The latter study also reported that 81% of the patients felt that the operation had improved their quality of life.

Azoury et al. [18] reported no cases of paradoxical respiratory compromise in patients who underwent chest wall reconstruction with ADM alone and Ge et al. [22] reported no cases of instability, hernia, or paradoxical wall movement at the end of follow-up in their series.

Discussion

The findings of this systematic review of studies analyzing chest wall reconstruction with ADM spanning a period of 16 years shows that this biomaterial, used alone, is associated with an overall surgical and medical complications rate of 19.0% and a local infection rate of 7.1%, which seems safer than another option such as synthetic mesh only reconstructions, reported with 32% complications rate in the same studies [16,18]. Complications were identified on the principle of maximum bias: All medical and surgical complications from literature, such as the occurrence of atrial fibrillation, have been identified. And the overall complications rate still seems lower compared to the synthetic mesh reconstruction option. Even when a major complication occurs the reduced adhesions noticed with the use of the biologic ADM [8,16,34] could be beneficial in case of surgical revision.

The main indications for resection in the studies analyzed were cancer, infection, radiation therapy, trauma, and congenital defects. Few studies to date have analyzed complications in this setting, and none have analyzed data prospectively or using a randomized study design. Complications and infections in particular can have a devastating effect on inert prostheses and a repeat operation is often required to remove the damaged product [34].

Most of the complications described in the studies analyzed resolved rapidly and had no effect on chest wall stability. Good stability was reported at the end of follow-up in most of the studies analyzed.

A range of ADM materials were used (human, porcine, and fetal bovine) (Figure 2). Choice of material does not appear to be linked to specific complications. Proven risk factors for complications are number of ribs resected, tobacco use, and patient age [10].

Mean defect size in the 20 studies reviewed is similar to sizes described for chest wall reconstruction using synthetic meshes [2]. In their retrospective study of chest wall reconstructions, Azoury et al. [18] reported that ADM was typically used for small defects, while synthetic meshes were preferred for large defects but in their series defect size was similar in patients who underwent reconstruction with ADM and with a synthetic mesh. The relatively short follow-up time (mean, 16.7 months) makes it difficult to assess long-term chest wall stability [33].

Reconstruction methods varied across studies, with some surgeons using ADM only and others opting for ADM combined with a synthetic mesh. We only included cases in which only ADM was used. Most of the series used ADM only [6,9,19-21]. Azoury et al. [18], on comparing the use of ADM alone, synthetic meshes alone, and ADM and synthetic meshes combined found no significant differences in complication rates. Giordano et al. [16] compared two groups, one in which only ADM was used and the other using only synthetic meshes. The patients in the SM group experienced a significantly higher rate of surgical site complications (32.6% *vs.* 15.7%; p=0.027). Both groups experienced similar rates of surgical site infections. Overall, the incidence of cardiopulmonary complications, including pneumonia, was similar among the groups. No differences were observed in the 90-day mortality rate. The reoperation rates for either management of complications or tumor recurrences were similar between the groups. Most of the ADM infections or exposures did not require mesh removal.

It should, however, be noted that comparisons of outcomes will have been skewed by the few studies analyzed, the small number of patients studied, and the short follow-up periods precluding evaluation of late complications. Furthermore, most of the studies were case reports, none of which described complications, which might also constitute publication bias. Not all the studies reported long-term stability whereas this outcome measure may have provided a more objective indicator of the true effectiveness of ADM than complication rates. Nevertheless, our report analyzed studies from a variety of centers over 16 years and thus provides an important overview of the use of ADM for chest wall reconstruction whether used alone or with other materials. Future prospective randomized studies should generate data that can be statistically analyzed to determine the real effectiveness of ADMs and position them in the decision-making algorithm.

Conclusion

Chest wall reconstruction after full-thickness resection is technically challenging, but surgeons now have access to a wide range of biologic and synthetic prostheses. ADM appears to be a safe option for reconstructing the chest wall and achieving mechanical stability, particularly in complex cases. The array of new products on the market calls for evaluation of their effectiveness in prospective studies as well as cost-effectiveness studies to determine how these costly products might be incorporated into treatment algorithms.

References

1. Sanna S, Brandolini J, Pardolesi A, Argnani D, Mengozzi M, Dell'Amore A, et al. Materials and techniques in chest wall reconstruction: A review. J Vis Surg. 2017;3:95-5.
2. Bosc R, Lepage C, Hamou C, Matar N, Benjoar MD, Hivelin M, et al. Management of chest wall reconstruction after resection for cancer: A retrospective study of 22 consecutive patients. Ann Plast Surg. 2011;67(3):263-8.
3. Lardinois D, Müller M, Furrer M, Bannic A, Gugger M, Krueger T, et al. Functional assessment of chest wall integrity after methylmethacrylate reconstruction. Ann Thorac Surg. 2000;69(3):919-23.
4. Mouton W, Lardinois D, Furrer M, Regli B, Ris H. Long-term follow-up of patients with operative stabilisation of a flail chest. Thorac Cardiovasc Surg.1997;45(5):242-4.
5. Khalil HH, Kalkat M, Malahias MN, Rhobaye S, Ashour T, Djearaman M, et al. Chest wall reconstruction with porcine acellular dermal matrix (strattice) and autologous tissue transfer for high risk patients with chest wall tumors. Plast Reconstr Surg Glob Open. 2018;6(5):e1703.
6. Schmidt J, Redwan B, Koesek V, Heitplatz B, Bedetti B, Aebert H, et al. Thoracic wall reconstruction with acellular porcine dermal collagen matrix. Thorac Cardiovasc Surg. 2014;64(3):245-51.
7. Eppley BL. Experimental assessment of the revascularization of acellular human dermis for soft-tissue augmentation. Plast Reconstr Surg. 2001;107(3):757-62.
8. Holton LH, Chung T, Silverman RP,Haerian H, Goldberg N, Burrows W, et al. Comparison of acellular dermal matrix and synthetic mesh for lateral chest wall reconstruction in a rabbit model. Plast Reconstr Surg. 2007;119(4):1238-46.
9. Butler CE, Langstein HN, Kronowitz SJ. Pelvic, abdominal, and chest wall reconstruction with alloderm in patients at increased risk for mesh-related complications. Plast Reconstr Surg. 2005;116(5):1263-75.
10. Weyant MJ, Bains MS, Venkatraman E, Downey R, Park B, Flores R, et al. Results of chest wall resection and reconstruction with and without rigid prosthesis. Ann Thorac Surg. 2006;81(1):279-85.
11. Gruber-Blum S, Brand J, Keibl C, Fortelny R, Redl H, Mayer F, et al. Abdominal wall reinforcement: Biologic *vs.* degradable synthetic devices. Hernia. 2017;21(2):305-15.
12. Lak KL, Goldblatt MI. Mesh selection in abdominal wall reconstruction: Plast Reconstr Surg. 2018;142(3 Suppl):99S-106S.
13. Banyard DA, Bourgeois JM, Widgerow AD, Evans GRD. Regenerative biomaterials: A Review. Plast Reconstr Surg. 2015;135(6):1740-8.
14. Shah N, Ayyala H, Tran B, Therattil P, Keith J. Outcomes in chest wall reconstruction using methyl methacrylate prostheses: A review of the literature and case series utilizing a novel approach with biologic mesh. J Reconstr Microsurg. 2019;35(8):575-86.
15. Thomas PA, Brouchet L. Prosthetic reconstruction of the chest wall. Thorac Surg Clin. 2010;20(4):551-8.
16. Giordano S, Garvey PB, Clemens MW, Baumann D, Selber J, Rice D, et al. Synthetic mesh versus acellular dermal matrix for oncologic chest wall reconstruction: A comparative analysis. Ann Surg Oncol. 2020;27(8):3009-3017.
17. Maistry N, Durell J, Wilson S, Lakhoo K. Primary paediatric chest wall tumours necessitating surgical management. Ann R Coll Surg Engl. 2020;102(5):335-9.
18. Azoury SC, Grimm JC, Tuffaha SH, Broyles J, Fischer A, Yang S, et al. Chest wall reconstruction: evolution over a decade and experience with a novel technique for complex defects. Ann Plast Surg. 2016;76(2):231-7.
19. Begum T, Farrelly PJ, Craigie RJ. Non-cross-linked porcine acellular dermal matrix (Strattice Tissue Matrix) in pediatric reconstructive surgery. J Pediatr Surg. 2016;51(3):461-4.

20. Berthet JP, Wihlm JM, Canaud L, Joyeux F, Cosma C, Hireche K, et al. The combination of polytetrafluoroethylene mesh and titanium rib implants: An innovative process for reconstructing large full thickness chest wall defects. Eur J Cardiothorac Surg. 2012;42(3):444-53.

21. D'Amico G, Manfredi R, Nita G, Poletti P, Milesi L, Livraghi L, et al. reconstruction of the thoracic wall with biologic mesh after resection for chest wall tumors: A presentation of a case series and original technique. Surg Innov. 2018;25(1):28-36.

22. Ge PS, Imai TA, Aboulian A, Van Natta TL. The use of human acellular dermal matrix for chest wall reconstruction. Ann Thorac Surg. 2010;90:1799-804.

23. Lin SR, Kastenberg ZJ, Bruzoni M, Albanese CT, Dutta S. Chest wall reconstruction using implantable cross-linked porcine dermal collagen matrix (Permacol). J Pediatr Surg. 2012;47(7):1472-5.

24. Al Ameri O, Chaouat M, Marco O, Azoulay B, Hersant B, Mimoun M. Major chest wall resection for the treatment of invasive breast carcinoma: A series of 33 patients. Ann Chir Plast Esthet. 2014;59(2):115-22.

25. Alshomer F, Aldaghri F, Alohaideb N, Aljehani R, Murad MA, Hashem F. Reconstruction of congenital sternal clefts: Surgical experience and literature review. Plast Reconstr Surg Glob Open. 2017;5(11):e1567.

26. Brunbjerg ME, Juhl AA, Damsgaard TE. Chest wall reconstruction with acellular dermal matrix (Strattice™) and a TRAM flap. Acta Oncol. 2013;52(5):1052-4.

27. Cothren. Chest wall reconstruction with acellular dermal matrix (AlloDerm) and a latissimus muscle flap. Plast Reconstr Surg. 2004;114(4):1005-6.

28. Huston TL, Taback B, Rohde CH. Chest wall reconstruction with porcine acellular dermal matrix (strattice) and a latissimus myocutaneous flap. Am Surg. 2011;77(6):e115-6.

29. Kaplan KM, Chopra K, Feiner J, Gastman BR. Chest wall reconstruction with strattice in an immunosuppressed patient. Eplasty. 2011;11:e46.

30. Maliska III CM, Archer RL, Tarpley SK, Miller III AS. Complex sternal and rib reconstruction with allogeneic material. Arch Plast Surg. 2018;45(6):593-7.

31. Mirzabeigi MN, Moore JH, Tuma GA. The use of Permacol® for chest wall reconstruction in a case of desmoid tumour resection. J Plast Reconstr Aesthet Surg. 2011;64(3):406-8.

32. Rastrelli M, Tropea S, Spina R, Costa A, Stramare R, Mocellin S, et al. A case of "en bloc" excision of a chest wall leiomyosarcoma and closure of the defect with non-cross-linked collagen matrix (Egis®). Case Rep Oncol. 2016;9(3):655-60.

33. Shah VN, Orlov O, Hoffman R, Plestis K. Reoperation 7 years after sternal reconstruction with a porcine acellular dermal matrix. Eur J Cardiothorac Surg. 2018;54(3):601-3.

34. Sodha NR, Azoury SC, Sciortino C, Sacks JM, Yang SC. The use of acellular dermal matrices in chest wall reconstruction. Plast Reconstr Surg. 2012;130(5 Suppl 2):175S-182S.

35. Butler CE, Prieto VG. Reduction of adhesions with composite AlloDerm/polypropylene mesh implants for abdominal wall reconstruction. Plast Reconstr Surg. 2004;114(2):464-73.