Annals of Orthopedic Surgery Research

Research Article
Published: 25 Feb, 2019

The Results of Treatment with Percutan Iliosacral Screw in Posterior Ring Injuries of Pelvis and the New Method for Measuring Inlet-Outlet Angle

Mehmet Bulut[1], Fırat Tantekin M[1], Serdar Yalvaç E[2], Onur Ziyadanoğulları M[3], Murat Gürger[4], Akif Çaçan M[5] and Emin Özkul[1]*

[1]Department of Orthopaedics and Traumatology, Dicle University, Turkey

[2]Department of Orthopaedics and Traumatology, Yozgat Boğazlıyan State Hospital, Turkey

[3]Department of Orthopaedics and Traumatology, Diyarbakır Çermik State Hospital, Turkey

[4]Department of Orthopaedics and Traumatology, Fırat University, Turkey

[5]Department of Orthopaedics and Traumatology, Medipol School of Medicine, Turkey

Abstract

Purpose: In this study, we evaluated the radiological and functional results of the patients treated with iliosacral screw in the unstable posterior ring injuries of the pelvis and the factors affecting the results.

Materials and Methods: 43 patients, who were treated due to instable posterior ring injury of the pelvis in Dicle University, Faculty of Medicine, Department of Orthopedics and Traumatology between 2014 and 2017, were evaluated retrospectively. 38 patients with adequate clinical and radiological follow-ups were included in the study. Reduction maneuvers were performed before fixation. The inlet and outlet angles were calculated for all cases in the sagittal plane of Computed Tomography (CT). Radiological evaluation of the patients was performed by preoperative and postoperative computed tomography, pelvic anterior-posterior and inlet images according to Henderson's descriptions, and evaluation of the functional results according to Majeed scoring.

Results: 26 (68.4%) of the cases were male and 12 (31.6%) were female, mean age was 33.7 (15-68) years, mean follow-up time was 36.5 (12-58) months. 28 (73.7%) of the patients were Tile Type B and 10 (26.3%) were Tile Type C. The average time between injury and surgery was 2.5 (1-10) days. A total of 54 screws were used in 36 patients. The mean preoperative vertical displacement was 4.87 ± 3.2 (0-14.4) mm preoperatively, 2.16 ± 1.94 (0-8) in postoperative early period, and 2.17 ± 2.11 (0-9) at the last follow-up. The mean anteroposterior displacement was 7.02 ± 2.84 (3-14) mm preoperatively, 2.94 ± 2.39 (0-8) in postoperative early period and 3.03 ± 2.43 (0-8) at the last follow-up. The mean Majed functional score at the final follow-up was 84.7 ± 10.5 (56-97). The results were excellent in 22 (57.8%) patients, good in 12 (31.5%) and moderate in 4 (10.5%) patients. Age, gender, additional fracture and organ pathology did not affect the number of screws used and the functional and radiological results (p>0.05).

Conclusion: Iliosacral screw application is a method, in which radiological and functional results are good and complications are low, and can be applied in early period, especially in hemodynamically unstable patients. The most important points of the method are the reduction before the fixation and the taking inlet-outlet images at the right angles.

Keywords: Pelvis injury; Posterior ring; Instability; Inlet-outlet image; Iliosacral screw

OPEN ACCESS

Correspondence:
Mehmet Bulut, Department of Orthopaedics and Traumatology, Dicle University, Turkey,
E-mail: bulmeh@yahoo.com

Received Date: *01 Feb 2019*
Accepted Date*: 22 Feb 2019*
Published Date*: 25 Feb 2019*

Citation:
Bulut M, Fırat Tantekin M, Serdar Yalvaç E, Onur Ziyadanoğulları M, Gürger M, Akif Çaçan M, et al. The Results of Treatment with Percutan Iliosacral Screw in Posterior Ring Injuries of Pelvis and the New Method for Measuring Inlet-Outlet Angle. Ann Orthop Surg Res. 2019; 2(1): 1006.

Introduction

Pelvic fractures account for 3% of all fractures and 40% of these fractures consist of an unstable posterior pelvis injury. Mortality rates in pelvic fractures are high and approximately 28%. This rate is 50% in open fractures [1,2].

The most common etiological cause is traffic accidents with 60%, fall from height and crush injuries with 30% [3]. While stable fractures are treated conservatively, the treatment of unstable fractures varies according to the fracture types and the presence of additional injuries. In the cases

Figure 1: a. Postopo. pelvis anterior-posterior (a-p) graph **b.** Postop outlet graph **c.** Image of 2 iliosacral screws sent to S1 at postop CT **d.** Vertical displacement measurement in postop. a-pradiography **e.** A-p displacement measurement in postoperative inlet radiography **f.** Image of iliosacral screw sent to S2 at Postop CT.

requiring surgical treatment, more open reduction and recon plate stabilization were used in the previous years. Due to the high risk of wound problems, infections and bleeding, closed reduction and percutaneous iliosacral screw fixation have become prominent. In addition, the fact that it can also be applied safely in patients with polytrauma and posterior skin problems and that it does not bring an additional trauma load as much as open reduction, is the other advantages of iliosacral screw. In order to achieve a successful outcome in the treatment with iliosacral screw; providing reduction before fixation and getting the inlet and outlet images with the right angles are the sine qua non of this method [3-6].

In this study, we evaluated pre-fixation reduction, inlet and outlet imaging at right angles, the factors affecting the results and the complications, in patients with unstable posterior ring injury of pelvis treated with iliosacral screw.

Materials and Method

Forty three patients, who were treated due to instable posterior ring injury of the pelvis in Dicle University, Faculty of Medicine, Department of Orthopedics and Traumatology between 2014 and 2017, were evaluated retrospectively. Thirty eight patients with adequate clinical and radiological follow-ups were included in the study. Ethics committee approval was obtained from the Ethics Committee of the Hospital dated 06 June 2018 and numbered 189 and "Informed Voluntary Consent Form" was obtained from all patients who participated in the study.

Of the cases; 26 (68.4%) were male and 12 (31.6%) were female with a mean age of 33.7 ± 14.49 (15-68) years. The trauma mechanisms included; 15 (39.5%) in-vehicle traffic accidents, 9 (23.7%) outer-vehicle traffic accidents, 8 (21.1%) falling from height, 3 (7.9%) motorcycle accident, 2 (5.3%) burying under wreckage and 1 (2.6%) falling from a horse.

According to Tile [6] classification; 28 (73.7%) of the patients were Type B and 10 (26.3%) were Type C. According to the Young-Burgess [7] classification; 2 (5.3%) had Apc 2, 17 (44.7%) had Apc 3, 5 (13.1%) had lateral compression 2, 4 (10.5%) had lateral compression 3, 6 (15.8%) had vertical shear, and 4 (10.5%) had combined injury.

Thirty (78.9%) patients had sacrum fractures and 28 (73.6%) had sacroiliac joint separation. Twenty (52.6%) patients had both sacrum fractures and sacroiliac joint separation. 10 (26.3%) of the patients with sacrum fractures were Denis zone 1, and 20 (52.6%) were Denis zone 2, 28 (73.7%) of the patients had a fracture in ischium-ramus pubis.

Twenty five (65.7%) patients had an additional organ and system pathology. The most common organ pathology was chest pathology and was present in 20 (52.6%) patients. The number of patients with more than one organ trauma was 16 (42.1%).

An additional orthopedic injury was present in 20 (52.6%) patients. The most common accompanying orthopedic injury was calcaneus fracture and was present in 6 (15.6%) patients. 9 (23.6%) patients had multiple orthopedic injuries.

Radiologic evaluation

The radiological evaluations of the patients were made with preoperative and postoperative pelvic anterior-posterior (a-p), inlet, outlet radiographs and Computed Tomography (CT). Preoperative sacroiliac, vertical and a-p displacements of the patients were measured in the pelvic a-p and inlet radiographs. A-p and vertical displacements were measured in preoperative, early postoperative and final radiographs as described by Henderson [8] (Figure 1). Symphysis pubis and sacroiliac separation were measured in preoperative and postoperative CTs.

The presence of dimorphism in the sacrum was evaluated by Graphy and CT. Sacral dimorphism was seen in 17 (44.7%) patients. In the preoperative CT, inlet and outlet angles were measured. While the inlet angle was being measured in the CT sagittal plane, the angle between the sagittal axis and the tangent line of the anterior cortex of S1 and S2 vertebrae was measured as the anterior inlet angle, and the angle between the sagittal axis and the tangent line of the posterior cortex of S1 and S2 vertebrae was measured as the posterior inlet angle. The average inlet angle was determined by taking the average of the anterior and posterior inlet angles. The outlet angle was determined by deducting the average inlet angle from 90 degrees (Figure 2). Functional results of the patients were evaluated by Majeed [9] scoring method.

Surgical treatment

35 (92.1%) of the patients were operated in the supine position and 3 (7.9%) of them were operated in the prone position in order to operate on the vertebrae. Internal rotation was applied to extremity on the same side in patients with external rotation type injury, and

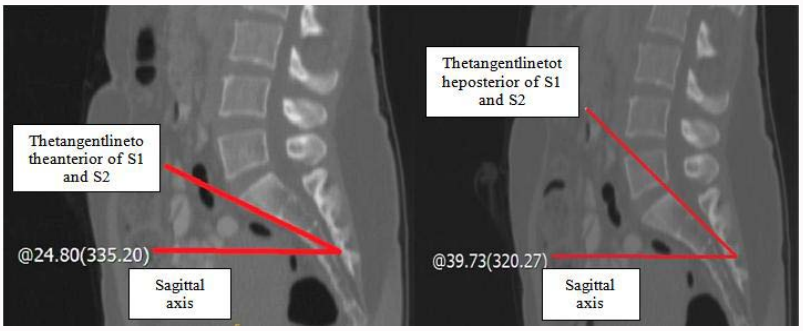

Figure 2: Measurement of the anterior inlet and posterior inlet angles in the ct sagittal plane.
Average inlet angle: 24.80°+39.73°/2=32.27°, Outlet angle: 90°-32.27°=57.73°.

Table 1: Comparison of radiological parameters according to the Tile classification.

Parameters (Displacement mm)	Tile Tip B 28 Patients Mean ± SD (min-max)	Tile Tip C 10 Patients Mean ± SD (min-max)	P Value
Preop. sacroiliac	7.73 ± 5.19(0-17)	7.87 ± 7.45(0-18.4)	P=0.949
Last control sacroiliac	2.47 ± 1.67(0-5.7)	2.62 ± 2.47(0-6)	P=0.838
Preoperative vertical	3.90 ± 2.75(0-13)	7.60 ± 2.89(0-14.4)	P=0.001
Early postoperative vertical	1.97 ± 2.11(0-6)	2.52 ± 1.91(0-8)	P=0.506
Last control vertical	2.05 ± 2.11(0-7)	2.7 ± 2.11(0-9)	P=0.361
Preoperative anterior-posterior	6.46 ± 2.23(3-12)	8.6 ± 3.80(3-14)	P=0.040
Early postoperative anterior-posterior	2.67 ± 2.29(0-8)	3.7 ± 2.62(0-8)	P=0.252
Last control anterior-posterior	2.76 ± 2.33(0-8)	3.8 ± 2.65(0-8)	P=0.260

external rotation was applied to those with lateral compression type injury. Traction was performed in patients with vertical displacement. In addition, for the reduction of the displacement of the hemipelvis in anterior-posterior plane, 2 schanz screws were passed through the iliac crest and reduction was attempted with gentle manipulation (Figure 3). External fixation was applied to patients with bilateral or segmented ischium-pubis ramus fracture, and open reduction and plate-screw fixation were performed in cases with more than 2.5 cm separated simphysispubis.

Patients who had unilateral fracture and had no additional problems were walked with crutches from day 3 onwards. Patients with additional fractures were given partial load from the 6th week and full load from 2.5 months to the fracture side. Patients were evaluated statistically in terms of gender, age, mean period before the operation duration of operation, presence of additional fractures and organ injuries, amount of preoperative displacement, type of fracture, number of screws and whether applying additional treatment had an effect on radiological and clinical outcomes or not.

Statistical evaluation was performed with SPSS 18.0 (SPSS Inc. Chicago, IL, USA). Kolmogorov Smirnov test was used to determine whether the distribution was normal or not. Student-t test (Independent Sample T test) was used to compare the parametric values of two independent groups. Mann Whitney U test was used to compare nonparametric values in two independent groups. Student-t test (Paired sample t test) was used to compare parametric values in two dependent groups and Wilcoxon test was used to compare nonparametric values in two dependent groups. In the comparison of categorical (nominal, ordinal) data, Chi-square test was used in two independent groups. Results with P<0.05 were considered significant.

Results

The mean period before the operation was 2.5 (1-10) days, the mean duration of operation was 106.2 (29-200) min and mean scopy number per screw was 29.9 (26-34). The mean duration of hospitalization was 10.7 (2-48) days and the mean follow-up period was 36.5 (12-58) months. The longest hospitalized patient was the patient, who had plate on the symphysis pubis and developed infection in this area in addition to the iliosacral screw treatment. Patient was treated with serial debridement and antibiotic, without plate removal.

The mean preoperative sacroiliac joint separation was 7.76 ± 5.76 (0-18.4) mm, and the mean last control sacroiliac separation was 2.51 ± 1.88 (0-6) mm. The difference was statistically significant (P<0.001). The mean vertical displacement was 4.87 ± 3.2 (0-14.4) mm preoperatively, 2.16 ± 1.94 mm (0-8) at the postoperative early period, and 2.17 ± 2.11 (0-9) mm at the last follow-up. Anteroposterior displacement was measured as 7.02 ± 2.84 (3-14) mm preoperatively, 2.94 ± 2.39 (0-8) mm at the postoperative early period and 3.03 ± 2.43 (0-8) mm at the last follow-up. Preoperative vertical and anteroposterior displacement and postoperative early vertical and anterior-posterior displacement were statistically significantly different (P<0.001). There was no significant difference between vertical and anterior-posterior displacement amounts in early postoperative period and the last follow-up (P=0.684) (P=0.067).

Postoperative late period anterior-posterior displacement was 5 mm or less in 31 (81.6%) and vertical displacement was in 33 (86.8) cases. The amounts of displacement in other cases were between 5 mm to 10 mm.

The mean Majeed score was 84.7 ± 10.5 (56-97). The results were evaluated as excellent in 22 (57.8%) patients, good in 12 (31.5%) and

Table 2: Comparison of radiological parameters according to the Majeed score.

Parameters (Displacement mm)	Majeed skoru ≥ 85 22 patients Mean ± SD (min-max)	Majeed skoru <85 16 patients Mean ± SD (min-max)	P Value
Preop. sacroiliac	6.78 ± 5.01(0-18.4)	8.86 ± 6.47(0-17)	P=0.274
Last control sacroiliac	2.42 ± 1.9(0-6)	2.61 ± 1.9(0-6)	P=0.753
Preoperative vertical	4 ± 3.7(0-10)	5.85 ± 2.2(0-14.4)	P=0.075
Early postoperative vertical	1 ± 1.16(0-5)	3.45 ± 1.82(1-8)	P=0.023
Last control vertical	0.9 ± 1.16(0-5)	3.57 ± 2.04(1-9)	P<0.001
Preoperative anterior-posterior	6.9 ± 3.2(3-13)	7.1 ± 2.7(3-14)	P=0.777
Early postoperative anterior-posterior	2.15 ± 1.89(0-8)	3.83 ± 2.61(0-8)	P=0.028
Last control anterior-posterior	2.26 ± 1.98(0-8)	3.88 ± 2.64(0-8)	P=0.038

moderate in 4 (10.5%) patients.

According to Tile classification; 28 (73.7%) of the patients were Type B and 10 (26.3%) were Type C. In Tile Type C, preoperative vertical (P=0.001) and preoperative anteroposterior displacement (P=0.04) measurements were significantly higher than Tile Type B. There was no significant difference between other radiological parameters (Table 1).

A total of 54 screws were used in 38 patients. In 23 patients, one screw was used in S1 and one screw in S2; in 12 patients, one screw in both S1 and S2; and in 2 patients, 3 screws were used in S1 and S2. 30 (55.5%) of the screws were used on the left side and 24 (44.5%) were used on the right side. The diameter of the used screws was 6.5 mm cannulated and the mean length was 88.3 (75 to 115) mm. Preoperative sacroiliac, vertical and antero-posterior displacement were significantly higher in patients with two or more screws used (P<0.001).

In addition to the iliosacral screw treatment; external fixator was applied to 13 (34.2%) patients, plate in symphysis pubis to 8 (21.1%) patients, plate in iliac crest fracture to 3 (7.8%) patients. Preoperative sacroiliac, vertical and anterior-posterior displacements of iliosacral screw + ex fixation or plate-screw cases were significantly higher (P<0.001).

There were no significant differences found in terms of gender, age, number of screws used, additional fracture and organ pathology, and time of operation when the groups were compared (P>0.05).

There were 22 (57.8%) patients 85 and above, and 16 patients below 85, according to Majeed functional scoring. According to the Majeed functional score; early postoperative and final follow-up vertical and anterior-posterior displacement amounts were significantly lower in patients scored 85 or above, according to the Majeed functional scoring (Table 2).

In 2 (5.2%) patients who had external fixation and in 1 (2.6%) patient who had plate on symphysis pubis, infection was observed. Patients with pin tract infection were treated with antibiotics and local wound care. The patient, who had an infection due to the plate in symphysis pubis, was treated with serial debridement and parenteral antibiotherapy.

Sacral variation was present in 17 (44.7%) patients. The number of patients with screw malposition was 6 (11.1%). Four (7.4%) of the screws perforated sacral foramen and 1 (1.85%) perforated the sacral canal, 1 (1.85%) had extraosseous localization. The screws in the sacral canal and foramen were not revised due to the absence of a clinical finding, while the extraosseous located was revised.

Figure 3: Intraoperative marking and reduction.

No significant correlation was found between the patients with a dysmorphic sacrum and a normal sacrum (P=0.778).

Preoperative neurological deficits were present in 4 (10.5%) patients. In three of them (7.89%) had foot drop due to peroneal nerve paralysis. The other patient with neurological deficits had bone compression to the secondary spinal canal L4 fracture, with severe pain and motor loss in the left lower extremity. The patients were followed up with orthosis and medical treatment. Nonunion, malunion, iatrogenic vein and nerve damage were not observed in patients.

Discussion

In causes of pelvic injuries, motor vehicle accidents are the first with 60%, while the second most common cause is fall from height with 30% and the third most common cause is crush injuries [3]. While it is seen more rare than extremity fractures, it is seen in approximately 20% of patients with blunt trauma and multiple injuries and the mortality rate can be up to 50%. It is more common in males [4,5,10,11]. In the hemodynamically unstable pelvis injuries where open reduction and internal fixation is contraindicated in early period, iliosacral screw application alone or with external fixator is considered to be the most suitable and only option.

Müller et al. [12] evaluated 31 patients with Tile Type C injury who were applied external fixation in addition to iliosacral screw treatment. They reported that age, gender, time of operation, whether the injury was unilateral or bilateral were not effective on postoperative functional and radiological results. Chang-Wug et al. [13] evaluated 19 patients; 14 patients with AO type C, 5 with AO type B and reported that the risk of neurological damage was increased due to the severity of the injury and had a negative effect on the functional results. Vallier et al. [14] evaluated the functional

and radiological results as independent of age and trauma severity, and the results were worse in open fractures, additional organ and orthopedic injuries. Draijer et al. [15] reported in their study including 43 patients that the functional results were worsened due to the severity of the trauma. In our study, when we compared the groups according to gender, age, time of operation, type of fracture, having additional orthopedic and system injury, the number of screws used and the use of additional treatment methods; we did not find any statistically significant difference in terms of radiological and functional results. However, we must emphasize that the groups are not very well randomized.

Functional outcomes with anatomic reduction in pelvic fractures are closely related. In the studies conducted, 6 of the 11 examined studies evaluated displacements of below 5 mm as excellent and displacements between 5 mm to 10 mm as good. In general, it is stated that reduction displacements below 10 mm are acceptable [16]. Nepola et al. [17] evaluated 33 patients with Tile Type C injuries and reported that their postoperative vertical displacement ranged from 2 mm to 52 mm, but there was no difference between residual vertical displacement and functional outcomes. Mclaren et al. [18] evaluated 43 patients retrospectively in their study, and those with less than 1 cm displacement in the postoperative period were reported to have better functional outcomes than those with a displacement of more than 1 cm.

In our study, postoperative reduction measurements were performed as suggested by Henderson. In the late period postoperative anteroposterior displacement measurements, when the long-term vertical displacement of 31 (81.6%) patients was examined, the displacement of 33 (86.8%) patients was 5 mm and below and it was evaluated as perfect in accordance with the literature. The displacement rates of the other patients were between 5 mm to 10 mm and were considered as good. When we compared the patients who had excellent Majeed's functional scores with good and moderate scored ones; it was observed that there was no statistically significant difference between vertical, antero-posterior and sacroiliac separations preoperatively, but postoperative anteroposterior and vertical displacements were significantly lower in patients with excellent Majeed scores.

In addition, we found that postoperative early values were significantly lower compared to preoperative displacement measurements in our study. When we compared postoperative early and late period parameters, we found no significant difference. Therefore, we can say that the treatment with iliosacral screw provides effective and sustainable rigid fixation in the early stage and in the long term.

The treatment of symphysis pubis separations in Tile Type B fractures that are over 2.5 cm is surgery. Reduction can be continued with internal or external fixations in reductable displaced symphysis separations [19]. In our study, pelvic external fixator was applied in 13 (34.2%) patients and plate to symphysis pubis in 8 (21.05%) patients and there was no statistically significant difference between the radiological and functional results of patients who had external fixation, who had symphysis pubis plate and who was not applied anything. We think that the anterior ring should be stabilized as the posterior ring, especially in cases of bilateral fractures of the anterior ring and separation of symphysis pubis more than 2.5 cm. In our study, preoperative vertical and preoperative anterior-posterior displacements were statistically significantly lower in Tile Type B when compared to Tile Type C. Although postoperative radiological and functional results were better in Tile Type B, there was no statistically significant difference. Therefore, although preoperative displacement amounts are different, it is possible to obtain good radiological and functional results in Type C with good reduction and fixation as in Type B.

Sullivan et al. [20] evaluated 16 patients who had pelvic injury without additional fractures and organ injuries according to Majeed functional scoring and obtained excellent results in 37.5%, good in 25%, moderate in 18.75% and poor in 18.75%. Vaidya et al. [21] found the Majeed functional score as 78.77 (40-100) and emphasized that the functional scores were worsened related to the severity of the injury. In our study, mean Majeed score of the patients was 84.7 ± 10.5 (56-97). The results were evaluated as excellent in 22 (57.8%) patients, good in 12 (31.5%) and moderate in 4 (10.5%) patients. One of the patients with moderate to functional scoring was the patient with multiple epiphyseal dysplasias and from the other two patients, one had L4 vertebrae fracture and the patient's spinal canal was pressed, while the other one had a foot drop and had severe pain in the lower extremities.

In the treatment with sacroiliac screw, neurological damage can vary between 0.5% to 7.7% and screw malposition between 2% to 15%. Complications can be seen even in small deviations of 4 degrees from the normal axis of the screw. In order to send a successful iliosacral screw; proper reduction and good identification of the sacral dysmorphism and adequate intraoperative image support are required [22,23]. In a multicenter study of 3607 it patients, it was reported that the most commonly affected nerves were L5 (18.3%), S1 (15.6%) and peripheral nerves (19.2%). Iatrogenic nerve damage was reported as 1.9%. They concluded that the degree of instability, the presence of a complex pelvic trauma and an unstable sacrum fracture in the patient with pelvis fracture, were predisposing to the nervous system injuries [24]. There was no iatrogenic nerve injury in our study. There were nerve damage in 4 patients preoperatively; 3 of which were consistent with peroneal nerve injury, and the other patient had severe pain and motor loss in the left lower extremity due to spinal canal pressure at level L4. The patients were followed up with medical treatment.

Sacral variations in adults were reported in the literature between 15% to 50% [25-28]. The risk of iatrogenic vascular-nerve injury increases in patients with sacral dysmorphism. In patients with dysmorphic sacrum, it is recommended that the screws should be sent to the S1 vertebrae more caudal to the cranial in the coronal plane and more posterior to the anterior in the axial plane. Due to the narrow corridor in the horizontal A-P plane, a maximum of one screw can be used on the S1 vertebra. However, easier and longer screws can be used for S2 vertebrae [25]. In our study, sacral dysmorphism was observed in 17 (44.7%) patients. Only one of the patients with dysmorphic sacrum had a screw on the S2 vertebra because of the narrow corridor in the S1 vertebra.

In patients with pelvic injury, although the angles of the inlet and outlet radiographs are indicated as 45 degrees, it is recommended that these radiographs have interpersonal differences and in CT on saggital plane, angles should be calculated and inlet and outlet radiographs should be taken according to the calculations [29]. Thus, both the operation time and the exposure to radiation are reduced. With the sagittal plane CT measurements, inlet and outlet angles can be determined. Gusic et al. [30] in their study on 30 patients; divided

groups according to age and gender and measured an average inlet angle of 22.3 (10.4-39.8), an average outlet angle of 42.3 (31.5-53.1), and found no significant difference between inlet and outlet angles in terms of age and gender (Figure 2). Bulut M et al. [29] examined the pelvises of 50 male and 50 female cases aged between 18 and 80 years, measured the mean inlet angle in males as 34.30 ± 5.96 (21.5 to 46.5) and in females as 30.84 ± 7.53 (16.5 to 48.5) in degrees, and found a significant difference between the groups.

The learning curve being longer, the greater the risk of vascular nerve injury and the higher the number of the scopy are the disadvantages of the method. The small numbers in the comparison groups and the deficiencies in the standardization of the groups constitute the weaknesses of our study.

In order to achieve a successful outcome in the treatment of the ilocacral screw; an intraoperative fluoroscopic image, which is taken from right angles and in good quality, is required. Apart from fluoroscopy, navigation and CT-guided sacroiliac screw treatment can be applied but it is not available in every center [31]. Zwingman et al. [32] found in their study in which they evaluated 51 cases that screw malposition was significantly lower in patients who had CT than navigation and fluoroscopy. They reported no significant difference between these three methods in terms of secondary surgical requirement. In our study, fluoroscopy was used as the imaging method and the results were quite good in terms of secondary surgical requirement, complication, and postoperative radiological and functional results. We believe that fluoroscopy is an effective and adequate imaging method with an experienced surgical team. It is possible to obtain good radiological and functional results with iliosacral screw treatment in unstable posterior ring injuries of the pelvis.

However, in order to obtain a good result radiologically and functionally, a good reduction should be provided at acceptable limits before fixation. We think that the screw displacement in the right angles with the scopy images, after the inlet and outlet angles being calculated according to the values measured separately in the sagittal plane of computerized tomography for each patient, is effective on these results. Radiation beams should be sent in parallel to the sacrum while the inlet image is taken. Sacrum narrows in the anteroposterior plane toward the distale. While the angle of the inlet was measured for S1 and S2, the angles between the tangent line to the anterior and posterior of S1-S2 and sagittal axis were calculated separately in the sagittal section on tomography. Then the averages of these angles were calculated. To take the most accurate outlet image, the radiation beams should be come to 90 degrees perpendicular to the sacrum. Thus, it is understood whether the screws penetrate the sacral foramen or the L5-S1 disc. Outlet angle is calculated by deducting the average inlet angle value from 90. Since it is a minimally invasive method, provides a strong fixation, can be applied in the early and open fractures, provides early fixation in the patients with multiple trauma, doesn't have systemic burden on the patient, can be used in patients who have serious soft tissue injury percutaneous and since the soft tissue dissection and the blood loss is low; we think that the ISS method is a suitable option in pelvic injuries due to its advantages.

References

1. Papakostidis C, Giannoudis PV. Pelvic ring injuries with haemodynamic instability: Efficacy of pelvic packing, a systematic review. Injury. 2009;40(4):S53-61.
2. Tile M. Acute pelvic fractures: I. Causation and classification. J Am Acad Orthop Surg. 1996;4(3):143-51.
3. Schmal H, Markmiller M, Mehlhorn AT, Sudkamp NP. Epidemiology and outcome of complex pelvic injury. Acta Orthop Belg. 2005;71(1):41-7.
4. Yair B, Meir L, Ori S, Amal K, Rami M. Pelvis fractures in a level 1 trauma center. A test case for the efficacy of the evolving trauma system in Israel. Isr Med Assoc J. 2005;7(10):619-22.
5. McCormack R, Strauss EJ, Alwattar BJ. Diagnosis and Management of Pelvic Fractures. Bull NYU Hosp Jt Dis. 2010;68(4):281-91.
6. Tile M. Acute Pelvic Fractures: II. Principles of Management. J Am Acad Orthop Surg.1996;4(3):152-61.
7. Burgess AR, Eastridge BJ, Young JW, Ellison TS, Ellison PS, Poka A, et al. Pelvic ring disruptions: Effective classification system and treatment protocols. J Trauma. 1990;30(7):848-56.
8. Henderson RC. The long term results of nonoperatively treated major pelvic disruptions. J Orthop Trauma. 1989;3(1):41-7.
9. Majeed SA. Gradıng the outcome of pelvic fractures. J Bone Joint Surg Br. 1989;71(2):304-6.
10. Canale ST, Beaty JH, Calandrucio JH, Azar FM. Campbell's Operative Orthopaedics. In: Canale ST, Başbozkurt M, editors: Acetabulum and Pelvis Fractures. 11th edn: 2011;3334-70.
11. Giannoudis PV, Martin R, Grotz W, Tzioupis C, Dinopoulos H, Wells GE, et al. Prevalence of Pelvic Fractures, Associated Injuries, and Mortality: The United Kingdom Perspective. J Trauma. 2007;63(4):875-83.
12. Müller FJ, Stosiek W, Zellner W, Neugebauer R, Füchtmeier B. The anterior subcutaneous internal fixator (ASIF) for unstable pelvic ring fractures. Clinical and radiological mid-term results. Int Orthop. 2013;37(11):2239-45.
13. Oh CW, Kim PT, Kim JW, Min WK, Kyuung HS, Kım SY, et al. Anterior plating and percutaneous iliosacral screwing in an unstable pelvic ring injury. Orthop Sci. 2008;13(2):107-15.
14. Vallier HA, Cureton BA, Schubeck D, Wang XF. Functional outcomes in women after high-energy pelvic ring injury. J Orthop Trauma. 2012;26(5):296-301.
15. Draijer F, Egbers HJ, Havemann D. Quality of life after pelvic ring injuries: follow-up results of a prospective study. Arch Orthop Trauma Surg. 1997;116(1):22-6.
16. Mataliotakis GI, Giannoudis PV. Radiological measurements for postoperative evaluation of quality of reduction of unstable pelvic ring fractures: Advantages and limitations. Injury. 2011;42(12):1395-401.
17. Nepola JV, Trenhaile SW, Miranda MA, Butterfield SL, Fredericks DC, Riemer BL. Vertical shear injuries: is there a relationship between residual displacement and functional outcome? J Trauma. 1999;46(6):1024-9.
18. Mclaren AC, Rrabeck CH, Halpenny J. Long term pain-disability in relation to residula deformity after displaced pelvic ring fracture. Can J Surg. 1990;33(6):492-4.
19. Aşık M, Baştürk S, Yazıcıoğlu Ö, Seyhan F. Principles of diagnosis and treatment of pelvic fractures. Acta Orthop Traumatol Turc. 1996;30:199-205.
20. Sullivan MP, Scolaro JA, Milby AH, Mehta S. Isolated pelvic ring injuries: functional outcomes following percutaneous, posterior fixation. Eur J Orthop Surg Traumatol. 2015;25(6):1025-30.
21. Vaidya R, Jonathan M, Roth M, Tonnos F, Oliphant B, Carlson J. Midterm Radiographic and Functional Outcomes of the Anterior Subcutaneous Internal Pelvic Fixator for Pelvic Ring Injuries. J Orthop Trauma. 2017;31(5):252-9.
22. Iorio JA, Jakoi AM, Rehman S. Percutaneous Sacroiliac Screw Fixation of the Posterior Pelvic Ring. Orthop Clin North Am. 2015;46(4):511-21.

23. Xu R, Ebraheim NA, Robke J, Yeasting RA. Radiologic evaluation of iliosakral screw placament. Spine. 1996;21(5):582-8.

24. Schmal H, Hauschild O, Culemann U, Pohlemann T, Stuby F, Krischak G, et al. Identification of risk factors for neurological deficits in patients with pelvic fractures. Orthopedics. 2010;33(8):1-6.

25. Miller AN, Routt ML. Variations in Sacral Morphology and Implications for Iliosacral Screw Fixation. J Am Acad Orthop Surg. 2012;20(1):8-16.

26. Hasenboehler EA, Stahel PF, Williams A, Smith WR, Newman J, Symonds DL, et al. Prevalence of Sacral Dysmorphia in a Prospective Trauma Population: Implications for a "Safe" Surgical corridor for sacroiliac screw placement. Patient Saf Surg. 2011;5(1):8.

27. Matityahu A, Kahler D, Krettek C, Gebhard F, Stöckle U, Grutzner PA, et al. Three-Dimesional Navigation is More Accurate Than Two Dimensional Navigation or Conventional Fluoroscopy for Percutaneous Sacroiliac Screw Fixation in the Dsymorphic Sacrum: A Randomizde Multicenter Study. J Orthop Trauma. 2014;28(12):707-10.

28. Kaiser SP, Gardner MJ, Liu J, Routt ML, Morshed S. Anatomic Determinants of Sacral Dysmorphism and Implications for Safe Iliosacral Screw Placement. J Bone Joint Surg Am. 2014;96(14):120-5.

29. Bulut M. Morphometric Evaluation of the Sacrum and Sacroiliac Joint Anatomy According to Age and Gender Differences with Computed Tomography Scanning in Southeastern Anatolia Region. Dicle University, Institute of Health Sciences, Anatomy PhD Thesis. 2016, Diyarbakır (Advisor: Prof. Dr. M.Cudi TUNCER).

30. Gusic N, Grgorinic I, Fedel I, Lemac D, Bukvic N, Gusic M, et al. Fluoroscopic iliosacral screw placement made safe. Injury. 2017:48(5);S70-72.

31. Stockle U, Konig B, Hofstetter R, Nolte LP, Haas NP. Navigation assisted by image conversion. An experimental study on pelvic screw fixation. Unfallchirurg. 2001;104(3):215-20.

32. Zwingmann J, Hauschild O, Bode G, Sudkamp NP, Schmal H. Malposition and revision rates of different imaging modalities for percutaneous iliosacral screw fixation following pelvic fractures: a systematic review and meta-analysis. Arch Orthop Trauma Surg. 2013;133(9):1257-65.