World Journal of Vascular Surgery

Clinical Image
Published: 28 Dec, 2021

TAVI to Toe

Bijit Munshi[1], Gerald Yong[2], Leena Naggapan[3] and Toby Richards[1,4]*

[1]Department of Vascular Surgery, Fiona Stanley Hospital, Australia

[2]Department of Cardiology, Fiona Stanley Hospital, Australia

[3]Department of Anesthesia & Pain Medicine, Fiona Stanley Hospital, Australia

[4]School of Surgery, The University of Western Australia, Australia

Clinical Image

81-year-old male presented with left hallux and third toe tissue loss for three months. He reported intermittent calf claudication at 100 m for two years. Past history included non-ST elevation myocardial infarction managed with drug-eluting stents to right coronary artery, and chronic kidney disease stage III. Vascular risk factors included hypertension, hypercholesterolemia and ex-smoker from four years. Medications were aspirin, rosuvastatin, bisoprolol and ramipril. Functionally he was independent at home.

On examination no femoral pulses or peripheral pulses were palpable on either side. He had a loud ejection systolic murmur but no signs of heart failure. CT angiogram showed bilateral >90% common iliac artery stenoses, bilateral severe common femoral artery disease with bilateral superficial femoral artery occlusions, distally above knee popliteal reconstitution and three-vessel run-off to the feet.

Echocardiogram showed severe concentric left ventricular hypertrophy and severe aortic stenosis (mean gradient 51 mmHg), with preserved ejection fraction (55%).

Clinical relevance

Cardiac complications are common in vascular patients due to commonality of risk factors for atherosclerosis. These are relevant in vascular surgery where hemodynamic changes at operation from vessel clamping, blood loss, and reperfusion are all triggers of cardiac stress. Specifically, these hemodynamic changes can precipitate life threatening acute pulmonary edema in severe aortic stenosis.

Following a joint multidisciplinary meeting of vascular surgery, anesthesia and cardiology, simultaneous TAVI and lower limb revascularization was planned. Femoral access was needed to enable TAVI access, before lower limb arterial reconstruction.

At operation, under general anesthetic, right common femoral endarterectomy and patch angioplasty with Bovine pericardium was performed followed by plain balloon angioplasty to the common and external iliac arteries initially to 8 mm followed by 9 mm to enable a 16Fr eSheath (with dynamic expanding mechanism to approximate outer diameter of 24Fr) to be passed into the aorta. Following heparin dosing to ACT>250, with rapid ventricular pacing at 200 bpm, a 25 mm Edwards balloon aortic valvuloplasty was performed and a 29 mm Edwards SAPIEN 3 valve sited.

Following removal of the TAVI sheath and TOE revealing good TAVI function, lower limb arterial reconstruction proceeded. Left common femoral endarterectomy and patch angioplasty with Bovine pericardium was followed by subintimal left iliac artery angioplasty and stenting with a 10 mm Viabahn stent into the common and external iliac artery. Subsequently, a femoro-popliteal bypass graft was performed with reversed great saphenous vein. A full body angiographic reconstruction is shown in Figure 1.

The combined procedure took a total of 10 h. Starting blood pressure was 150/50 mmHg. Vasopressor requirements increased post TAVI implantation. Estimated blood loss was 500 mL 3U PRBC were administered to replace losses. The anesthetic chart is shown in Figure 2.

ICU recovery was uneventful with vasopressor support being progressively weaned. An episode of self-resolving supraventricular tachycardia was observed but no other tachyarrhythmias occurred throughout recovery. Echocardiogram showed a functioning transcatheter aortic valve with mild paravalvular aortic regurgitation (mean gradient 14 mmHg). He was extubated the next day moved

OPEN ACCESS

Correspondence:
Bijit Munshi, Department of Vascular Surgery, Fiona Stanley Hospital, 102-118 Murdoch Drive, Murdoch, WA 6150, Australia,
E-mail: bijit.munshi@gmail.com

Received Date: *09 Dec 2021*
Accepted Date*: 22 Dec 2021*
Published Date*: 28 Dec 2021*

Citation:
Munshi B, Yong G, Naggapan L, Richards T. TAVI to Toe. World J Vasc Surg. 2021; 4(1): 1031.

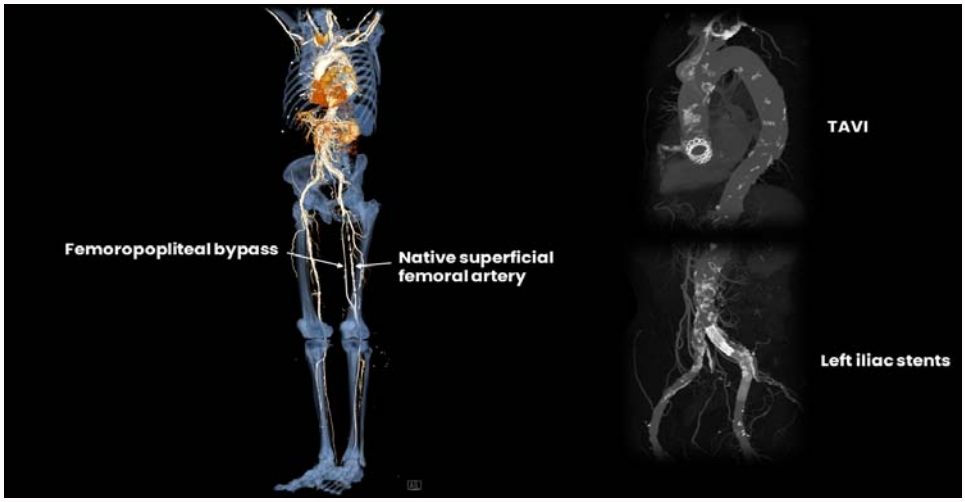

Figure 1: TAVI to Toe.

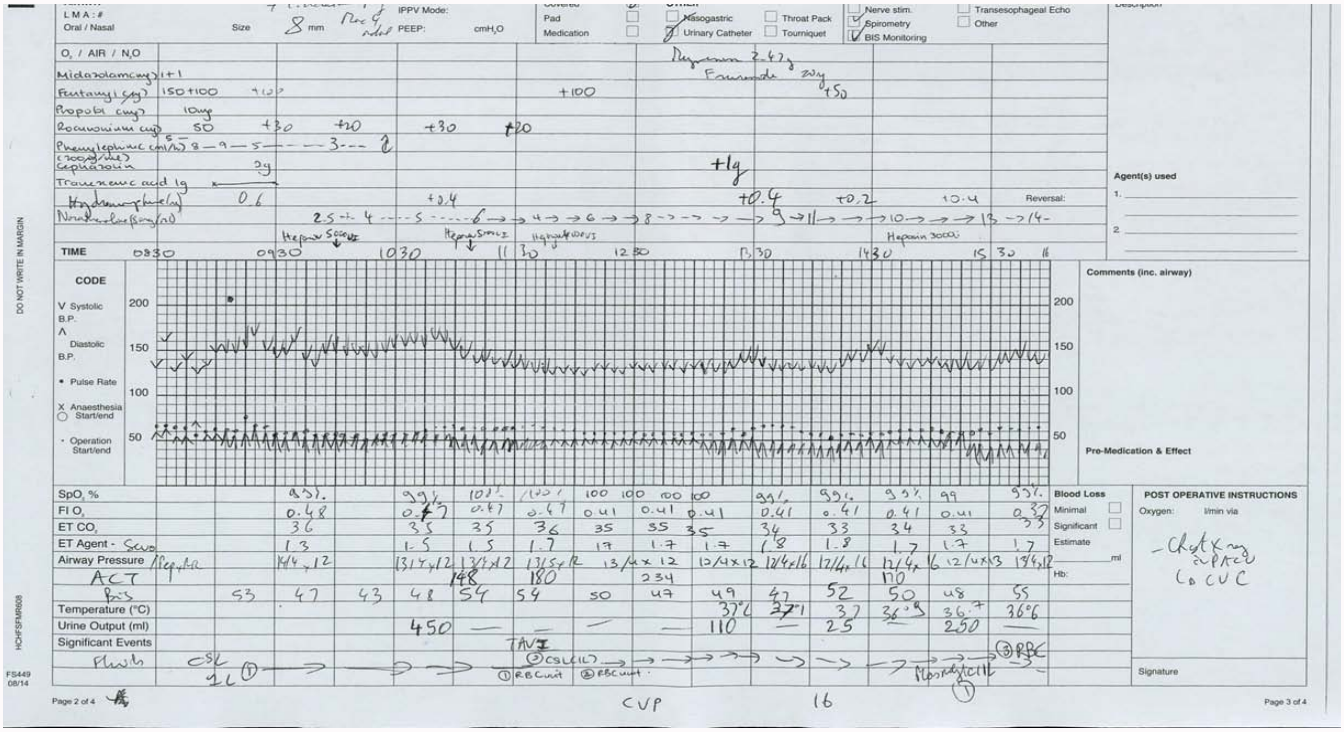

Figure 2: TAVI to Toe.

from ICU to the ward on day three postoperatively. Respiratory and renal function remained stable throughout the post-operative period. On day 9 the patient had left hallux and third toe trans-phalangeal amputations and he was subsequently discharged on day 14. Follow up at 6 weeks revealed all surgical and amputation wounds had healed.

Take-home message

Cardiovascular comorbidities are common in vascular surgery. We present the first reported case of combined TAVI and extensive lower limb revascularization as part of a multidisciplinary approach to patient care.