Journal of Surgical Techniques and Procedures

Surgical Technique
Published: 28 Dec, 2021

Surgical Treatment of Tibial Plateau Fracture in Leg Holder Hanging Position

Konstantinos Ditsios, Charalampos Pitsilos*, Triantafyllos Katsimentzas, Charalampos Pavlopoulos and Pericles Papadopoulos

Department of Orthopedics, Aristotle University of Thessaloniki, G. Gennimatas Hospital, Greece

Abstract

Tibial plateau fractures are common in patients presented in trauma centers. Their management is challenging, as preservation of the congruity of the articular surface and knee stability are important for the best functional outcome and the prevention of future arthritis. When surgical treatment of these injuries is decided, a wide spectrum of patient's positions and approaches has been described, depending on the fracture morphology and the surgeon's familiarization. In our orthopedic department we have been using supine position with lower limb in leg holder hanging position in minimally invasive osteosynthesis and open reduction and internal fixation of tibial plateau fractures. In this article we highlight the advantages of this position, which are the reasons why we propose it as a main or at least alternative patient's position of the surgical therapy of these fractures.

Introduction

Tibial plateau fractures are common injuries. They can occur in all age group having a bimodal distribution with high energy injuries usually occurring in young adults with good bone quality and low-energy fractures that typically occur in elderly patients with poor bone quality. They present as intra-articular lesions that require anatomical reduction of the joint surface and restoration of the mechanical axis of the lower limb, in order to preserve function of the knee joint and to prevent future knee arthritis [1]. They are frequently overlooked due to the difficulty in recognizing these fractures on X-rays and this is the reason why CT scan is more commonly used on suspicion of these injuries [2]. Treatment includes non-operative and operative management. The former is followed for un-displaced or minimally displaced and stable fractures and for elderly patients who cannot tolerate surgery. Usual indications for surgical treatment are condylar widening of more than 5 mm, articular step-off more than 3 mm, metaphyseal-diaphyseal translation of more than 1 cm, angular deformity of more than 10º in the coronal (varus-valgus) or sagittal plane, open fracture, fracture of medial plateau or bicondylar fractures, associated compartment syndrome, associated ligament injury requiring repair and associated fractures of the ipsilateral tibia or fibula. Operative management includes external fixation, minimal invasive osteosynthesis and open reduction with internal fixation. The latter is the gold standard treatment for tibial plateau fractures [3]. The main approaches for open reduction and internal fixation are the anterolateral, the medial, the posteromedial, the posterolateral and the direct posterior approach. Patient is placed in supine position for the first two approaches, in either supine or prone position for posteromedial approach and in prone position for the last two approaches. Lateral and floating position is used when a combination of approaches is needed [4]. Most of the tibial plateau fractures are treated in supine position with a pad under the affected hip and a rolled sheet under the knee so that the knee joint is flexed 30º to 40º. We propose a supine position with lower limb in leg holder hanging position as it offers some advantages for the reduction and internal fixation of the tibial plateau fractures.

Case Presentation

Leg holder hanging position

In the leg holder hanging position, the patient is supine and a leg holder supports the femur at its middle to distal third in neutral hip flexion while the tibia is hanging. This allows knee flexion of more than 90º, creating dynamic and static circumstances that favor joint exploration and anatomic reduction of intra-articular tibial fractures. The other lower limb is immobilized in hip abduction, either on a surgical table or on a boom (Figure 1).

First: First of all, weight of the tibial combined with some longitudinal traction allows joint space expansion and better visualization of the plateau after the joint capsulotomy.

OPEN ACCESS

****Correspondence:***
Charalampos Pitsilos, Department of Orthopedics, Aristotle University of Thessaloniki, G. Gennimatas Hospital, Ethnikis Aminis 41, 54635, Thessaloniki, Greece, Tel: 6944332663; E-mail: xnostos@hotmail.com

Received Date: *30 Nov 2021*
Accepted Date*: 17 Dec 2021*
Published Date*: 28 Dec 2021*

Citation:
Ditsios K, Pitsilos C, Katsimentzas T, Pavlopoulos C, Papadopoulos P. Surgical Treatment of Tibial Plateau Fracture in Leg Holder Hanging Position. J Surg Tech Proced. 2021; 5(2): 1049.

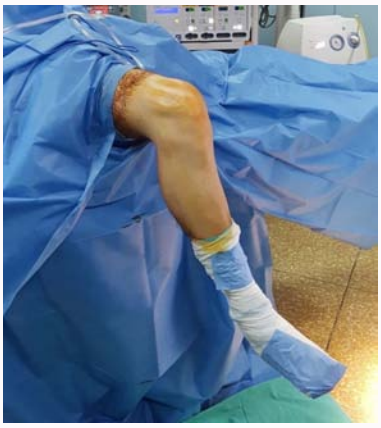

Figure 1: Leg holder hanging position.

Figure 2: Varus force to evaluate the lateral articular surface.

Second: Second, during knee flexion tibial plateau is moved anterior in relation to the femoral condyles. This causes a greater exposure of the articular surface that needs to be explored and restored.

Third: Third hanging limb allows a wide range of rotation of both femur and tibia, especially around the knee. This is why except for posterolateral and direct posterior approach; all the other main approaches of the tibial plateau can be utilized in this position.

Fourth: Fourth, extreme varus and valgus stress can be applied, too. This can be easily achieved by the surgeon's body while in mid-flexion, rendering an assistant not necessary in specific fracture patterns, such as Schatzker I fracture (Figure 2).

Fifth: Fifth the most important static stabilizers of the knee joint are shortened in flexion. The lateral and medial collateral ligaments and the anterior cruciate ligament are relaxed in knee flexion, so are the posterolateral and the posteromedial structures of the knee. This provides a more sufficient abduction or adduction maneuver of the tibia and a better joint exposure.

Sixth: Sixth hanging tibia favors the true evaluation of the alignment of the lower limb. Anatomical and mechanical axis of tibia coincide, at least when they are not disturbed by an old injury or any congenital deformity. It is easier to restore tibial axis in a leg holder hanging position, having femoral condyles and ankle as reference points.

Last but not least: Last but not least fluoroscopy is easier to handle as limb is in the air and there is adequate free space for C-arm rotation and proper position.

From 2018 to 2020, 62 patients with tibial plateau fractures were treated in our orthopedic department in a leg holder hanging position. All patients had a good or excellent functional outcome in respect to their everyday activity, during the follow-up. For all these reasons, we insist that the leg holder hanging position is a favorable patient position for fixation of the most tibial plateau fractures.

Discussion

Tibial plateau fractures are challenging injuries which should be treated properly to preserve knee function and avoid post-traumatic arthritis.

The articular surface of the proximal tibia is divided in three columns, the lateral, the medial and the posterior, which should be restored after fracture fixation [5]. The most popular and widely used classifications of these fractures are Schatzker's and AO's classification. The former describes six types of tibial plateau fractures. Type I is a split wedge fracture of the lateral tibial plateau. Type II is a split wedge depression fracture of the lateral tibial plateau. Type III is a pure depression fracture of the lateral tibial plateau. Type IV is a split wedge fracture of the medial tibial plateau. Type V is a bicondylar tibial plateau fracture, where there is continuity between epiphysis and diaphysis. Type VI is a bicondylar tibial plateau fracture with complete discontinuity between epiphysis and diaphysis. AO's classification describes unicondylar fractures as 41B and bicondylar fractures as 41C. Recently, a revised Schatzker's classification was proposed, based on the three-dimensional imaging with CT scan for tibial plateau fractures, which is a combination of former Schatzker's classification and the three-column theory. It divides lateral and medial tibial condyle to anterior and posterior fragment, giving more specific informations for fracture line orientation and preoperative planning [6]. However, 3D-CT scan is not superior to 2D-CT scan in improving inter observer reliability or diagnostic accuracy for the evaluation of tibial plateau fracture characteristics [7].

Many approaches have been described for open reduction and internal fixation of tibial plateau fractures, based on the location of the fragments [8]. Anterolateral approach is used for lateral plateau fractures. Medial approach is used for isolated fractures of the medial plateau or as part of "dual incision" approach for bicondylar fractures. Posteromedial approach is used for medial tibia plateau fractures, when the fracture line is in or close to the coronal plane. Posterolateral approach is used for coronal fracture line resulting in a displaced posterolateral fragment. Finally, direct posterior approach is used for fracture patterns that cannot be addressed with posteromedial or posterolateral approaches [4]. In addition, anterolateral approach can be extended posteriorly *via* extensive release of the lateral collateral ligament, osteotomy of the lateral rim of the lateral tibial plateau, osteotomy of the fibula head or osteotomy of the lateral epicondyle [9].

Tibial plateau fracture mapping studies conclude that most of the fracture patterns can be reduced and fixed adequately by plates placed with anterolateral, extensive anterolateral, or posteromedial approach. Only complex fractures with posterior fragment may need posterolateral or, rarely, posterior approach, which are the least common types [10,11].

Leg holder hanging position for tibial plateau fracture surgical treatment has been proposed only for arthroscopic-assisted reduction, to our knowledge [12]. In this position the most common approaches can be utilized, so it can be used for internal fixation of the most tibial plateau fractures.

Knee flexion causes some specific circumstances of the joint stabilizing structures that favor articular surface exposure and restoration. When knee moves from extension to flexion, the femoral condyles gradually roll and slide backwards and more tibial plateau is exposed [13]. Furthermore, except for posterior cruciate ligament which is lengthened, the other major ligaments (anterior cruciate ligament, medial collateral ligament, lateral collateral ligament) along with the popliteal complex (femoral insertion of the popliteus tendon and the fibular insertions of the popliteo-fibular ligament) are shortened at 90º of knee flexion, allowing a wider range of rotation and adduction/abduction of the tibia [14]. In addition to medial collateral ligament (superficial and deep portion), posterior oblique ligament, which is an important stabilizer of posteromedial knee corner is also relaxed in knee flexion [15]. The iliotibial band is a key structure to the lateral stability of the knee. While in extension it resists in varus lengthening, anteroposterior translation and internal rotation of the tibia, in high degrees of knee flexion it relaxes, allowing these deforming forces action during surgery. In addition, other posterolateral corner stabilizers, such as biceps femoris, fibular collateral ligament, popliteus tendon, popliteofibular ligament, lateral capsule, arcuate ligament, the lateral aspect of the gastrocnemius muscle and fabellofibular ligament are also relaxed in high degrees of flexion [16].

Finally, except for the fixation of the articular surface, it is important to restore tibial axis. This is why navigation systems of the lower limb alignment have been used [17]. The anatomical and mechanical axes of the tibia coincide. In leg holder hanging position, the axis of tibia can be successfully restored having femoral condyles and ankle as reference points.

Conclusion

To the best of our knowledge, we are the first to describe the advantage of tibial plateau fractures fixation in a leg holder hanging position. Most types of these fractures can be treated in this position, having a satisfactory anatomical and functional outcome. Knee biomechanical features in flexion provide a good joint exposure and rotation of the femur allows the utilization of the most commonly used approaches. For all these reasons, we propose the leg holder hanging position as an official patient's position for the fixation of most of the tibial plateau fractures.

References

1. Junior MK, Fogagnolo F, Bitar RC, Freitas RL, Salim R, Jansen Paccola CA. Tibial plateau fractures. Revista Brasileira de Ortopedia. 2009;44(6):468-74.
2. Kiel CM, Mikkelsen KL, Krogsgaard MR. Why tibial plateau fractures are overlooked? BMC Musculoskelet Disord. 2018;19(1):244.
3. Prat-Fabregat S, Camacho-Carrasco P. Treatment strategy for tibial plateau fractures: an update. EFORT Open Rev. 2017;1(5):225-232.
4. Kandemir U, Maclean J. Surgical approaches for tibial plateau fractures. J Knee Surg. 2014;27(1):21-9.
5. Luo CF, Sun H, Zhang B, Zeng BF. Three-column fixation for complex tibial plateau fractures. J Orthop Trauma. 2010;24(11):683-92.
6. Kfuri M, Schatzker J. Revisiting the Schatzker classification of tibial plateau fractures. Injury. 2018;49(12):2252-63.
7. Mellema JJ, Doornberg JN, Molenaars RJ, Ring D, Kloen P; Traumaplatform Study Collaborative & Science of Variation Group. Tibial plateau fracture characteristics: Reliability and diagnostic accuracy: Erratum. J Orthop Trauma. 2016;30(5):e144-51.
8. Katsimentzas T, Ditsios T, Ditsios K. Surgical approaches and leg positions for tibial plateau fractures. Tibia Pathology Fractures. Intech Open. 2020;1-13.
9. Frosch KH, Korthaus A, Thiesen D, Frings J, Krause M. The concept of direct approach to lateral tibial plateau fractures and stepwise extension as needed. Eur J Trauma Emerg Surg. 2020;46(6):1211-9.
10. Molenaars RJ, Mellema JJ, Doornberg JN, Kloen P. Tibial plateau fracture characteristics: Computed tomography mapping of lateral, medial, and bicondylar fractures. J Bone Joint Surg Am. 2015;97(18):1512-20.
11. McGonagle L, Cordier T, Link BC, Rickman MS, Solomon LB. Tibia plateau fracture mapping and its influence on fracture fixation. J Orthop Traumatol. 2019;20(1):12.
12. Chase R, Usmani K, Shahi A, Graf K, Mashru R. Arthroscopic-assisted reduction of tibial plateau fractures. Orthop Clin North Am. 2019;50(3):305-14.
13. Freeman MA, Pinskerova V. The movement of the normal tibio-femoral joint. J Biomech. 2005;38(2):197-208.
14. Rochcongar G, Pillet H, Bergamini E, Moreau S, Thoreux P, Skalli W, et al. A new method for the evaluation of the end-to-end distance of the knee ligaments and popliteal complex during passive knee flexion. The Knee. 2016;23(3):420-5.
15. LaPrade MD, Kennedy MI, Wijdicks CA, LaPrade RF. Anatomy and biomechanics of the medial side of the knee and their surgical implications. Sports Med Arthrosc Rev. 2015;23(2):63-70.
16. Flato R, Passanante GJ, Skalski MR, Patel DB, White EA, Matcuk GR, Jr. The iliotibial tract: Imaging, anatomy, injuries, and other pathology. Skeletal Radiol. 2017;46(5):605-22.
17. Vibert B, Pailhe R, Morin V, Rubens-Duval B, Saragaglia D. Navigation for lower limb alignment during internal fixation of complex tibial-plateau fractures. Orthop Traumatol Surg Res. 2018;104(4):491-6.