



Structural Alterations in Cortical and Subcortical Region of Brain in Untreated Patients of PTSD: A Concise Review of Recent Medical Literature

Waqas Yasin¹, Sani Zehra², Gulraiz Karim Rind Baloch³, Syed Mujtaba Ali Naqvi⁴ and Ali Khan^{5*}

¹Department of Psychiatry, Medical College of Wisconsin, USA

²Jinnah Medical and Dental College, Pakistan

³Department of Anatomy, Ziauddin University, Pakistan

⁴Department of Neurology, Texas Tech University El Paso, USA

⁵Dow University of Health and Sciences, Pakistan

Abstract

Although psychiatric illnesses are mostly considered to be psychogenic in nature, however with increasing resources and advances in medical study, anatomical neuroimaging studies of the affected brain areas can now provide a significant evidence of the structural abnormalities involved in the psychiatric disorders such as PTSD-first known as shell shock, then combat fatigue, which is considered to be associated with a wide range of traumatic events with an increased risk in individuals who are exposed to physical abuse, physical assault, or kidnapping thus people with PTSD may avoid situations that remind them of the traumatic events. Studies focusing on the structural brain changes in PTSD patients have found abnormalities in both gray and white matter specifically in hippocampus, prefrontal cortex and cerebellum. Advancing research has demonstrated changes in the volumetric measurement of hippocampus which is shown to increase or decrease depending upon different factors such as selective sample size or time of onset, age of onset or duration of the disease. These changes are evident with alteration in behavioral traits in PTSD patients which are known to be regulated *via* hippocampus. Research has shown that cortical thickness of the brain is also affected due to PTSD which is thought to be more prominent in the Prefrontal Cortex (PFC). Whether PTSD causes thickening or thinning of the cortex is believed to be dependent on time and the course of the disease and further research is required to find the most probable cause. Recent studies have shown that cerebellum also plays an important part in psychiatric diseases which contradicts with the earlier belief that cerebellum only regulates motor actives of the brain. Changes in the density of the cerebellum have provided evidence that psychiatric illness not only has their effect on cerebellum but they also change the anatomy of the human brain.

The aim of this review is to provide concise information on the structural brain abnormalities in PTSD.

Keywords: Posttraumatic stress disorder; Structural brain abnormalities; Grey matter; White matter; Cortex; Hippocampus and magnetic resonance imaging

Introduction

Post-Traumatic Stress Disorder (PTSD) is a psychiatric condition that's triggered by a traumatic event-either experiencing it or witnessing it. Symptoms may include intense disturbing thoughts, severe anxiety, fear, anger and feelings related to their experience that last long after the traumatic event has ended. They may relive the event through nightmares and flashbacks; uncontrollable thoughts about the event and they may have strong negative reactions thus people with PTSD may avoid situations that remind them of the traumatic event. Although symptoms can vary over time and from person to person and they may have temporary difficulty adjusting and coping, but with time and good self-care, they usually get better [1].

Post-Traumatic Stress Disorder (PTSD) was once believed to be mostly psychogenic in nature however in the last few decades a rapid growth in the study of PTSD using neuroimaging techniques

OPEN ACCESS

*Correspondence:

Ali Khan, Dow University of Health and Sciences, Baba-e-Urdu Road, Karachi, Pakistan,

E-mail: alikhanmedical409@gmail.com

Received Date: 05 Apr 2020

Accepted Date: 23 Apr 2020

Published Date: 27 Apr 2020

Citation:

Yasin W, Zehra S, Rind Baloch GK, Ali Naqvi SM, Khan A. Structural Alterations in Cortical and Subcortical Region of Brain in Untreated Patients of PTSD: A Concise Review of Recent Medical Literature. *Ann Psychiatr Clin Neurosci.* 2020; 3(1): 1025.

Copyright © 2020 Ali Khan. This is an open access article distributed under the Creative Commons Attribution License, which permits unrestricted use, distribution, and reproduction in any medium, provided the original work is properly cited.

Table 1: Comparison between Volumes of Subcortical Gray Matter and White Matter Structures in PTSD and Healthy Survivors of Trauma [4].

Subcortical Area	Volume of Patients with PTSD (mm ³)	Volume of Healthy Survivors (mm ³)
Hippocampus		
Left	3497.6 ± 447.6	3438.3 ± 480.4
Right	3478.5 ± 366.7	3383.6 ± 371.3
Corpus callosum		
Anterior	843.9 ± 120.6	851.4 ± 145.5
Posterior	903.6 ± 133.2	951.5 ± 136.8
Putamen		
Left	5987.6 ± 784.1	5991.2 ± 758.9
Right	5654.0 ± 695.7	5492.9 ± 669.7

such as Magnetic Resonance Imaging (MRI) and Positron Emission Tomography (PET) have enabled the exploration of dynamic neural and anatomical changes involved in the pathophysiology of PTSD [2].

Studies of structural brain abnormalities in PTSD have focused specially on hippocampus, a grey matter structure that is located in the limbic system which is critically involved in declarative memory, working memory and memory for episodic events [3]. Some studies have deduced that gray matter volume reduction is marked in chronic PTSD patients, there are changes in cortical thickness in various brain regions [4,5]. Alterations in gray matter volume and cortical thickness are determined by the number and size of neurons and glial cells and their degree of myelination and are thought to be more prominent in the hippocampus and in the prefrontal cortex respectively [6].

Different studies have compared patients with PTSD with equally stressed individuals to learn about the specific structural brain changes directly related to PTSD although gray and white matter alterations are typically considered independently however there might be some overlap due to axonal projections [7,8]. Thus, it may be worthwhile to discuss overall structural brain abnormalities and to explore their interrelationships through different studies.

Epidemiology

Worldwide the prevalence rates of PTSD during a given year at a time are between 0.5% to 1% and In the United States the rates is estimated to be 3.5% in adults. According to gender specific studies women have a two to three times higher risk of developing post-traumatic stress disorder as compared to men with a lifetime prevalence of about 10% to 12% in women and 5% to 6% in men [9].

Review of Literature

Literature search strategy

A literature review was carried out to investigate the structural brain changes in the PTSD patients. A Medical search of the literature was performed using the key words posttraumatic stress disorder, structural brain abnormalities, grey matter, white matter, cortex, hippocampus and magnetic resonance imaging. Publications in Pub-Med and references from relevant articles published between 2014 and 2019 were analyzed.

There has been an extensive research on functional and volumetric abnormalities in PTSD. Along with studies demonstrating reduced hippocampal volume in patients with PTSD, studies have shown that these patients tend to perform poorly on explicit memory tasks suggesting a functional impairment of the hippocampal memory

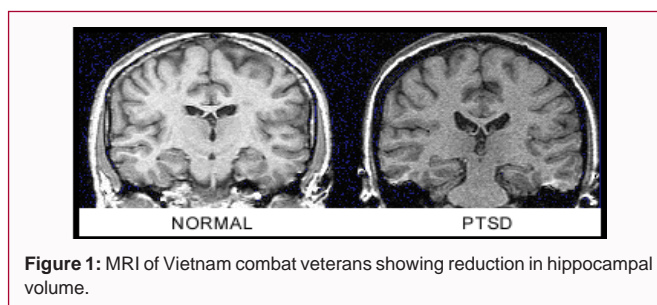


Figure 1: MRI of Vietnam combat veterans showing reduction in hippocampal volume.

system. There are different studies targeting other brain areas such as striatum in PTSD pathology and have found multiple results with some showing reduced while others showing increased blood flow to this region in patients with PTSD as well as cortical thickening [8] when compared with controls [10].

In light of research, gray matter damage is a relevant feature in PTSD and to support this hypothesis researchers have performed various neuroimaging studies to provide evidence on the structural brain abnormalities.

Hippocampal changes in PTSD

Posterior and anterior hippocampal regions have noticeable structural and functional connections and contribute to different emotional and intellectual processes. It is known that the posterior hippocampus has connections with the precuneus and is associated with various cognitive functions specifically playing an important role in memory retrieval and enabling individuals to manage basic and high-level cognitive tasks in everyday life. In contrast, the anterior hippocampus is preferentially associated with the limbic prefrontal circuitry, the Hypothalamic-Pituitary-Adrenal (HPA) axis and the amygdala and is thought to perform stress and emotion-related functions. According to research PTSD-related abnormalities have been found in greater number in the anterior hippocampus as compared to the posterior [2,11,12].

Although shrinkage in the hippocampal volume has been widely reported in the literature [3,12,13] (Figure 1), certain studies oppose these findings and reveals no significant reduction in the relative volume of the right and left hippocampal region [5].

These differences in the results may be attributed to different causes of PTSD, age of onset of disease, duration and severity of symptoms or variance in the sample size in different studies. It still warrants further research to isolate what cases hippocampal volume alteration in PTSD.

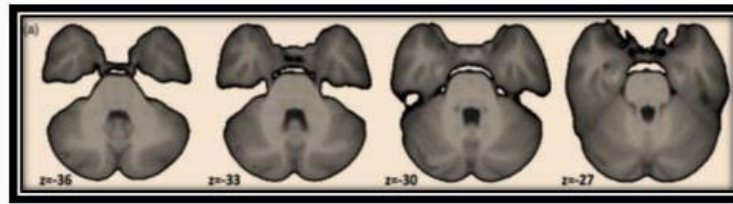


Figure 2: TBM analysis. (a) Transverse images displaying lower cerebellar volume in PTSD versus HC groups ($p < 0.0125$) [8].

Cortical changes in PTSD

Several studies have undergone in context of the changes observed in the cortex in PTSD patients. In a study all participants underwent 3-T magnetic resonance imaging and anatomic images were acquired by using a T1-weighted 3D spoiled gradient-recalled sequence and statistical analyses were performed. Volumes of 14 subcortical gray matter structures and five white-matter structures were obtained for volumetric measurements (Table 1). Out of all the structures of interest that were selected, a noticeable reduction in the volume of posterior corpus callosum in adult patients with PTSD relative to trauma survivors without PTSD was noticed. After analyzing the cortical thickness, an increased thickness in the left precuneus, right inferior parietal lobule, and right superior temporal gyrus in the group with PTSD was noticed as compared to survivors [8]. These findings were consistent with another longitudinal study of trauma victims that demonstrated increased PFC thickness approximately 1 year after trauma [2] although certain studies contradict with increased cortical thickening and reports cortical thinning on average in the PTSD group [5]. It was concluded that the pathological changes in medial parietal cortex may lead to atrophic changes in chronically ill patients while increased cortical thicknesses may occur in some brain regions in the early stages of PTSD [8]. Pictorial presentation of TBM analysis is given in Figure 2.

Cerebellar changes in PTSD

In the early days cerebellum was considered to be associated with motor function only and was largely ignored in psychiatric illness. Now it is believed that the cerebellum receives and sends information to non-motor cortical areas, including prefrontal cortex which is responsible for higher cognitive function thus these changes in cerebellum can directly lead to changes in PFC in PTSD patients. Research indicates that Lesions to the cerebellum can result in anxiety, irritability, aggression and distractibility which are known to be the symptoms of PTSD; this led to a reconceptualization of PTSD [4]. Findings from neuroimaging and lesion studies of cerebellum in PTSD patients showed varying results with some studies showing greater gray matter density in the cerebellum of rape victims with PTSD compared to trauma-exposed healthy controls and alternatively some reported reductions in both grey matter volume and whole-brain functional connectivity. In a study tensor-based morphometry was used to characterize whole-brain structural alterations and a reduction in anatomical covariance with the middle temporal gyrus in PTSD versus control groups was observed. This multimodal study shows overlapping structural and functional alterations in PTSD and associations with symptom severity [4]. Figure 1 Shows TBM analysis indicating low cerebellar volume in PTSD patients [4]. Another study reported greater gray matter density in the cerebellum using voxel-based morphometry in rape victims with PTSD compared to trauma-exposed healthy controls. This difference in density may be related to

the age at exposure to the traumatic event and age of onset of PTSD [5].

Conclusion

In light of the above discussion it is concluded that brain is subjected to structural changes in PTSD which are largely visible in hippocampus, PFC and cerebellum. Although hippocampus is largely researched to reduce in its volume, certain studies show no difference in its measurements which might be due to specific sample selection or small sample size. Similarly contradictions are found in the measurements of cortical thickness which is observed to increase in thickness in the early stages of the disease or when the patients is re-exposed to traumatic events and is noted to decrease in chronically ill PTSD patients. Some conflicts are observed in the measurement of the density of the cerebellum as well, which is hypothesized to be due to time and age of occurrence of the disease though research is yet to flourish in this field.

Nonetheless studies coincide with each other showing different results in volumetric measurements, cortical thickness and density in hippocampus, PFC and cerebellum respectively yet it is clear that patients with PTSD when subjected to neuroimaging techniques are to find structural brain abnormalities specifically in the aforementioned structures.

References

1. Boccia M, D'Amico S, Bianchini F, Marano A, Giannini AM, Piccardi L. Different neural modifications underpin PTSD after different traumatic events: An fMRI meta-analytic study. *Brain Imaging Behav.* 2016;10(1):226-37.
2. Akiki TJ, Averill CL, Abdallah CG. A network-based neurobiological model of PTSD: Evidence from structural and functional neuroimaging studies. *Curr Psychiatry Rep.* 2017;19(11):81.
3. Li L, Wu M, Liao Y, Ouyang L, Du M, Lei D, et al. Grey matter reduction associated with posttraumatic stress disorder and traumatic stress. *Neurosci Biobehav Rev.* 2014;43:163-72.
4. Holmes SE, Scheinost D, DellaGioia N, Davis MT, Matuskey D, Pietrzak RH, et al. Cerebellar and prefrontal cortical alterations in PTSD: Structural and functional evidence. *Chronic Stress (Thousand Oaks).* 2018.
5. Sussman D, Pang EW, Jetly R, Dunkley BT, Taylor MJ. Neuroanatomical features in soldiers with post-traumatic stress disorder. *BMC Neurosci.* 2016;17:13.
6. Mueller SG, Ng P, Neylan T, Mackin S, Wolkowitz O, Mellon S, et al. Evidence for disrupted gray matter structural connectivity in posttraumatic stress disorder. *Psychiatry Res.* 2015;234(2):194-201.
7. Li L, Lei D, Li L, Huang X, Suo X, Xiao F, et al. White matter abnormalities in post-traumatic stress disorder following a specific traumatic event. *EBioMedicine.* 2016;4:176-83.
8. Li S, Huang X, Li L, Du F, Li J, Bi F, et al. Posttraumatic stress disorder: Structural characterization with 3-T MR imaging. *Radiology.*

- 2016;280(2):537-44.
9. Olf M. Sex and gender differences in post-traumatic stress disorder: An update. *Eur J Psychotraumatol.* 2017;8(supl 4):1351204.
 10. Waltzman D, Soman S, Hantke NC, Fairchild JK, Kinoshita LM, Wintermark M, et al. Altered microstructural caudate integrity in posttraumatic stress disorder but not traumatic brain injury. *PLoS One.* 2017;12(1):e0170564.
 11. Malivoire BL, Girard TA, Patel R, Monson CM. Functional connectivity of hippocampal subregions in PTSD: Relations with symptoms. *BMC Psychiatry.* 2018;18(1):129.
 12. Akiki TJ, Averill CL, Wrocklage KM, Schweinsburg B, Scott JC, Martini B, et al. The association of PTSD symptom severity with localized hippocampus and amygdala abnormalities. *Chronic Stress (Thousand Oaks).* 2017;1.
 13. Levy-Gigi E, Szabo C, Richter-Levin G, Kéri S. Reduced hippocampal volume is associated with overgeneralization of negative context in individuals with PTSD. *Neuropsychology.* 2015;29(1):151-61.