Annals of Clinical Radiology

Research Article
Published: 05 Nov, 2019

Prenatal Magnetic Resonance Imaging Evaluation of Hepatic and Retroperitoneal Tumors

Xing Tang[1#], Jin-Bo Jiang[2#], Long-Biao Cui[1,2], Hong Wang[1], Bin Zhang[1], Shun Qi[1], Hong Yin[1]*

[1]*Department of Radiology, Xijing Hospital, Fourth Military Medical University, Xi'an 710032, China*

[2]*Department of Clinical Psychology, School of Medical Psychology, Fourth Military Medical University, Xi'an 710032, China*

[#]*Xing Tang and Jin-Bo Jiang contributed equally to this work.*

Abstract

Objective: Prenatal Magnetic Resonance Imaging (MRI) has been shown to be useful in diagnosing the developmental abnormality of fetuses. Due regard being given to prenatal MRI as an efficient adjunct to Ultrasonography (US), this study sought to demonstrate the in utero visualization of fetal hepatic and retroperitoneal tumor on MRI based on the pathological type.

Methods: We evaluated 267 pregnant women underwent prenatal MRI, among which 5 fetuses had upper abdominal masses (hepatic hemangioendotheliomas in 2, hepatoblastoma in 1, and neuroblastomas in 2) depicted on fetal MR images, confirmed by the following pathological results. With an MRI standard protocol, T2-weighted Single-Shot Turbo-Spin Echo (SSTSE), T1-Weighted Water Selective (WATS), and Diffusion-Weighted (DW) sequences, the whole fetal abdomen was assessed for lesions on the basis of the histopathological type.

Results: On MR images, fetal hepatic hemangioendothelioma, neuroblastomas, and hepatoblastoma shared considerable overlap in imaging features, showing an isolated liver tumor with heterogeneous low T1 and high T2 signal intensity. Distinct characteristics included: (1) local mild hyperintensity within the mass on DW images for hepatic hemangioendothelioma; (2) much more variable signal intensity, with local mild hyperintensity within the mass on DW images for hepatoblastoma; and (3) a hyperintense mass arising from the retroperitoneum on DW images, with central higher T2 and low DW signal intensity representing cystic degeneration for the neuroblastoma.

Conclusion: In this study we demonstrated that prenatal MRI provides the common and unique imaging features for the diagnosis of fetal hepatic hemangioendothelioma, hepatoblastoma, and retroperitoneal neuroblastoma.

Keywords: Fetus; Tumor; Magnetic resonance imaging; Prenatal diagnosis; Pathology

OPEN ACCESS

Correspondence:
Long-Biao Cui, Department of Radiology, Xijing Hospital, Fourth Military Medical University, Xi'an 710032, China, E-mail: lbcui@fmmu.edu.cn

Received Date: *20 Sep 2019*
Accepted Date*: 31 Oct 2019*
Published Date*: 05 Nov 2019*
Citation:
Tang X, Jiang JB, Cui LB, Wang H, Zhang B, Qi S, et al. Prenatal Magnetic Resonance Imaging Evaluation of Hepatic and Retroperitoneal Tumors. Ann Clin Radiol. 2019; 2(1): 1015.

Introduction

Although hepatic tumors are uncommon and account for approximately 5% of the total tumor types occurring in the fetuses and neonates, giant hepatic hemangioma and hepatoblastoma are frequently diagnosed fetal liver tumors, among which large hepatic hemangioma is related to life-threatening perinatal complications [1]. Therefore, it is extremely essential to choose an appropriate management strategy to improve the outcome for fetuses with liver tumors, which depends on prenatal diagnosis [2]. Identifying these masses, however, could be challenging by means of imaging. Besides, differential diagnosis is sometimes required when retroperitoneal tumors with unclear boundary exist in the upper abdomen due to similar imaging features between them.

Ultrasonography (US) is the first choice of prenatal imaging modality for evaluating fetal liver lesions. In recent years, fetal magnetic resonance imaging plays an increasingly important role in the diagnosis of fetal abnormalities and evidence has arisen supporting the notion of fetal Magnetic Resonance Imaging (MRI) as an important adjunct to US in assessing retroperitoneal or hepatic abnormalities in fetuses [3-5]. Meanwhile, the principle of MRI exploits water protons in biologic tissue, leading to MRI possessing no exposure to ionizing radiation. Utilization of MRI could benefit vulnerable population, especially pregnancies and children. In view of the association between fetal tumors and possibility of worse outcome, the potential of fetal MRI as an important adjunctive prognostic imaging test in fetuses with upper abdominal tumors can now be tested. However, in utero diagnosis of hepatic and retroperitoneal tumors on fetal MRI, which has been considered

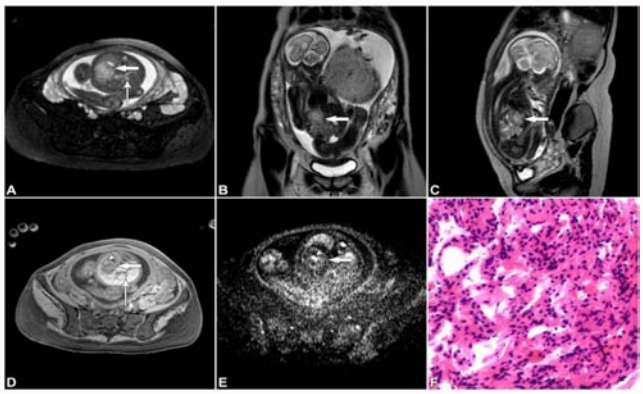

Figure 1: Fetus with a hepatic hemangioendothelioma measuring 2.9 cm × 3.3 cm × 3.0 cm at 27 gestational weeks (case 1). Axial (A), coronal (B), and sagittal (C) T2W MR images demonstrated a heterogeneously hyperintense poor-defined mass (thick arrow) in the left hepatic lobe. The mass is heterogeneously hypointense on T1W-WATS image, with point-like high signal intensity within the mass (arrowhead, D). Biliary duct is seen near the mass (thin arrow). DW image shows high signal intensity in the center of the mass (arrowhead, E). Histopathological findings were used to confirm hepatic hemangioendothelioma (F). (Original magnification, x200).

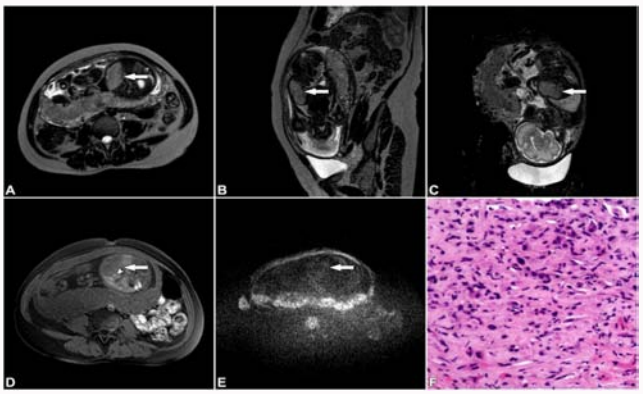

Figure 2: Fetus with a hepatic hemangioendothelioma measuring 2.9 cm × 5.5 cm × 2.3 cm at 28 gestational weeks (case 2). Axial (A), coronal (B), and sagittal (C) T2-weighted MR images demonstrate a heterogeneously hyperintense irregularly shaped mass (arrow) in the right hepatic lobe, with well-marginated border. The mass is heterogeneously hypointense on T1W-WATS image, with local point-like high signal intensity (arrowhead, D). DW image shows mildly hyperintense mass (E). Histopathological findings were used to confirm hepatic hemangioendothelioma (F). (Original magnification, x200).

as an adjunct to US for various indications in prenatal diagnosis, is sparsely investigated. When evidence exists for health-care systems to consider introduction of MRI as an evaluating test for prenatal diagnosis, there might be opportunity to optimize standards to improve this technique in clinical application [6]. Further research is needed to confirm whether this modality is validated in clinical practice.

We therefore aimed to demonstrate the visualization of hepatic and retroperitoneal tumors in the current study, and evaluated the significance of the findings on MR images.

Subjects and Methods

Subjects

Our study was approved by our institutional review board (Xijing Hospital, Fourth Military Medical University) and written consent was obtained from all maternal before enrollment. Between February 2013 and November 2014, a total of 267 pregnant women who were referred to our institution for further prenatal examination, among which five pregnancies (median age, 27 years old; range, 26 years to 29 years old) with five fetuses (mean gestational age, 27 weeks; range, 24 weeks to 28 weeks) ultrasonographically suspected of upper abdominal masses were included in this study. Each case was discussed at a multidisciplinary team meeting prior to fetal MRI evaluation. Gestational age was based on last menstrual period. They were confirmed by pathologic examination of specimens obtained from surgical resection.

MRI Scanning

MRI was performed, according to a standardized protocol, on a 1.5 T unit (Philips Gyroscan Intera). The patients were placed in a supine, head-first position in the magnet. Neither the mother nor the fetus was sedated. The fetus was examined using an eight-channel phased array abdominal coil. The following sequences were used: a T2-Weighted (T2-W) Single-Shot Turbo-Spin Echo (SSTSE) sequence (TR/TE 1200/200 ms, NEX 1, flip angle 90°, matrix 320 × 250, field of view 250 mm × 250 mm, slice thickness 3 mm, section gap 0.3 mm, acquisition time 30 sec) and a T1-Weighted (T1-W) Water Selective (WATS) sequence (TR/TE shortest/shortest, NEX 1, flip angle 80°, matrix 256 × 256, field of view 250 mm × 250 mm, slice thickness 3 mm, section gap 0.3 mm, acquisition time 14.7 sec). Both sequences were obtained in three orthogonal planes.

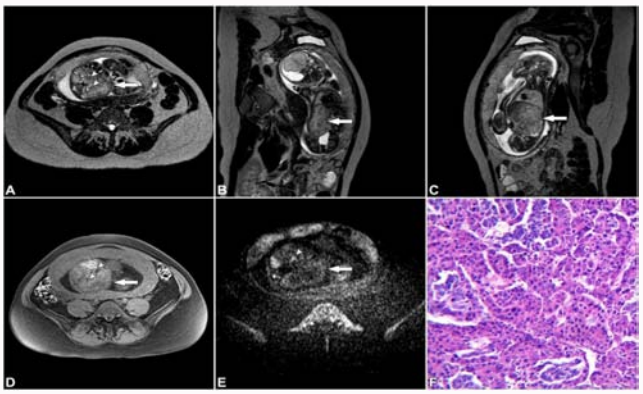

Figure 3: Fetus with a hepatoblastoma measuring 5.5 cm × 3.7 cm × 5.6 cm at 24 gestational weeks (case 3). Axial (A), coronal (B), and sagittal (C) T2-weighted MR images demonstrate a heterogeneously hyperintense irregularly shaped mass (arrow) arising from the right hepatic lobe, with unclear boundary and patch-like low signal intensity (arrowhead) within the mass. The mass is heterogeneously hypointense on T1W-WATS image, with local low signal intensity (arrowhead, D). DW image shows local mildly high signal intensity in the mass (arrowhead, E). Histopathological findings were used to confirm hepatoblastoma (F). (Original magnification, x200).

Image analysis

Two radiologists (X.T. and H.Y.) with more than ten years of experience in MRI prospectively evaluated ultrasonography and MRI data in random order, respectively. Radiologists' reads were blinded to the exact clinical information, and they were not aware results on each other at the time of review, although each case had a suspected abdominal lesion. A finding was considered "suspicious" on images if it could not be confirmed in more than one plane and excluded from the current study.

Results

Fetal MRI was performed on 267 pregnant women, among whom five pregnant women ultrasonographically suspected of upper

Table 1: Findings on Fetal MRI.

Case	Age (y)	Gestational age (w)	Location	Signal intensity			Internal features			Pathological type
				T2	T1	DWI	High T1 signal intensity	Low T2 signal intensity	Low T1 and high T2 signal intensity	
1	28	27	Left lobe	++	-	++	+			Hepatic hemagioendothelioma
2	27	28	Right lobe	+	--	+	+			Hepatic hemagioendothelioma
3	27	24	Right lobe	+	-	++		+		hepatoblastoma
4	29	26	Left retroperitoneum	++++	---	++++			+	neuroblastoma
5	26	27	Left retroperitoneum	+++	---	+++			+	neuroblastoma

Analysis of the image by signal intensity score as + (high) and - (low)

abdominal masses had abnormal MRI results. Of the five fetuses ultrasonographically suspected of upper abdominal masses, two were pathologically diagnosed as hepatic hemangioendothelioma, two as neuroblastomas, and one as hepatoblastoma. Refer to Table 1 for detailed information of these lesions.

Figure 1 and 2 shows the two fetuses with hepatic hemangioendotheliomas. T2W-SSTSE axial, coronary, and sagittal planes showed that the masses with heterogeneously high signal intensity ranging from 2.3 cm to 5.5 cm in diameter. One poor-defined mass located in the left hepatic lobe (Figure 1), and another relatively well-defined masses in the right (Figure 2). They were heterogeneously hypointense on T1W-WATS axial images with local point-like high signal intensity considered as hemorrhage. The biliary duct was observed near the mass on coronary images in one case (Figure 1A and 1D). In addition, DW images showed high signal intensity in the center of one mass representing hemorrhage (Figure 1E), and one mildly hyperintense masses (Figure 2E).

An isolated large hepatoblastoma measuring 5.5 cm × 3.7 cm × 5.6 cm was detected in one fetus, as shown in Figure 3. T2W images demonstrated a heterogeneously hyperintense irregularly shaped mass arising from the right hepatic lobe, with unclear boundary and patch-like low signal intensity within the mass (Figure 3A-3C). It was heterogeneously hypointense on T1W image and with local mildly high signal intensity on DW image (Figure 3D and 3E).

Another two cases had retroperitoneal masses pathologically diagnosed as neuroblastomas (Figure 4 and 5). The masses with well-marginated borders were heterogeneously hyperintense on T2W and DW images and hypointense on T1W images, ranging from 1.8 cm to 4.5 cm in diameter. One lobulated mass had mottled higher T2, lower T1, and low DW signal intensity within the mass representing cystic degeneration (Figure 4). But local low signal intensity was observed within another mass on T2W images (Figure 5).

In order to hemi-quantitatively assess these lesions, we performed image analysis using signal intensity score as + (high) and - (low). Table 1 lists imaging features of all the lesions.

Discussion

In this study we demonstrated that prenatal MRI provided the common and unique imaging features for infantile liver hemangioendotheliomas, hepatoblastoma, and neuroblastoma. MRI is effective in detecting and assessing upper abdominal tumors in fetuses.

Although there is no precise incidence in this area currently, a previous review highlighted hemangioendothelioma as a frequently diagnosed fetal and neonatal liver tumor [7]. In 1982, Weiss and

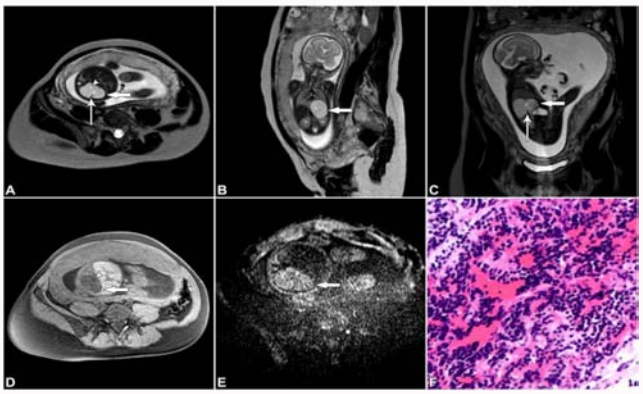

Figure 4: Fetus with a retroperitoneal neuroblastoma measuring 3.6 cm × 3.0 cm × 4.5 cm at 26 gestational weeks (case 4). Axial (A), coronal (B), and sagittal (C) T2-weighted MR images demonstrate a heterogeneously hyperintense lobulated mass (arrow) in the left upper abdomen, with well-marginated border and mottled higher signal intensity (arrowhead) within the mass considered as cystic degeneration. The mass is heterogeneously hypointense on T1W-WATS image, with point-like lower signal intensity (arrowhead, D). DW image shows a hyperintense mass arising from the retroperitoneum, with central low signal intensity representing cystic degeneration (arrowhead, E). Histopathological findings were used to confirm neuroblastoma (F). (Original magnification, x200).

Enzinger [8] proposed that the term hemangioendothelioma should be restricted to those vascular neoplasms showing a borderline biological behavior, intermediate between entirely benign hemangiomas and highly malignant angiosarcomas. In recent pathological classification, this meaning of hemangioendothelioma was still used by Requena and Kutzner [9]. Albeit intermediate between benign and malignant tumor, hemangioendothelioma might elicit life threatening complications, including high output heart failure, consumptive coagulopathy, hemolytic anemia, and tumor rupture, resulting in fetal death [10]. As reported, the neonatal mortality rate of infants with large liver hemangioendotheliomas is 70% to 90% [11]. Therefore, it is extremely essential to choose an appropriate management strategy to improve the outcome for fetuses with hemangioendothelioma, which depends on prenatal diagnosis.

It is essential to provide the best information to the future parents about the nature of the hepatic hemangioendothelioma and the likely clinical outcomes, which depends on making accurate diagnosis of the abnormality in fetus [12]. It has been purported relatively high for the neonatal mortality rate of fetuses with infantile liver hemangioendotheliomas [11]. Hence, fetal abnormalities should be highlighted in obstetric clinical practice. Generally speaking, fetal hepatic hemangioendotheliomas are heterogeneously hyperintense on T2W images and hypointense on T1W images, with mild high

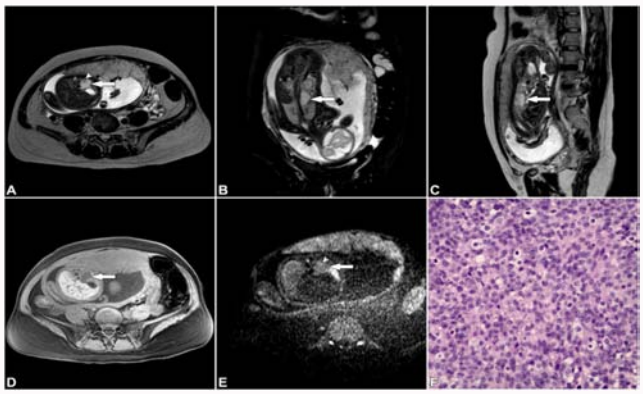

Figure 5: Fetus with a retroperitoneal neuroblastoma measuring 2.7 cm × 2.0 cm × 1.8 cm at 27 gestational weeks (case 5). Axial (A), coronal (B), and sagittal (C) T2-weighted MR images demonstrate a homogeneously hyperintense mass (arrow) next to the vertebra, with well-marginated border and local low signal intensity (arrowhead). The mass is heterogeneously hypointense on T1W-WATS image (D). DW image shows a hyperintense mass arising from the retroperitoneum, with local higher signal intensity (arrowhead, E). Histopathological findings were used to confirm neuroblastoma (F). (Original magnification, x400).

DW signal intensity. They present local point-like high T1 and DW signal intensity considered as hemorrhage. Taken together, fetal MRI could be regard as a tool for parental counseling.

Since MRI provides excellent soft tissue contrast, it can identify the organ origin of fetal abdominal mass and the relationship between them and the surrounding organs. On the basis of the liver tumor with varying degrees of hemorrhage and necrosis, MRI findings show significant differences. In detail, on T1W-WATS sequence hemangioendothelioma present as a mass with clear boundary and is heterogeneously hypointense and point-like high signal intensity can be seen within the mass. High signal observed within the mass contributes to the qualitative diagnosis as hemorrhage. On SSTSE sequence the tumor demonstrates heterogeneously high signal intensity, and the internal necrosis shows patch-like high signal. US axial plane showed that a hypoechoic mass in the right lobe of fetal liver. Color Doppler flow imaging showed that flowing signal in the mass edge. These features on MR images can make up for the limitation of US, on which hyperechoic; hypoechoic or mixed echo mass could not provide clear information for the condition of hemorrhage and necrosis. In addition, a case report by Dong et al. [5] shows an enlarged artery originating from the abdominal aorta, which supplied the hepatic hemangioendothelioma, as well as the distal abdominal aorta with a small caliber due to the presence of intrahepatic arteriovenous shunting, but no case had similar feature in our present study.

The differential diagnosis of fetal liver tumors includes hepatic hemangioendotheliomas, hepatoblastoma, and mesenchymal hamartoma. Imaging of hepatoblastoma has been infrequently reported prenatally using US, and only rarely using MRI [13-17]. As reported by Al-Hussein et al, prenatal MRI at 34 weeks implicated solitary mass confirmed as hepatoblastoma by biopsy [16]. In a previous MRI-based prenatal diagnosis study, T2W image showed large hyperintense mass pathologically confirmed as hepatoblastoma with central necrosis in a fetus at 35 weeks [17]. In our present study, distinguishing features of a hepatoblastoma on fetal MRI include large lesion size, unclear boundary, patch-like low signal intensity within the mass, and higher DW signal intensity compared with hepatic hemangioendothelioma.

In addition to liver tumors, we detected two fetuses with neuroblastomas in the current study. It is obviously liable to distinguish neuroblastoma from liver lesion due to the location of the lesion, as well as more hyperintense on DW images and the feature of cystic degeneration. The location of neuroblastoma can vary due to originating from any site along the sympathetic nervous system chain. Garnier et al. [18], Maki et al. [19], and Blackman et al. [20] reported prenatal MRI features of fetal intrarenal, suprarenal, and paraspinal neuroblastomas, respectively. The appearance of infantile neuroblastoma on MRI depends on whether the lesion is solid or cystic. Both types have a low signal on T1W images, whereas cystic areas have markedly high signal intensity on T2W images, and solid components have moderately high signal intensity [19]. In line with these findings, fetal neuroblastoma presented increased T2 and decreased T1 signal intensity in our current study.

In the last decade, convergent findings have been noted the superiority of fetal MRI to detect cases with fetal tumors, indicating prenatal MRI could be a supplementary method in the diagnosis of fetal tumors [6,21-23].

In summary, by combining data from fetuses with upper abdominal tumors, our study goes beyond prior studies to provide an imaging-level perspective on this infantile liver and retroperitoneal tumors, and demonstrates that MRI is effective in detecting and assessing fetal liver hemangioendotheliomas, hepatoblastoma, and neuroblastomas. MRI is helpful to distinguish hepatic and retroperitoneal tumors. Furthermore, these findings are important because prenatal MRI may be a useful adjunct to US in assessing fetal lesions.

References

1. Makin E, Davenport M. Fetal and neonatal liver tumours. Early Hum Dev. 2010;86(10):637-42.
2. Alamo L, Perrin L, Vial Y, Anooshiravani M, Meuli R. Prenatal imaging of congenital hepatic tumors: a report of three cases. Clin Imaging. 2017;41:112-7.
3. Manganaro L, Vinci V, Giancotti A, Gerli S, Cozzi DA, Pusiol T, et al. Bi-parametric magnetic resonance imaging applied to obstetrics. J Obstet Gynaecol. 2017;37(5):670-2.
4. Snyder E, Jelin AC, Huisman T, Hooper JE, Tekes A. Fatal congenital retroperitoneal neuroblastoma diagnosed by fetal magnetic resonance imaging. J Comput Assist Tomogr. 2017;41(4):651-2.
5. Dong SZ, Zhu M, Zhong YM, Yin MZ. Use of foetal MRI in diagnosing hepatic hemangioendotheliomas: a report of four cases. Eur J Radiol. 2010;75(3):301-5.
6. Pugash D, Brugger PC, Bettelheim D, Prayer D. Prenatal ultrasound and fetal MRI: the comparative value of each modality in prenatal diagnosis. Eur J Radiol. 2008;68(2):214-26.
7. Isaacs H Jr. Fetal and neonatal hepatic tumors. J Pediatr Surg. 2007;42(11):1797-803.
8. Weiss SW, Enzinger FM. Epithelioid hemangioendothelioma: a vascular tumor often mistaken for a carcinoma. Cancer. 1982;50(5):970-81.
9. Requena L, Kutzner H. Hemangioendothelioma. Semin Diagn Pathol. 2013;30(1):29-44.
10. Gembruch U, Baschat AA, Gloeckner-Hoffmann K, Gortner L, Germer U. Prenatal diagnosis and management of fetuses with liver hemangiomata. Ultrasound Obstet Gyneco. 2002;19(5):454-60.

11. Pott Bartsch EM, Paek BW, Yoshizawa J, Goldstein RB, Ferrell LD, Coakley FV, et al. Giant fetal hepatic hemangioma. Case report and literature review. Fetal Diagn Ther. 2003;18(1):59-64.

12. Johnson AB, Richter GT. Vascular anomalies. Clin Perinatol. 2018;45(4):737-49.

13. Shih JC, Tsao PN, Huang SF, Yen BL, Lin JH, Lee CN, et al. Antenatal diagnosis of congenital hepatoblastoma in utero. Ultrasound Obstet Gynecol. 2000;16(1):94-7.

14. Aviram R, Cohen IJ, Kornreich L, Braslavski D, Meizner I. Prenatal imaging of fetal hepatoblastoma. J Matern Fetal Neonatal Med. 2005;17(2):157-9.

15. Catanzarite V, Hilfiker M, Daneshmand S, Willert J. Prenatal diagnosis of fetal hepatoblastoma: case report and review of the literature. J Ultrasound Med. 2008;27(7):1095-8.

16. Al-Hussein HA, Graham EM, Tekes A, Huisman TA. Pre- and postnatal imaging of a congenital hepatoblastoma. Fetal Diagn Ther. 2011;30(2):157-9.

17. Nemec SF, Horcher E, Kasprian G, Brugger PC, Bettelheim D, Amann G, et al. Tumor disease and associated congenital abnormalities on prenatal MRI. Eur J Radiol. 2012;81(2):e115-22.

18. Garnier S, Maillet O, Haouy S, Saguintaah M, Serre I, Galifer RB, et al. Prenatal intrarenal neuroblastoma mimicking a mesoblastic nephroma: a case report. J Pediatr Surg. 2012;47(8):e21-3.

19. Maki E, Oh K, Rogers S, Sohaey R. Imaging and differential diagnosis of suprarenal masses in the fetus. J Ultrasound Med. 2014;33(5):895-904.

20. Blackman SC, Evenson AR, Voss SD, Barnewolt CE, Puder M. Prenatal diagnosis and subsequent treatment of an intermediate-risk paraspinal neuroblastoma: case report and review of the literature. Fetal Diagn Ther. 2008;24(2):119-25.

21. Bulas D. Fetal magnetic resonance imaging as a complement to fetal ultrasonography. Ultrasound Q. 2007;23(1):3-22.

22. Li JL, Hai-Ying W, Liu JR, He QM, Chen KS, Yang J, et al. Fetal Lymphangioma: Prenatal diagnosis on ultrasound, treatment, and prognosis. Eur J Obstet Gynecol Reprod Biol. 2018;231:268-73.

23. Wuest A, Surbek D, Wiest R, Weisstanner C, Bonel H, Steinlin M, et al. Enlarged posterior fossa on prenatal imaging: differential diagnosis, associated anomalies and postnatal outcome. Acta Obstet Gynecol Scand. 2017;96(7):837-43.