



Post SARS-CoV-2 Infection Related Colonic Ulcerations Masquerading as Gastrointestinal Mass

Mukul Rastogi¹, Rakesh Kumar Jagdish^{1*}, Noopur Gupta² and Abhishek Shekhar³

¹Department of Hepatology, Gastroenterology, and Liver Transplant Medicine, Fortis Hospital Noida, India

²Department of Pathology, SRL, Fortis Hospital Noida, India

³Department of Radiology, Fortis Hospital Noida, India

Abstract

SARS-CoV-2 (COVID-19) infection has varied manifestations, ranging from predominant respiratory symptoms to only gastrointestinal manifestations to completely asymptomatic course. Coronavirus can be found in the stool even after other symptomatic recovery and nasal/pharyngeal swab become negative. Gastrointestinal (GI) involvement in COVID-19 also has varied manifestations which can range from diarrheal illness to necrotizing colitis. We hereby reported a case of colonic ulcerations presented as caecal mass which developed during COVID-19 infection recovery.

Keywords: SARS-CoV-2 infection; COVID-19; Colonic ulcerations; Caecal mass; Colonoscopy; Colonic biopsy

Case Presentation

A case of 42 years old female, without any prior comorbidities, having fever of moderate severity, with shortness of breath, was diagnosed with SARS-CoV-2 (COVID-19) infection related pneumonia (COVID-19 RT-PCR Positive), for which she received steroids, ivermectin, azithromycin and other supportive treatment. There was no history of NSAIDs, or tocilizumab, remdesivir treatment. She recovered gradually and discharged.

After 7 days of her COVID-19 therapy, she developed pain in right iliac fossa, which was radiating to umbilicus, non-colicky, severe in intensity; Visual Analogue Score (VAS) of 6/10, requiring analgesics, mimicking acute appendicular pain. It was associated with nausea and infrequent vomiting without loose stools, or abdominal distention. There was no history of bleeding per rectum. There were no residual symptoms of cough, shortness of breath, sore throat, or any other symptoms. She denied any chronic medicine use, prior Gastrointestinal (GI) symptoms, food allergies, lactose intolerance, alcohol abuse, smoking, and drug use. She was treated with metronidazole and other antibiotics for her abdominal symptoms before presenting to us, with no improvement in symptoms.

Laboratory evaluation showed anemia with hemoglobin of 10.5 gm/dl, (range 12.1 g/dl to 15.1 g/dl) white blood cell count of 9100/cumm (range 4500/cumm to 11000/cumm) with 72% of neutrophils and, platelet count was 245,000/microL (range 150,000/microL to 450,000/microL). ESR-55 mm/1st hour (range 0 to 20 mm/hr), INR was 1.0 (range 0.8 to 1.1) and creatinine was 0.85 mg/dL (range 0.59 to 1.04). Stool for ova and cyst were negative. Stool occult blood test was positive.

Contrast Enhanced Computed Tomography (CECT) scan abdomen showed (Figure 1A, 1B) asymmetrical wall thickening of cecum and terminal ileum, needs to rule out malignancy in view of asymmetrical nature of the thickening. Small sub-centimetric hypodense lesion was also noted in liver, which are difficult to characterized and have no appreciable enhancement on contrast study with possible liver metastasis, in view of asymmetrical ceecal thickening. Appendix and pancreas were normal. Because of suspicion of malignancy her tumor marker (CA 19.9, CEA, CA 125, AFP) were done which were normal. She came for further evaluation of her GI symptoms, and she underwent colonoscopy, which showed normal ileum and ileo-cecal valve. There were multiple, punched out; friable ulcerations in caecum and ascending colon with in-between normal mucosa without any obvious thickening, biopsies were taken (Figure 2A, 2B). Differential diagnosis of amoebic colitis, tubercular ulcers, NSAIDs related ulcer, Nonspecific IBD, and COVID related ulceration was considered.

OPEN ACCESS

*Correspondence:

Rakesh Kumar Jagdish, Department of Hepatology, Gastroenterology, and Liver Transplant Medicine, Fortis Hospital Noida, UP, India, Tel: 9718090045; E-mail: dr.rkj.kapil@gmail.com

Received Date: 21 Sep 2021

Accepted Date: 12 Oct 2021

Published Date: 21 Oct 2021

Citation:

Rastogi M, Jagdish RK, Gupta N, Shekhar A. Post SARS-CoV-2 Infection Related Colonic Ulcerations Masquerading as Gastrointestinal Mass. *J Gastroenterol Hepatol Endosc.* 2021; 6(3): 1100.

Copyright © 2021 Rakesh Kumar Jagdish. This is an open access article distributed under the Creative Commons Attribution License, which permits unrestricted use, distribution, and reproduction in any medium, provided the original work is properly cited.

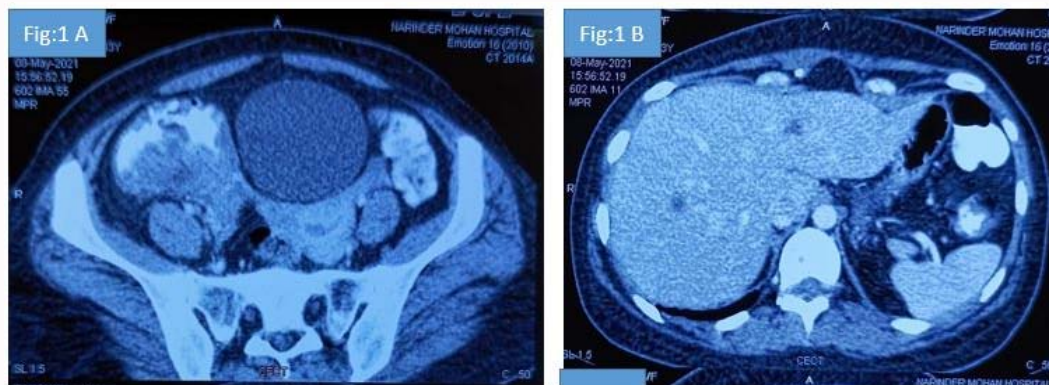


Figure 1: Figure 1A: Abdominal computed tomography showing asymmetrical thickening of the cecum and IC junction. Figure 1B: Suggestive of <1 cm hypodense lesions too small to characterize in the liver.

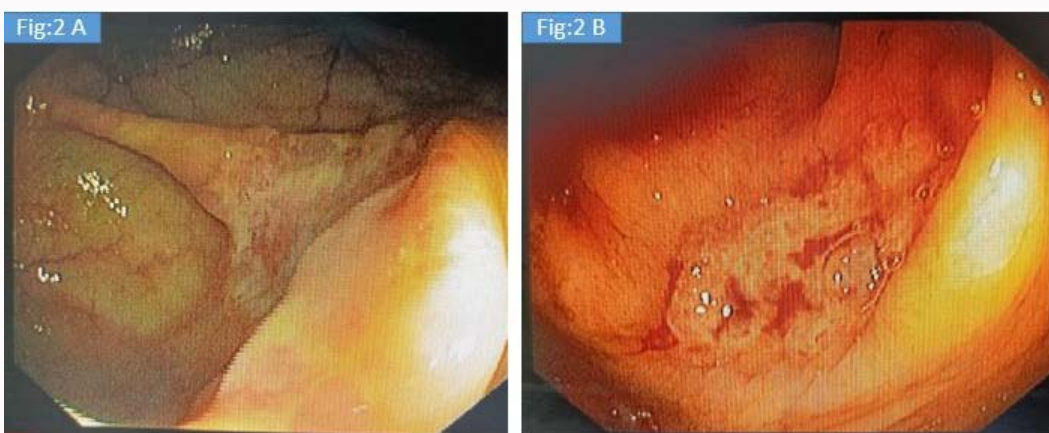

Figure 2: Colonoscopy Images of the cecum (Figure 2A) and ascending colon (Figure 2B) on flexible colonoscopy examination showing ulcerations.

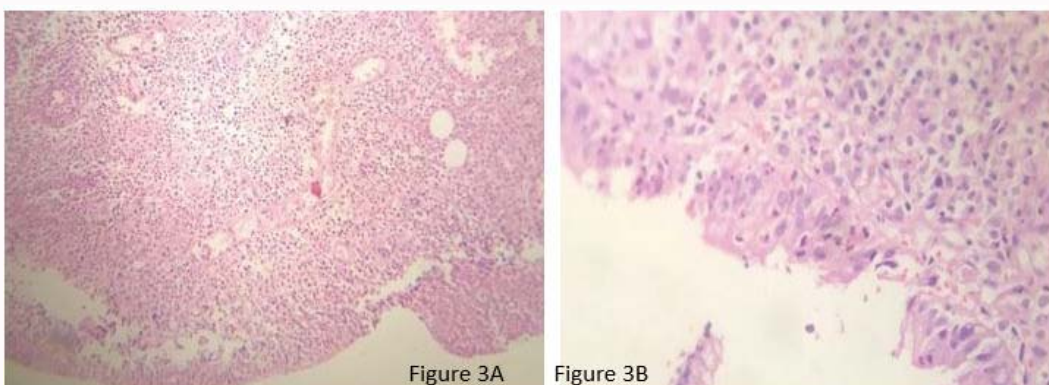


Figure 3: Colonic Biopsy images, H&E stain 10x (Figure 3A) and 40x (Figure 3 B): Biopsy of the colonic ulcer showing inflammatory exudate, ulceration, cryptitis, and congested vessels. No microscopic coagulopathy, crypt abscess, mucin depletion, hemosiderin deposits, parasite, vasculitis, malignancy, granuloma was seen.

Colonic biopsy (Figure 3A, 3B) showed inflammatory exudates, ulcerations, cryptitis, congested vessels, without microscopic coagulopathy necrosis, PAS stain was negative. Lamina propria showed edema, dense inflammatory infiltrates, no crypt abscess, no evidence of mucin depletion, hemosiderin deposits, no parasite, no vasculitis, no malignancy, no granuloma; biopsy was suggestive of Nonspecific active colitis with ulcerations likely related to post COVID-19 colonic ulcerations. She was referred to us as a possible case of disseminated malignancy with GI involvement, but biopsy

and review imaging were not suggestive of malignancy. She was treated conservatively and her symptoms resolved on follow up and stool occult blood test became negative.

Discussion

SARS-CoV-2 (COVID-19) infection has varied manifestations, ranging from most common respiratory symptoms to less common gastrointestinal manifestations. It may have completely asymptomatic course as well. Initial case series reported that 3% to

10% of patients have initial GI symptoms, who eventually develop pulmonary manifestations [1]. GI involvement in COVID also has varied manifestations which can range from anorexia, dyspepsia, nausea, vomiting, diarrhea illness, abdominal pain and necrotizing colitis. Gastrointestinal manifestations may be due to binding of the SARS-CoV-2 (COVID-19) virus to ACE 2 receptors (angiotensin converting enzyme-2 receptors) which are prevalent throughout the gut [2,3]. COVID-19 can result in GIT inflammation directly *via* infection of the GI cells or indirectly mediated by cytokines which can result in systemic symptoms and multiple organ involvement [4].

Studies of colonoscopy from Italy, done in the COVID-19 patients showed segmental colitis associated with diverticulosis in 25% cases followed by, ischemic colitis in 20% and ulcerative hemorrhagic colitis in 5% of cases [5]. The colonic ulcers as manifestation or sequel of COVID infection has not reported in literature so far, probably this is the first case report of colonic ulcers as a sequel to COVID infection. There are some case reports of bloody diarrhea as a clinical manifestation of COVID-19 with or without underlying inflammatory bowel disease [6,7]. There is also a case with colitis presenting as only presentation of COVID-19 infection [8]. Case reports of large bowel involvement in COVID-19 disease characterized by thickening of the ascending, transverse, left colon and case of colonic ileus with air fluid levels [9]. Due to the fear associated with the COVID-19 illness, and endoscopy being considered as a high risk procedure [10]. As endoscopy and colonoscopy are aerosols generating procedures it may endanger medical staff, and therefore not routinely performed in COVID-19 patients unless patients with life-threatening gastrointestinal bleeding or esophageal foreign-body obstruction [11]. So far no standardized methods established for stool COVID-19 analysis despite its prolonged shedding even after respiratory recovery. Coronavirus can be found in the stool even after other symptomatic recovery and nasal/pharyngeal swab become negative due to prolonged stool shedding [12]. Stool COVID-19 testing should be done in patients of gastrointestinal symptoms with negative nasopharyngeal swab test in a suspected COVID-19 disease [13], therefore methods should be sought for faecal isolation and stool testing for COVID-19.

In the present case, the patient was referred to us as a case of ileocecal mass with possible metastasis to liver, in view of radiological findings, but clinical history was not in favor. There are case reports in the form of case series, where colonic ulcers were found to be masquerading as malignancy, particularly tuberculosis in India. It is very difficult to differentiate tuberculosis on endoscopic and radiological features from malignancy or inflammatory bowel disease, therefore biopsy remains the key in such cases [14,15]. Also case of ischemic colitis mimicking as tumour are reported [16]. One has to be at utmost awareness to rule out or rule in possible malignancy due to varied presentation, in the current pandemic COVID-19 related GI manifestation must be kept in mind, either treatment related adverse effects or virus related injury.

Therefore patient was subjected to colonoscopy and biopsy with all standard precautions of COVID-19 protocols for the colonoscopy procedure to rule out the malignancy or other possible differential diagnosis. In present case we have considered multiple differential diagnoses for the cause of ulcerations which were masquerading as mass on radiological imaging. Firstly, NSAIDs related ulcerations, due to the proximal colonic nature, although history of NSAIDs or Over the Counter (OTC) drugs was not there. Secondly, tuberculosis

related colonic ulcerations was considered, which is more common entity particular in developing countries like India, and suspected involvement of ileum and cecum on imaging, although on colonoscopy, ileum was normal up to 10 cm from ileo-cecal valve. Thirdly, possibility of amoebic ulceration was kept, which usually presents as punched out ulcerations, and also common in India, but this was also ruled out in the biopsy analysis. All the other possible differential diagnosis were ruled out on biopsy evaluation of the lesions. Since such presentation is never reported in context to COVID-19 infection, it is worthwhile reporting this index case. Moreover, we have limitation of this case report is that the diagnoses is without any kinds of histologic confirmation of COVID-19, but we have ruled out all the alternative possible etiologies.

References

1. Wang D, Hu B, Hu C, Zhu F, Liu X, Zhang J, et al. Clinical characteristics of 138 hospitalized patients with 2019 novel coronavirus-infected pneumonia in Wuhan, China. *JAMA*. 2020;323(11):1061-9.
2. Barbosa da Luz B, de Oliveira NMT, França Dos Santos IW, Paza LZ, Braga LLVM, Platner FDS, et al. An overview of the gut side of the SARS-CoV-2 infection. *Intest Res*. 2020.
3. Guan GW, Gao L, Wang JW, Wen XJ, Mao TH, Peng SH, et al. Exploring the mechanism of liver enzyme abnormalities in patients with novel coronavirus-infected pneumonia. *Zhonghua Gan Zang Bing Zhi*. 2020;28(2):100-6.
4. Budden KF, Gellatly SL, Wood DL, Cooper MA, Morrison M, Hugenholtz P, et al. Emerging pathogenic links between micro biota and the gut-lung axis. *Nat Rev Microbiol*. 2017;15(1):55-63.
5. Massironi S, Viganò C, Dioscoridi L, Filippi E, Pagliarulo M, Manfredi G, et al. Endoscopic findings in patients infected with 2019 novel coronavirus in Lombardy, Italy. *Clin Gastroenterol Hepatol*. 2020;18(10):2375-9.
6. Mazza S, Sorce A, Peyvandi F, Vecchi M, Caprioli F. A fatal case of COVID-19 pneumonia occurring in a patient with severe acute ulcerative colitis. *Gut*. 2020;69(6):1148-9.
7. Carvalho A, Alqusairi R, Adams A, Paul M, Kothari N, Peters S, et al. SARS-CoV-2 gastrointestinal infection causing hemorrhagic colitis: Implications for detection and transmission of COVID-19 disease. *Am J Gastroenterol*. 2020;115:942-6.
8. Jaijakul S. Colitis as a sole presentation of SARS-CoV-2 infection: Case report. *SN Compr Clin Med*. 2020:1-3.
9. Sattar Y, Connerney M, Rauf H. Three cases of COVID-19 disease with colonic manifestations. *Am J Gastroenterol*. 2020;115(6):948-50.
10. Pribadi RR, Utari AP, Muzellina VN, Nursyirwan SA, Maulahela H, Renaldi K, et al. Clinical practice of gastrointestinal endoscopy in COVID-19 patients: An experience from Indonesia. *Clin Endosc*. 2021.
11. Tse F, Borgaonkar M, Leontiadis GI. COVID19: Advice from the Canadian association of gastroenterology for endoscopy facilities, as of march 16, 2020. *J Can Assoc Gastroenterol*. 2020; 3(3):147-9.
12. Green CA, Quraishi MN, Shabir S, Sharma N, Hansen R, Gaya DR, et al. Screening faecal microbiota transplant donors for SARS-CoV-2 by molecular testing of stool is the safest way forward. *Lancet Gastroenterol Hepatol*. 2020;5(6):531.
13. Han C, Duan C, Zhang S, Spiegel B, Shi H, Wang W, et al. Digestive symptoms in COVID-19 patients with mild disease severity: Clinical presentation, stool viral RNA testing, and outcomes. *Am J Gastroenterol*. 2020;115(6):916-23.
14. Kamlesh V, Vishwas DP, Prachi S, Bal M, Saklani AP. Isolated colorectal tuberculosis masquerading as malignancy: A case series. 2008 *Tropical Gastroenterology*. ISSN: Print-0250-636X.

15. Praharaj DL, Acharya A, Mohapatra V, Das S, Pradhan P, Mohapatra MK. Gastric tuberculosis masquerading as advanced malignancy in a young male. *Int J Mycobacteriol.* 2020;9(4):448-50.
16. Deepak P, Devi R. Ischemic colitis masquerading as colonic tumor: Case report with review of literature. *World J Gastroenterol.* 2011;17(48):5324-6.